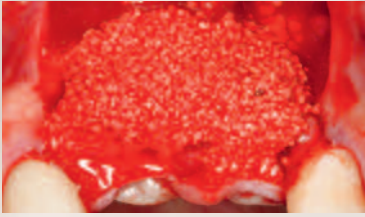


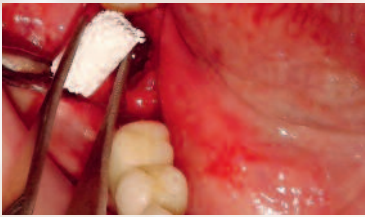Case Studies *Collection*

No. 12 - October 2015

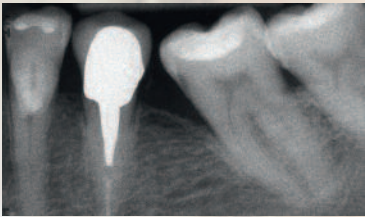
RTR
Horizontal bone
augmentation
Yi Man



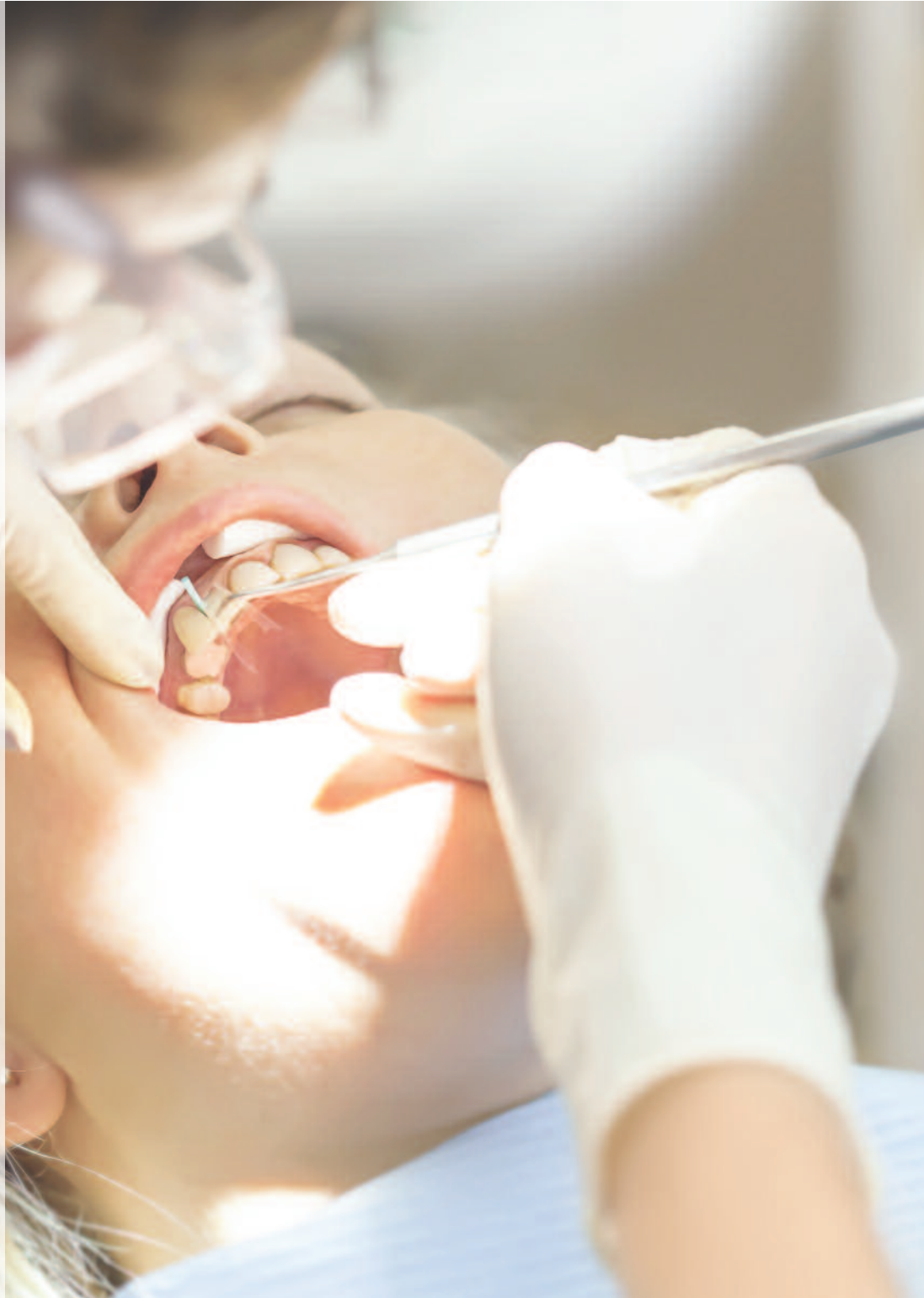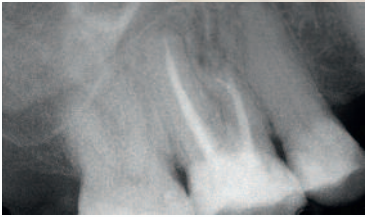
RTR
Alveolar ridge preservation
Ana I. Coello Gomez



BIODENTINE™
Iatrogenic perforation
treatment
H. Steffen

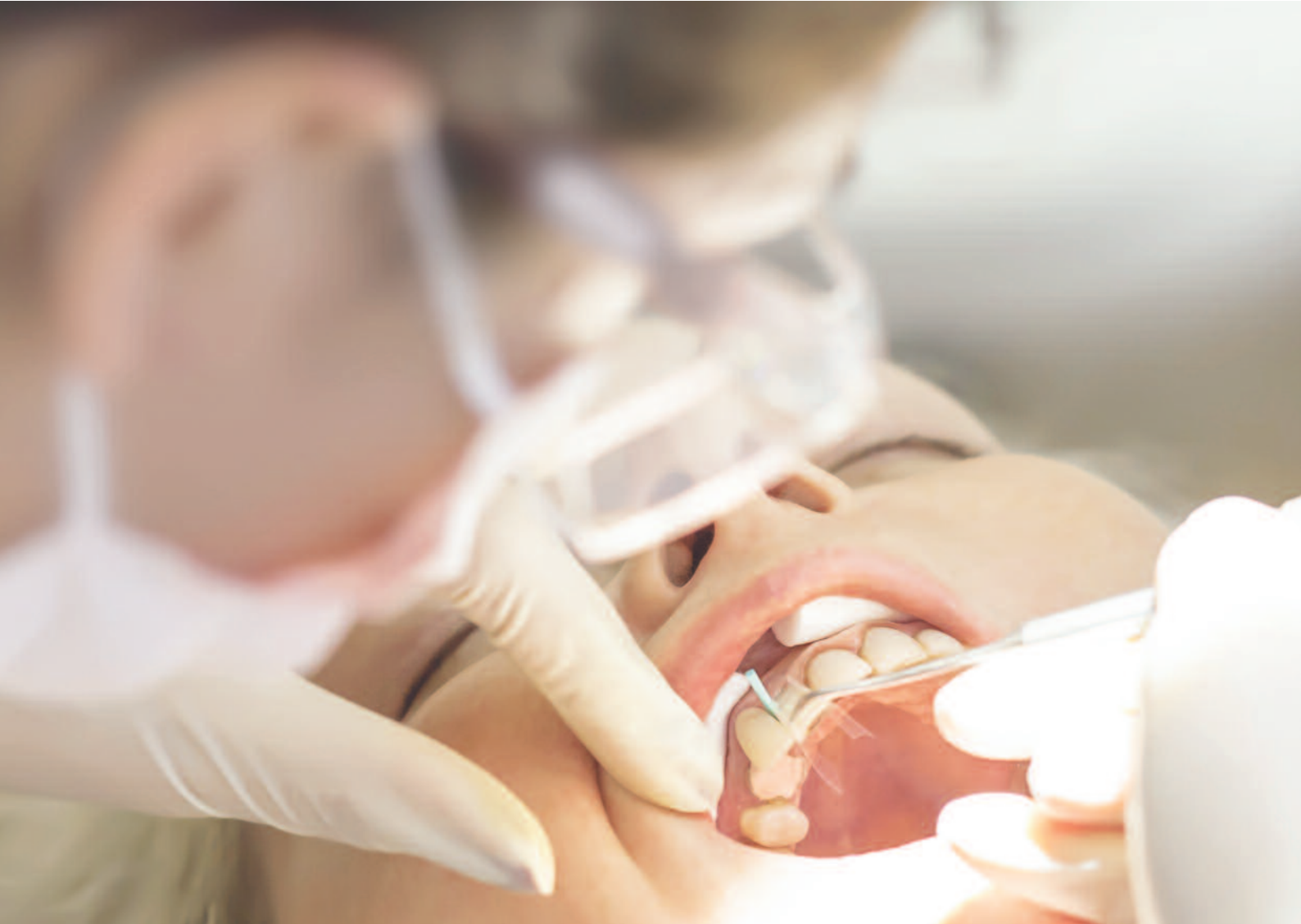

BIODENTINE™
Retrograde root canal filling
T. Dammaschke

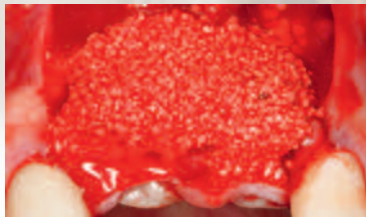


Septodont Case Studies Collection

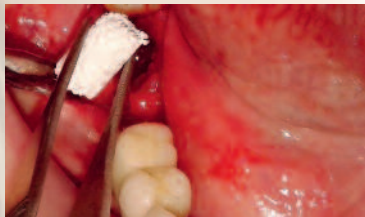No. 12 - October 2015



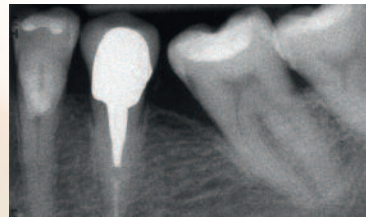
RTR
Horizontal bone
augmentation
Yi Man



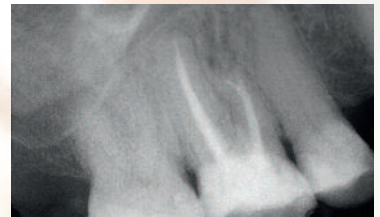
RTR
Alveolar ridge
preservation
Ana I. Coello Gomez



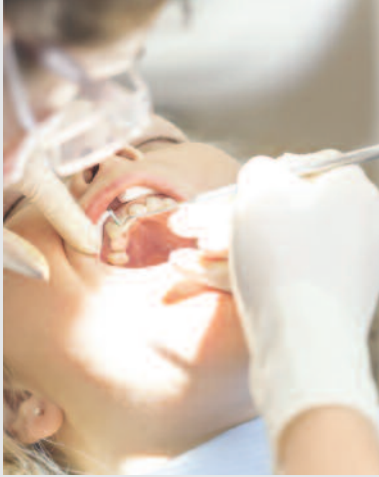BIODENTINE™
Iatrogenic perforation
treatment
H. Steffen



BIODENTINE™
Retrograde root canal
filling
T. Dammaschke



Editorial



© photo pixel / Fotolia

Since its foundation Septodont has developed, manufactured and distributed a wide range of high quality products for dental professionals.

Septodont recently innovated in the field of gingival preparation, composites and dentine care with the introduction of Racegel, the N'Durance® line and Biodentine™, which are appreciated by clinicians around the globe.

Septodont created the “*Septodont Case Studies Collection*” - a series of case reports - in 2012 to share with you their experience and the benefits of using these innovations in daily practice.

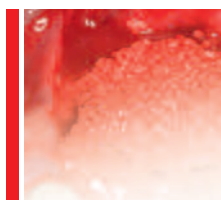
Over the past 3 years, authors from more than 15 countries have generously contributed to the success of our magazine that is now distributed on the 5 continents.

Each new issue of the Case Studies Collection is the opportunity to discover new clinical challenges and their treatment solutions.

This 12th issue is dedicated to two of Septodont's innovative products:

- R.T.R., an easy-to-use synthetic bone grafting material. In addition to its ability to provide an optimal osteoconductive environment to promote the growth of new dense bone, R.T.R. comes in 3 different presentations to suit all the clinical situations.
- Biodentine™, the first biocompatible and bioactive dentin replacement material. Biodentine™ uniqueness not only lies in its innovative bioactive and “pulp-protective” chemistry, but also in its universal application, both in the crown and in the root.

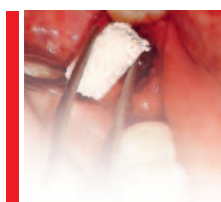
Content



β -tricalcium phosphate used with onlay graft for horizontal bone augmentation yielded preferable result: a case report

04

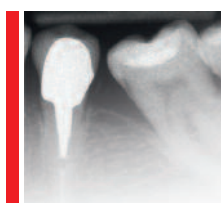
Yaqian Chen, Qingqing Wu, Yi Man



Alveolar Ridge Preservation With Alloplastic Material

09

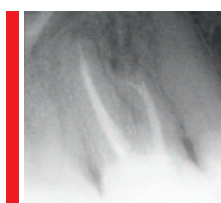
Ana I. Coello Gómez, Selene P. Navarro Suárez, Daniel Torres Lagares, Jose Luis Gutiérrez Perez



Treatment of Iatrogenic Lower Premolar Perforation with Biodentine™

16


Dr. Heike Steffen



Retrograde Root Canal Filling with Biodentine™

20

Dr. Till Dammaschke



β -tricalcium phosphate used with onlay graft for horizontal bone augmentation yielded preferable result: a case report

Yaqian Chen, Qingqing Wu, Yi Man
State Key Laboratory of Oral Diseases,
West China Hospital of Stomatology, Sichuan University, China

Introduction

Rehabilitation of teeth lost due to disease, trauma, surgery or congenital problems with implant-supported prosthesis has become a common practice worldwide. (1) However, various bone defects often exist in implant area. In some severe atrophic cases, alveolar bone must be restored before or in combination with implant placement. Bone augmentation using onlay bone grafts which are harvested from either intraoral or extraoral sites is currently one of the most reliable techniques with potential success rate. (2,3) However, the use of autografts only as onlay grafts has some drawbacks such as the high morbidity at the donor site, limited bone graft supply and the need for multiple surgical sites. (4,5) Therefore, synthetic bone graft materials have become a popular choice for bone augmentation during last decade and the application of different bone substitutes has

been described in different oral surgeries. (6.7.8.9) Recently, the synthetic bone graft based on β -tricalcium phosphate which can be completely absorbed in 6 to 9 months has been reported to be used in different oral surgeries such as alveolar preservation and periodontal defects with satisfactory clinical and histologic results. (10.11.12) Tricalcium phosphate grafts has structural characteristics which is similar to bone tissue, moreover, during reabsorption it can provide ion calcium and magnesium for surrounding tissue, thus creating a correct ionic environment, which could activate more alkaline phosphatase for further bone synthesis. (13) The purpose of this case report is to present clinical and radiographic results for a patient treated with β -TCP bone substitute with autogenous bone block harvested in situ as onlay grafts for horizontal bone augmentation.

Case Report

A 36 year-old healthy male with good oral hygiene required implant supported prosthesis for his two maxillary central incisors and right lateral incisor (tooth 11,12,21). (Fig1,2) Pre-surgery radiographic examination showed insufficient bone volume for placement of implants 3.3 mm in diameter. (Fig.3)

After administration of local anesthesia, crestal and vertical incisions were made to expose the labial surface of the absorbed alveolar ridge and two autogenous bone block was harvested apical to the recipient site from the basal base and β -TCP bone graft (RTR Syringe package, Septodont, France) was placed in the donor

site and dressed on the autogenous block. (Fig.4-9) Then the incision was closed after a titanium mesh and a barrier membrane was covered. (Fig.10) Routine anti-inflammatory therapy and prophylactic antibiotics were prescribed.

Six months later, a reentry surgery was performed. The bone graft material has been replaced by new formed bone which is an inspiring result as compared with six months ago. Two implants were inserted at tooth 12 and 21 with good primary stability. (Fig.11-13) CBCT examinations presented favorable outcome of the horizontal bone augmentation. (Fig.14-15)

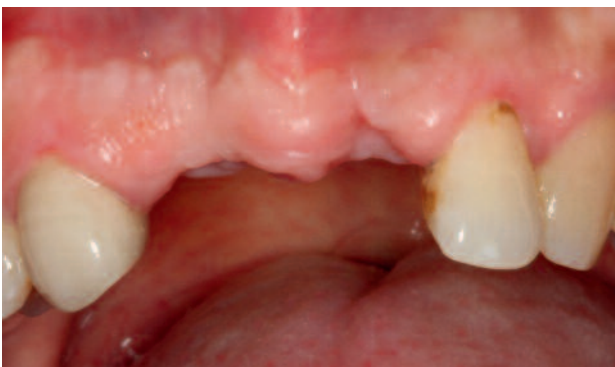

Fig. 1: Pre-surgery oral examination showed acceptable vertical height of the frontal bony shelf in anterior maxillary.

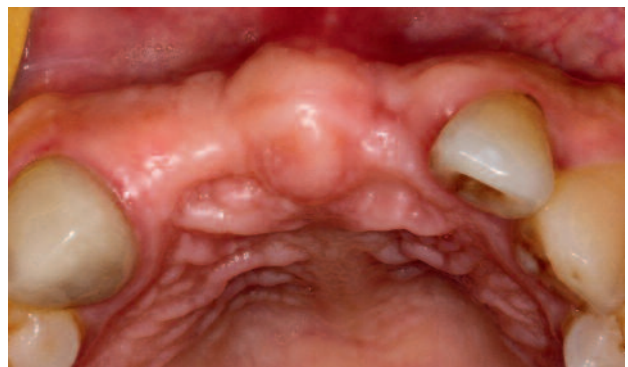

Fig. 2: Pre-surgery oral examination from occlusal view indicated horizontal bone defect.

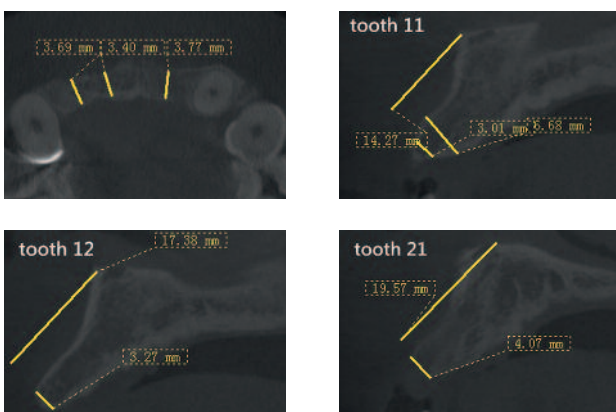


Fig. 3: Presurgery CBCT examination showed width and height of alveolar ridge before bone augmentation.

Fig. 4: Vertical and crestal incision was made to expose the labial surface of anterior alveolar bone.

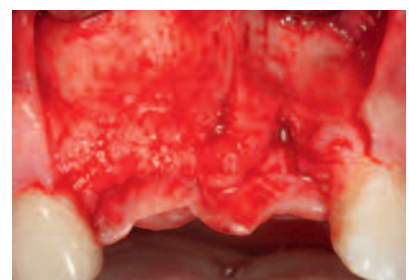
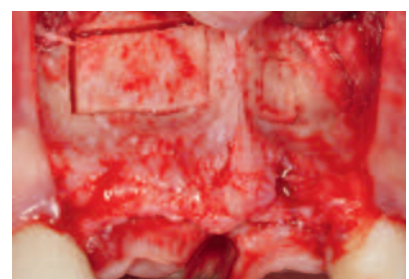
Fig. 5: Two bone blocks outlined by ultrasonic instruments from basal base apical to the recipient site.



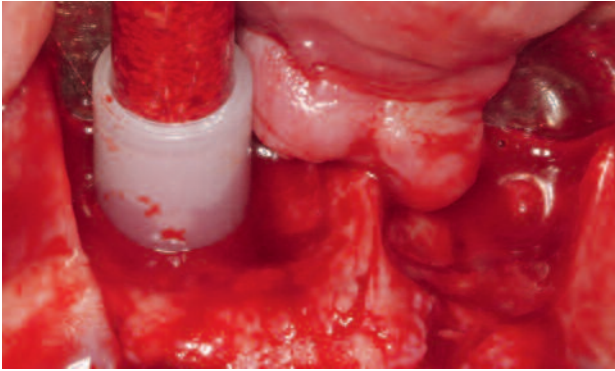


Fig. 6: Use the filter of the syringe package sucking blood in surgical area.

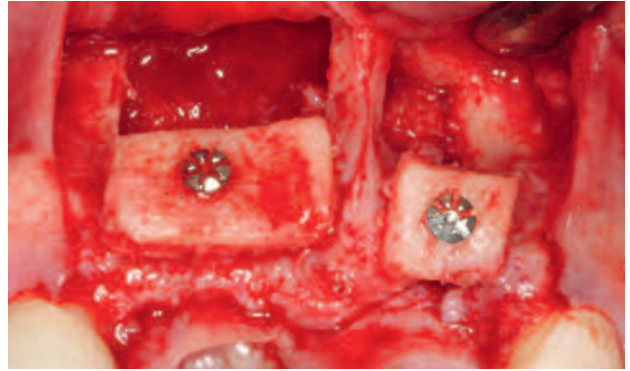


Fig. 7: Fix two blocks on the alveolar ridge with titanium screws.

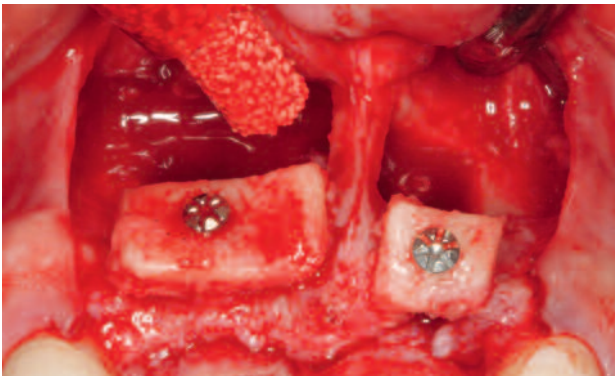


Fig. 8: Inject R.T.R. graft into the donor site.

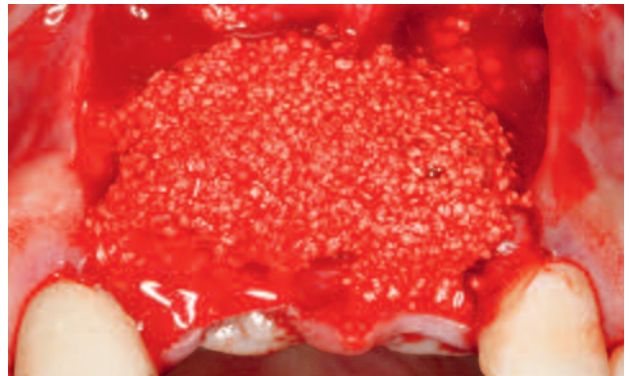


Fig. 9: Finish dressing R.T.R. graft on the blocks.

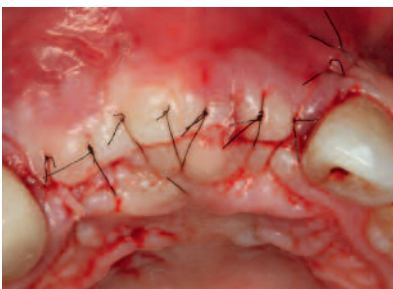


Fig. 10: Flap closed with a releasing incision.

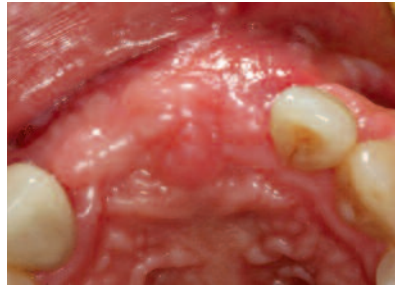

Fig. 11: Occlusal view six months later.

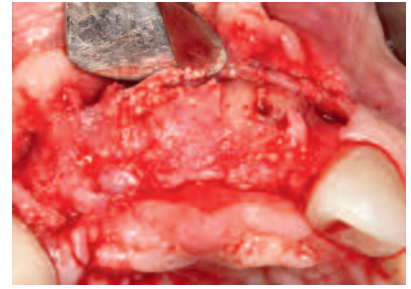


Fig. 12: Horizontal alveolar ridge was augmented by new formed bone.

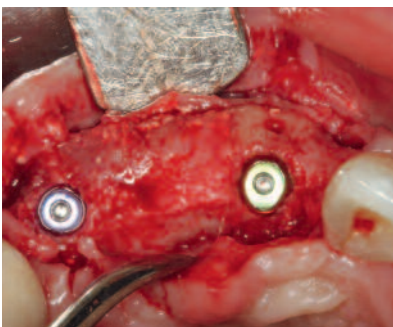


Fig. 13: Two implants were placed in the anterior maxillary.

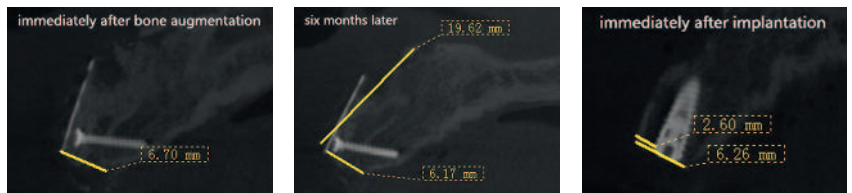

Fig. 14: CBCT of tooth 12 immediately after bone augmentation , six month later and immediately after implantation.

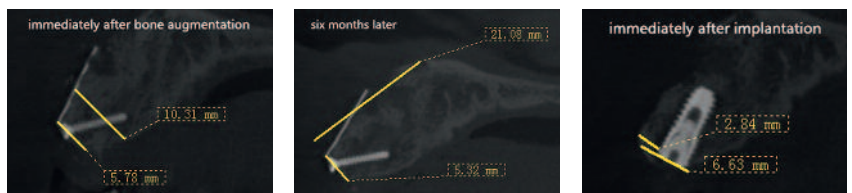


Fig. 15: CBCT of tooth 21 immediately after bone augmentation , six month later and immediately after implantation.

Discussion

This case report showed the potential advantage of β -tricalcium used with onlay graft for bone augmentation. The clinical and radiographic results show that this synthetic graft has been replaced by new formed bone six months later. Among all the graft materials, tricalcium phosphate is of special interest because it is a resorbable and osteoconductive biomaterial. (15) The in vivo osteoconductivity of synthetic bone graft is dependent on several properties including surface morphology, chemical composition and geometry at both the macro- and micro-scale. The pore size and interconnectivity of biomaterials can significantly influence the exchange of fluids through grafts and the delivery of ions, nutrients within and through the bone substitute. (16,17,18)

The bone graft used in this case consists of pure β -tricalcium with an appropriate macro- and micro-scale which turn to be good osteoconductivity and make this graft a potential scaffold for osteoblasts. Moreover, pure β -TCP can be totally absorbed in 6 months thus leaving no residuals in the implant area which may influence the remodeling of bone regeneration. (15)

β -TCP used with autogenous bone block as onlay graft for anterior bone augmentation in this case gained inspiring result which is a motivation for more oral surgeons to conduct similar cases. Despite the favorable result of the primary surgery, long term observation is still needed for a series of clinical cases.



Authors: Yi Man

From 2007 up to date: Clinical Lecturer of Implant Center, West China College of Stomatology, Sichuan University, China.

From 2010.09 – 2012.07: Clinical instructor, Clinical Lecturer of Tufts University School of Dental Medicine, Boston, USA.

From 2011.6-2012.7: Research Scholar of Massachusetts General Hospital of Harvard University, Massachusetts, USA.

From 2012.6 up to date: Standing Committee Member of Special Committee of Implant, Medical Society of Sichuan province, China.

From 2012.7 up to date: Associate professor of Oral Implantology Department, West China School of Stomatology, Sichuan University, China.

From 2012.9 up to date: Standing Committee Member of Committee of Implantology, Medical Society of China.

From 2013.2 up to date: Chair of Oral Implantology Department, Chair of Educational and research section of Oral Implantology, West China School of Stomatology, Sichuan University, China.

From 2014.11 up to date: International team for Implantology fellow.

Yaqian Chen

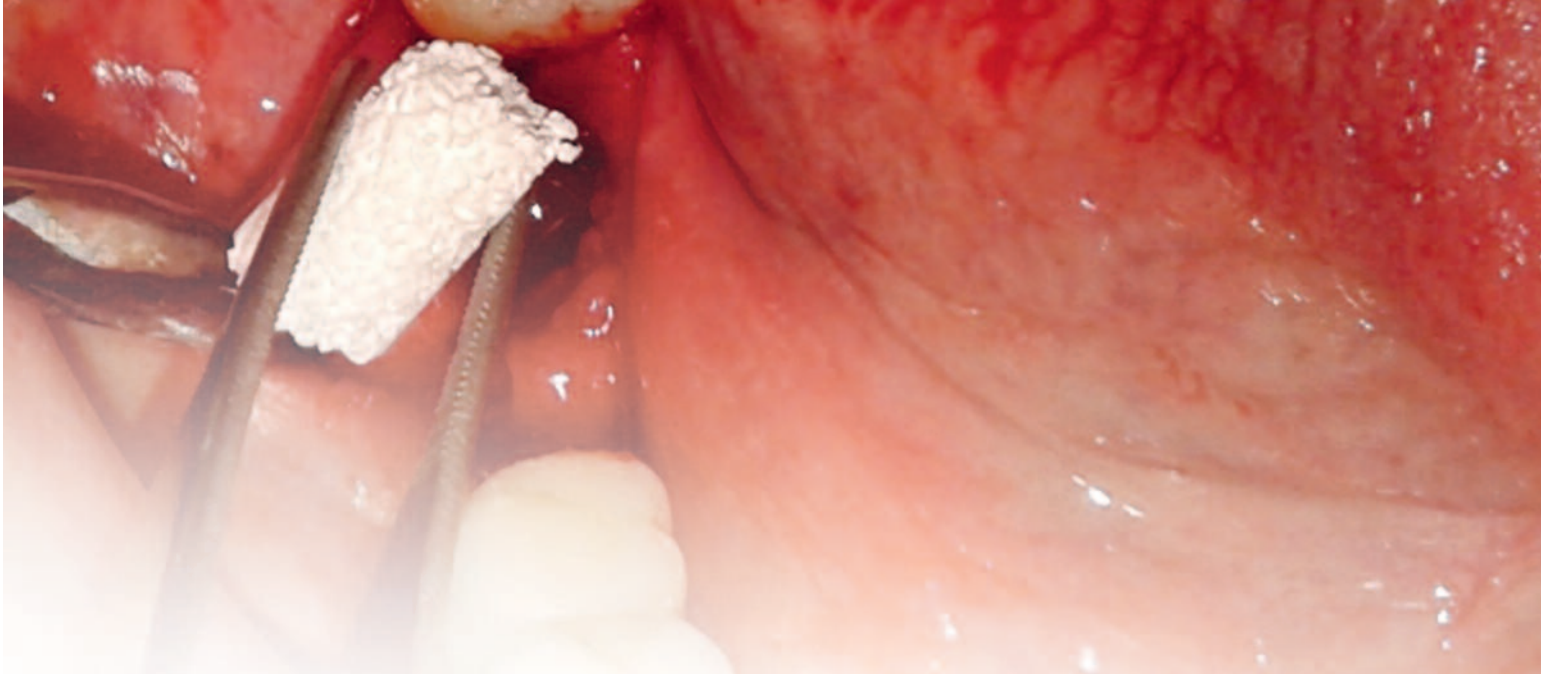
Resident of Department of Implantology, West China Hospital of Stomatology, Sichuan University, China.

Qingqing Wu

Resident of Department of Implantology, West China Hospital of Stomatology, Sichuan University, China.

References

- 01 Levin L. Dealing with dental implant failures. *J Appl Oral Sci* 2008;16:171-175.
- 02 Hill NM, Horne JG, Devane PA. Donor site morbidity in the iliac crest bone graft. *Aust N Z J Surg* 1999;69:726-728.
- 03 Isaksson S, Alberius P. Maxillary alveolar ridge augmentation with onlay bonegrafts and immediate endosseous implants. *J Cranio maxillofac Surg* 1992;20:2-7.
- 04 Chiapasco M, Zaniboni M, Rimondini L. Autogenous onlay bone grafts vs. alveolar distraction osteogenesis for the correction of vertically deficient edentulous ridges: a 2-4-year prospective study on humans. *Clin Oral Implants Res* 2007;18:432-440.
- 05 Felice P, Marchetti C, Iezzi G, Piattelli A, Worthington H, Pellegrino G, et al. Vertical ridge augmentation of the atrophic posterior mandible with interpositional bloc grafts: bone from the iliac crest vs. bovine an organic bone. Clinical and histological results up to one year after loading from a randomized-controlled clinical trial. *Clin Oral Implants Res* 2009;20: 1386-1393.
- 06 Wang M. Developing bioactive composite materials for tissue replacement. *Biomaterials* 2003; 24:2133-2151.
- 07 Schmitt CM, Doering H, Schmidt T, Lutz R, Neukam FW, Schlegel KA. Histological results after maxillary sinus augmentation with Straumann® BoneCeramic, Bio-Oss®, Puros®, and autologous bone. A randomized controlled clinical trial. *Clinical Oral Implants Research* 2013; 24:576-585.
- 08 Klijn, R.J., Meijer, G.J., Bronkhorst, E.M. & Jansen, J.A. A meta-analysis of histomorphometric results and graft healing time of various biomaterials compared to autologous bone used as sinus floor augmentation material in humans. *Tissue Engineering Part B: Reviews* 2010; 16: 493–507.
- 09 Tamimi F, Torres J, Al-Abedalla K, Lopez-Cabarcos E, Alkhraisat MH., Bassett DC., Gbureck U, Barralet JE.. Osseointegration of dental implants in 3D-printed synthetic onlay grafts customized according to bone metabolic activity in recipient site. *Biomaterials* 2014; 35:5436-5445.
- 11 Brkovic BM, Prasad HS, Rohrer MD, Konandreas G, Agrogiannis G, Antunovic D, Sándor GK. Beta-tricalcium phosphate/type I collagen cones with or without a barrier membrane in human extraction socket healing: clinical, histologic, histomorphometric and immunohistochemical evaluation. *Clin Oral Investig* 2012; 16: 581-590.
- 12 Stavropoulos A, Windisch P, Gera I, Capsius B, Sculean A, Wikesjö UM. A phase IIa randomized controlled clinical and histological pilot study evaluating rhGDF-5/ β -TCP for periodontal regeneration. *Journal of Clinical Periodontology*. 2011; 11:1044-1054.
- 13 Suba Z, Takács D, Matusovits D, Barabás J, Fazekas A, Szabó G. Maxillary sinus floor grafting with beta-tricalcium phosphate in humans: density and microarchitecture of the newly formed bone. *Clin Oral Implants Res*. 2006; 17:102-108.
- 14 Hirota M, Matsui Y, Mizuki N, Kishi T. Combination with allogenic bone reduces early absorption of beta-tricalcium phosphate (beta-TCP) and enhances the role as a bone regeneration scaffold. Experimental animal study in rat mandibular bone defects. *Dent. Mater. J.* 2009; 28: 153.
- 15 Rodella LF, Favero G, Labanca M. Biomaterials in Maxillofacial Surgery: Membranes and Grafts. *International journal of Biomedical science* 2011; 7: 81-88.
- 16 Gendler E. Perforated demineralized bone matrix: a new form of osteoinductive biomaterial. *J Biomed Mater Res* 1986;20:687-697.
- 17 Habibovic P, Yuan H, van der Valk CM, Meijer G, van Blitterswijk CA, de Groot K. 3D microenvironment as essential element for osteoinduction by biomaterials. *Biomaterials* 2005;26:3565-3575.
- 18 Walsh WR, Vizesi F, Michael D, Auld J, Langdown A, Oliver R, et al. β -TCP bone graft substitutes in a bilateral rabbit tibial defect model. *Biomaterials* 2008;29:266-271.



Alveolar Ridge Preservation With Alloplastic Material

Ana I. Coello Gómez

Dentist, Master Oral Surgery, University of Seville, Spain

Selene P. Navarro Suárez

Dentist, Master Oral Surgery, University of Seville, Spain

Daniel Torres Lagares

Co-director of the Master in Oral Surgery, University of Seville, Spain

Jose Luis Gutiérrez Perez

Co-director of the Master in Oral Surgery, University of Seville, Spain

Introduction and objective

Alveolar ridge preservation is done when it is expected that following a tooth extraction this part will be rehabilitated by an implant to minimize the bone resorption that occurs during the biological healing of the socket. Current studies allow us to expect that, with the alveolar ridge preservation technique, we will decrease the volume loss by around 1 mm in height and 3 mm in width.¹

Different techniques and materials have been used in recent years, all based on three biological mechanisms that promote alveolar healing: 2-4

- Osteogenesis: formation of new bone from viable and precursor osteoblasts, transplanted with graft material.
- Osteoinduction: formation of new bone by

differentiation of local connective tissue cells in bone-forming cells, under the influence of one or more inductors.

- Osteoconduction: formation of new bone by the network generated by a non-vital graft material, which allows the penetration of precursor osteoblasts present in the defect. The various types of grafts can be classified according to their origin in: autografts, allografts, xenografts, and alloplastic materials.
- Autografts: bone grafts that come from a donor area of the same individual. They are osteogenic, but have high resorption.
- Allografts: bone grafts from a member of the same species. They can be mineralized. In principle, they are associated with osteoinductive and osteoconductive properties.

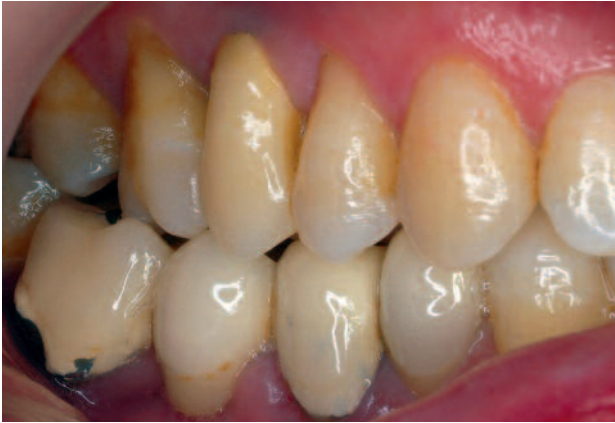

Fig. 1: Preoperative intraoral view of the 1st and 4th quadrants.

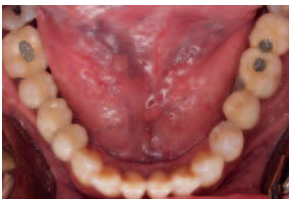

Fig. 2: Preoperative occlusal view of the lower arch.

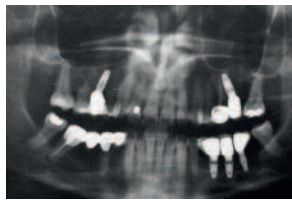

Fig. 3: Panoramic X-ray showing tooth 47, posterior three-unit porcelain-metal dental bridge, fractured, endodontically treated tooth, and apical radiolucent image.

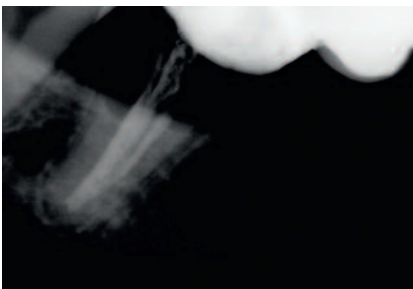


Fig. 4: Preoperative periapical X-ray.

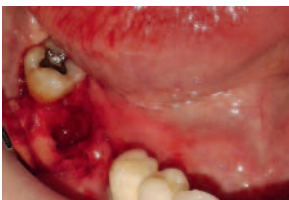

Fig. 5: Image of the socket after extraction, where we observe the integrity of its walls.

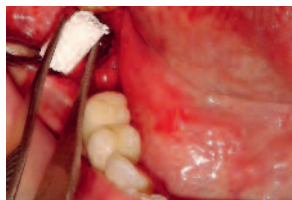

Fig. 6: Image of the placement of the selected biomaterial, easy handling using clamps.

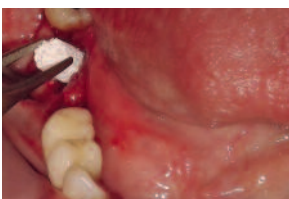

Fig. 7: Image that shows the filling of the socket with the biomaterial.

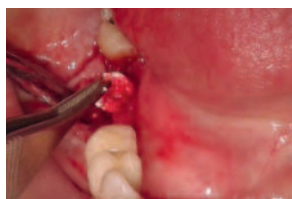

Fig. 8: Image where it is seen how the cone is impregnated with the blood from the socket.

- Xenografts: bone grafts from other species with osteoconductive properties.
- Alloplastic materials: bone grafts of synthetic origin (hydroxyapatite, bioactive glass, tricalcium phosphate, etc). They have osteoconductive properties.

Among the various available techniques described, the objective of this article is to present a case report of preservation with an alloplastic material without the need for membrane.

Case Report

A female patient, 53 years of age, with no special medical history, presented for alveolar ridge preservation of tooth 47 for subsequent rehabilitation with implant. The patient had an endodontically-treated, infected and fractured tooth (Fig. 1-3). The chosen treatment was its extraction and, given the risk of placing an implant in such conditions, we decided to postpone it, preserving the alveolar ridge.

After the careful extraction of the tooth and without raising a flap (Fig. 4), we proceeded to a thorough curettage, irrigating the socket using 0.2% chlorhexidine. Once the socket was disinfected, we checked that the walls were intact and proceeded to fill it with the selected biomaterial.

In this case, we used a sterile resorbable beta-tricalcium phosphate material from Septodont (R.T.R.), presented in the form of 0.3 cm³ cones, made of beta tricalcium phosphate granules coated with a matrix of highly purified collagen fibers of bovine origin which, in the case of cavities that cannot be closed, prevents the granules from leaking out.

The cone was placed in the socket using clamps (Fig. 5, 6), waiting for it to be carefully impregnated with the patient's own blood and compacting it (Fig. 7, 8). Finally, three crossed sutures were done on top, leaving the material slightly exposed

and checking the final status by X-ray (*Fig. 9, 10*). As post-op instructions, the patient was instructed to rinse with 0.2% chlorhexidine mouthwash, three times a day, from the second day, and as medical treatment, amoxicillin 1 g 1 tab/8hr/7days and ibuprofen 600 mg 1 tab/8 hr/7 days were prescribed.

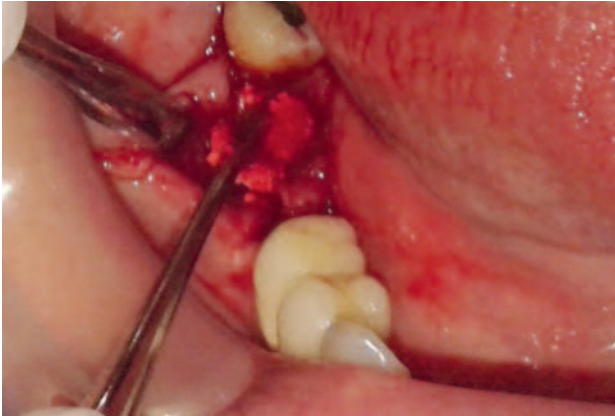


Fig. 9: Image finishing compacting the biomaterial.

After one week (*Fig. 11*), we removed the sutures and observed the start of healing of the soft tissues, also anticipating some maintenance of the alveolar ridge architecture, with less resorption than would occur spontaneously after simple removal of the molar.

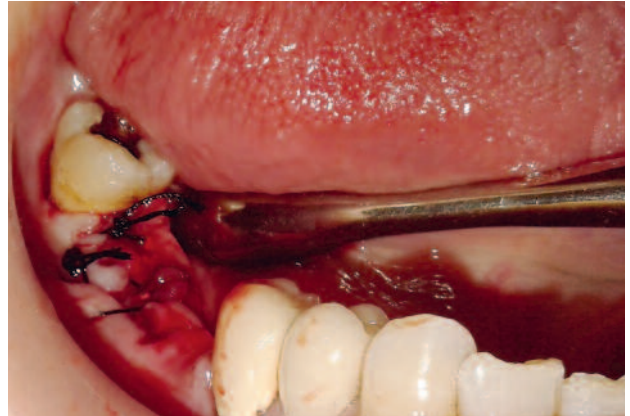


Fig. 10: Immediate postoperative image where the socket suturing is visible.

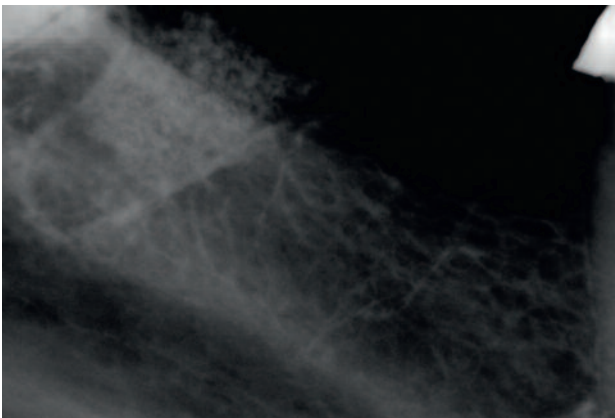


Fig. 11: Immediate postoperative periapical X-ray.

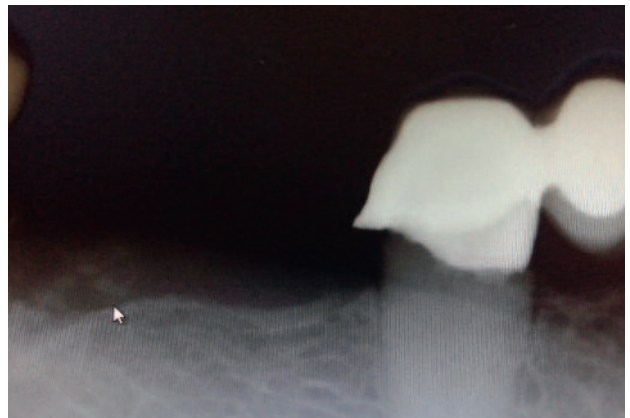


Fig. 12: One-week periapical X-ray.

Discussion

The case presented in this article correlates with previous studies in which, by using β -tricalcium phosphate and collagen bone grafts, it was possible to largely maintain the dimensions of the alveolar ridge.

In oral implantology, the goal of bone regeneration techniques is to increase or maintain bone volume for implant placement. Bone regeneration can be modified, by systemic factors, and also

by using biomaterials or bone substitutes. Traditionally, the ideal material, considered as "gold standard" for bone regeneration has been the autologous bone, taken from the patient. However, in recent decades, new human, animal or synthetic materials have been introduced, such as beta-tricalcium phosphate (R.T.R.), which has been very successful in implantological surgical techniques in experimental studies. 5-14 Cardaropoli et al.15 and other studies16-18

showed that sites where preservation had previously been done presented less resorption at six months compared with areas without preservation. However, even having performed an alveolar ridge preservation, the crestal resorption in width was 17% to 25%.

On the other hand, it has also been studied that there is a little loss of crest height and width after preservation¹⁹, but even so, Lasella et al.²⁰ concluded that the dimensions were improved, achieving conditions favorable for subsequent implant placement.

The alloplastic material used in this case is presented in the form of granules of beta tricalcium phosphate forming an osteoconductive micro- and macro-porous structure that encourages a dense growth of new bone.

The degree of bone regeneration from tricalcium phosphate varies depending on its formulation, porosity, and the size of the particles. The beta

phase is more recommended because it is less soluble than the alpha phase.

The dissolution rate of the material is related to its porosity, meaning that a greater porosity favors its resorption. In addition, the porosity is essential for perfusion, since the blood vessels and neoformed bone tissue need pores of at least 60 microns to grow. The size of the particles is also important since it has been shown that a smaller size causes less inflammatory reaction to a foreign body, which allows a stable mechanical interconnection and prevents phagocytic disintegration²¹.

From a clinical viewpoint, the various studies that use β -tricalcium phosphate in oral implantology show that about six months can be considered as a bone healing period.²²⁻³¹ The case reports in the literature show some successful results and provide clinical evidence to consider for future randomized and controlled clinical trials that more broadly study the benefits of this technique.


Conclusion

Alveolar ridge preservation is a technique that has shown to significantly reduce the bone resorption observed in the alveolar crest after tooth extraction, helping in the formation of hard tissue that is necessary for correct subsequent implant placement.

β -tricalcium phosphate (R.T.R.) has shown to be a good osteoconductive material for bone regeneration after filling a post-extraction socket,

maintaining an adequate alveolar ridge for subsequent placement of a dental implant.

When β -tricalcium phosphate is gradually resorbed, it is replaced by bone similar to the original bone, obtaining a regenerated vital bone tissue. The cone presentation, in addition to adapting to the shape of the socket, does not need to be covered with a membrane, thus facilitating its placement and handling.

**Authors:****Ana Coello Gómez (Main author)**

Dentist, University of Seville.

Master Oral Surgery, University of Seville.

Assistant Professor of the Master of Oral Surgery, University of Seville.

Member of the Spanish Society of Oral Surgery (SECIB)

Private practice limited to oral surgery.

Selene P. Navarro Suárez

Dentist, University of Seville.

Master Oral Surgery, University of Seville.

Assistant Professor of the Master of Oral Surgery, University of Seville.

Member of the Spanish Society of Oral Surgery (SECIB)

Private practice limited to oral surgery.

Daniel Torres Lagares

Dentist, University of Seville.

Master Oral Surgery, University of Seville.

Full Professor of the Master of Oral Surgery, University of Seville.

Member of the Spanish Society of Oral Surgery (SECIB).

José Luis Gutiérrez Pérez

Dentist and Oral and Maxillofacial Surgeon, University of Seville.

Master Oral Surgery, University of Seville.

Full Professor of the Master of Oral Surgery, University of Seville.

Member of the Spanish Society of Oral Surgery (SECIB).

References

- 01 Orgeas et al. Surgical Techniques for Alveolar Socket Preservation: A systematic Review. *Int. J. Oral Maxillofac. Implants.* 2013; 28: 1049-1061.
- 02 Barone A, Nicoli N, Fini M, Giardino R, Calvo JL, Covani U. Xenograft versus extraction alone for ridge preservation after tooth removal: a clinical and histomorphometric study. *J Periodontol* 2008; 79: 1370-1377.
- 03 Mardas N, Chadha V, Donos N. Alveolar ridge preservation with guided bone regeneration and a synthetic bone substitute or a bovine-derived xenograft: a randomized, controlled clinical trial. *Clin. Oral Impl. Res.* 21, 2010; 688-698.
- 04 Araujo M, Linder E, Wennström J, Lindhe J. The influence of Bio-Oss collagen on healing of an extraction socket: an experimental study in the dog. *Int J Periodontics Restorative Dent.* 2008; 28: 123-135.
- 05 Sixto García Ilnares, Óscar Hernán Arribaspiata Loconi. Caso clínico: Utilización del fosfato tricálcico beta (R.T.R) para relleno alveolar post-exodoncia, para la posterior colocación de un implante dental.
- 06 Barone A, Nicoli N, Fini M, Giardino R, Calvo JL, Covani U. "Xenograft versus extraction alone for ridge preservation after tooth removal: a clinical and histomorphometric study." *J Periodontol* 2008; 79: 1370-1377.
- 07 Jensen SS, Aaboe M, Pinholt EM, Hjorting-Hansen E, Melsen F, Ruyter IE. Tissue reaction and material characteristics of four bone substitutes. *Int J Oral Maxillofac Implants* 1996; 11: 55-66.
- 08 Norton MR, Wilson J. Dental implants placed in extraction sites implanted with bioactive glass: human histology and clinical outcome. *Int J Oral Maxillofac Implants* 2002; 17: 249-57.
- 09 Ormianer Z, Palti A, Shifman A. Survival of immediately loaded dental implants in deficient alveolar bone sites augmented with beta-tricalcium phosphate. *Implant Dent* 2006; 15: 395-403.

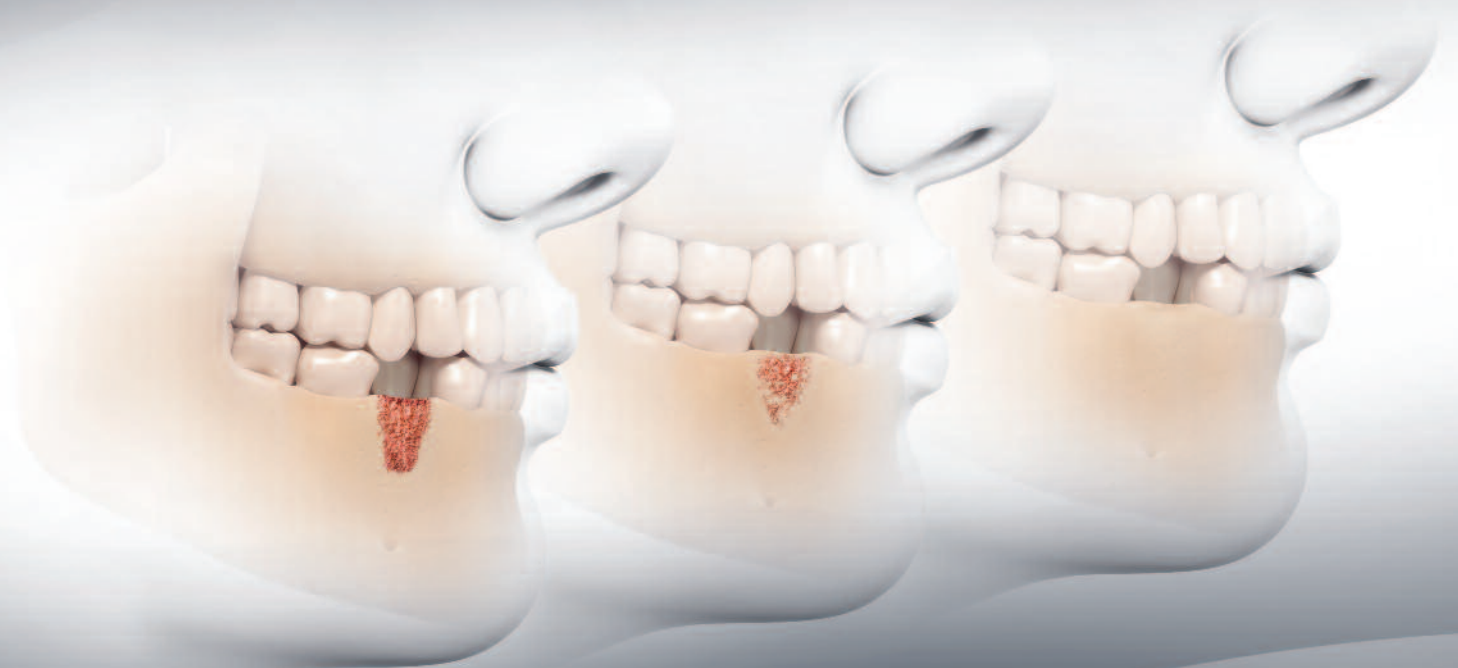References

- 10 Ogose A, Hotta T, Kawashima H, Kondo N, Gu W, Kamura T, Endo N. Comparison of hydroxyapatite and beta tricalcium phosphates as bone substitutes after excision of bone tumors. *J Biomed Mater Res* 2005; 72B: 94-101.
- 11 Linovitz RJ, Peppers TA. Use of an advanced formulation of beta-tricalcium phosphate as a bone extender in interbody lumbar fusion. *Orthopedics* 2002; 25 (suppl): 585-589.
- 12 Franch J, Diaz-Bertrana C, Lafuente P, Fontecha P, Durall I. Beta-tricalcium phosphate as a syntehtetic cancellous bone graft in veterinary orthopaedics. *Vet Comp Orthop Traumatol* 2006; 4: 1-9.
- 13 Jensen SS, Broggin N, Horting-hansen E, Schenk R, Buser D. Bone healing and graft resorption of autograft, anorganic bovine bone and beta-tricalcium phosphate. A histologic and histomorphometric study in the mandibles of minipigs. *Clin Oral Impl Res* 2006; 17: 237-43.
- 14 Suba Z, Takács D, Matusovits D, Barabás J, Fazekas A, Szabó G. Maxillary sinus floor grafting with betatricalcium phosphate in humans: desnity and microarchitecture of the newly formed bone. *Clin Oral Impl Res* 2006; 17: 102-108.
- 15 Cardaropoli D, Cardaropoli G. Preservation of the postextraction alveolar ridge: a clinical and histologic study. *Int J Periodontics Restestorative Dent* 2008; 28: 469-477.
- 16 Lekovic V, Kenney EB, Weinlaender M, et al. A bone regenerative approach to alveolar ridge maintenance following tooth extraction. Report of 10 cases. *J Periodontol* 1997; 68: 563-570.
- 17 Lekovic V, Camargo PM, Klokkevold PR, et al. Preservation of alveolar bone in extraction sockets using bioabsorbable membranes. *J Periodontol* 1998; 69: 1044-1049.
- 18 Ellingsen JE, Thomsen P, Lyngstadaas P. Advances in dental implant materials and tissue regeneration. *Periodontology* 2000 2006; 41: 136-56.
- 19 Vance G, Greenwell H, Miller R, Hill M, Johnston H, Scheetz J. Comparison of an allograft in an experimental putty carrier and a bovine-derived xenograft used in ridge preservation: a clinical and histologic study in humans. *Int J Oral Maxillofac Impl* 2004; 19: 491-497.
- 20 Isella JM, Greenwell H, Miller RL, Hill M, Drisko C, Bohra AA, Scheetz JP. Ridge preservation with freeze-dried bone allograft and a collagen membrane compared to extraction alone for implant site development: a clinical and histologic study in humans. *J Periodontol* 2003; 74: 990-999.
- 21 Jensen OT, Garlini G, Bilk D, Peters F. Use of alloplasts for sinus floor grafting. En: Jensen OT. *The sinus bone graft* (2^a ed). Quintessence: Chicago 2006. pag: 201-9.
- 22 Zijderveld SA, Zerbo IR, van der Bergh JPA, Schulten EAJM, ten Bruggenkate CM. Maxillary sinus floor augmentation using a beta-tricalcium phosphate (Cerasorb) alone compared to autogenous bone grafts. *Int J Oral Maxillofac Implants* 2005; 20: 432-40.
- 23 Mardas N, Chadha V, Donos N. Alveolar ridge preservation with guided bone regeneration and a synthetic bone substitute or a bovine-derived xenograft: a randomized, controlled clinical trial. *Clin. Oral Impl. Res.* 21, 2010; 688-698.
- 24 Ormianer Z, Palti A, Shifman A. Survival of immediately loaded dental implants in deficient alveolar bone sites augmented with beta-tricalcium phosphate. *Implant Dent* 2006; 15: 395-403.
- 25 Ogose A, Hotta T, Kawashima H, Kondo N, Gu W, Kamura T, Endo N. Comparison of hydroxyapatite and beta tricalcium phosphates as bone substitutes after excision of bone tumors. *J Biomed Mater Res* 2005; 72B: 94-101.
- 26 Linovitz RJ, Peppers TA. Use of an advanced formulation of beta-tricalcium phosphate as a bone extender in interbody lumbar fusion. *Orthopedics* 2002; 25 (suppl): 585-589.
- 27 Boix D, Weiss P, Gauthier O, Guicheux J, Bouler JM, Pilet P, Daculsi G, Grimandi G. Injectable bone substitute to preserve alveolar ridge resorption after tooth extraction: a study in dog. *J Mater Sci Mater Med* 2006; 17: 1145-52.
- 28 Sela MN, Steinberg D, Klinger A, Krausz AA, Kohavi D. Adherence of periodontopathic bacteria to bioabsorbable and non-absorbable barrier membranes in vitro. *Clin Oral Impl Res* 1999; 10: 445-52.
- 29 Szabo G, Huys L, Coulthard P, Maiorana C, Garagiola U, Barabas J, Néemth Z, et al. A prospective multicenter randomized clinical trial of autogenous bone versus beta-tricalcium phosphate graft alone for bilateral sinus elevation: histologic and histomorphometric evaluation. *Int J Oral Maxillofac Implants* 2005; 20: 371-81.
- 30 Suba Z, Takács D, Matusovits D, Barabás J, Fazekas A, Szabó G. Maxillary sinus floor grafting with betatricalcium phosphate in humans: desnity and microarchitecture of the newly formed bone. *Clin Oral Impl Res* 2006; 17: 102-108.
- 31 Trisi P, Rao W, Rebaudi A, Fiore P. Histologic effect of pure-phase beta-tricalcium phosphate on bone regeneration in human artificial jaw bone defects. *Int J Perio Rest Dent* 2003; 23: 69-77.

R.T.R.

Full resorption...


...Strong new bone formation



Cone



Syringe



Granules

R.T.R. (Resorbable Tissue Replacement) is a highly pure β -tricalcium phosphate bone grafting material that helps to safely create new bone formation following an extraction or any bone loss (intraony defect, sinus-lift...).

- **Resorbs progressively and fully:** R.T.R. releases calcium and phosphate ions helping to promote strong new bone formation.
- **Regenerates natural bone growth.** Osteoconductive micro and macroporous structures foster dense new bone growth.
- **Restores volume:** R.T.R. renews the bone integrity within 3-6 months.
- **Available in 3 presentations** (Cone, Syringe, Granules) to suit all clinical situations.

Improve your patients' extraction therapy and bone loss repair to promote future implant success with R.T.R.

R.T.R. Cone contains collagen from bovine origin



Treatment of Iatrogenic Lower Premolar Perforation with Biodentine™

OÄ [Senior Physician] Dr. Heike Steffen, Greifswald

Introduction

A 58-year-old patient with unremarkable general history underwent root canal treatment on tooth #35 in August 2010 due to complaints referable to the pulp. Thereafter, the tooth was asymptomatic, and was to be treated with post and core treatment and a crown due to the massive loss of crown substance. During pre-drilling for the planned post in September 2010, the primary reamer deviated from the original course of the root canal, perforating the root. The treating

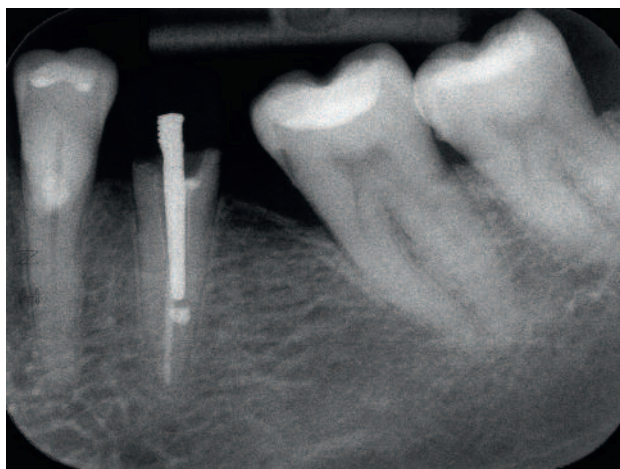


Fig. 1: Initial radiograph of 28.04.2011: The perforation has been provisionally treated with calcium hydroxide, and the tooth provided with a temporary post crown.

dentist suspected the perforation because the patient displayed pain during pre-drilling and bleeding out of the root canal, and immediately discontinued treatment, treating the perforation to the extent possible with a radiopaque calcium hydroxide preparation and the tooth with a temporary post crown. The patient was transferred to the Polyclinic for Restorative Dentistry, Periodontology, Endodontology and Preventive Dentistry of the Ernst-Moritz-Arndt University in Greifswald with a request to cover the perforation. The patient presented to our facility in April 2011. It was found that tooth #36 was missing, with gap closure due to the tilting of teeth #37 and #38.

On the initial radiograph, tooth #35 shows radiologically adequate root canal filling without apical lesions; in the middle third of the root, there was radiopaque material that was later found to be calcium hydroxide; a radiopaque metallic body was lying in the root canal that proved to be a temporary post crown (*fig. 1*). Clinically, the tooth was mildly sensitive to percussion; however, both close probing and palpation and tooth mobility were unremarkable.

In addition to detailed discussion of treatment with the patient, the patient was also informed of the limited prognosis of the tooth due to the previous complication. The patient nonetheless consented to the treatment. After anesthesia, application of a rubber dam, removal of the temporary post crown, and the application of a medicated insert, extensive perforation was confirmed by surgical microscope (ProErgo, Zeiss, Oberkochen, Germany). The position, size, and presence of granulation tissue in the perforation were determined using a plugger. The perforation was found to be lingual with a diameter of approx. 3-4 mm, and was already filled with granulation tissue (*Fig. 2*).

Local hemostasis was performed with hydrogen peroxide (3%), and extensive disinfection of the canal system was carried out using a NaOCl solution (3%) heated to approx. 37°C and chlorhexidine (2%). After hemostasis was obtained, a piece of resorbable collagen fleece (Parasorb, Resorba, Nuremberg, Germany) adjusted to the size of the perforation was placed beyond the perforation using a manual plugger that had previously been adapted to the length and diameter of the perforation (Handplugger by P. Machtou grey, Jadent, Aalen, Germany) (*fig. 3*). This served, on the one hand, to displace existing granulation tissue, and, on the other, as a barrier to avoid overstuffing of the Biodentine in the bone. The actual perforation was then treated with Biodentine, mixed according to the manufacturer's instructions. Additionally, a narrow, deep filling spatula specifically developed for perforation covering (John West Repair Instrument, Sybron Endo 974-0020/0021 Orange, CA, USA) was used (*fig. 4*).

For approx. 15 min, the initial curing of the Biodentine was awaited (*fig. 5*). An interim radiograph was obtained in order to verify the placement of the Biodentine (*fig. 6*). Lastly, the actual root canal was visualized and prepared appropriately in terms of length and diameter for the insertion of a pin using a red primary reamer (ER-System Gr. 2, Komet, Lemgo, Germany), and the length of the remaining root filling was radiographically verified (*fig. 7*). The tooth was provided with a new temporary post

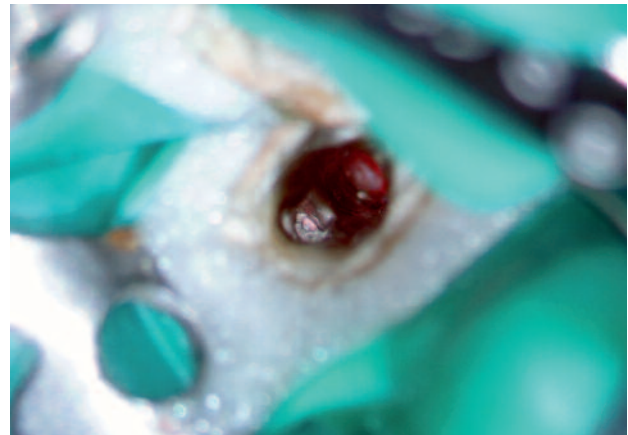


Fig. 2: Clinical photograph of the perforation.




Fig. 3: Plugger by P. Machtou for inserting the collagen fleece into the perforation.

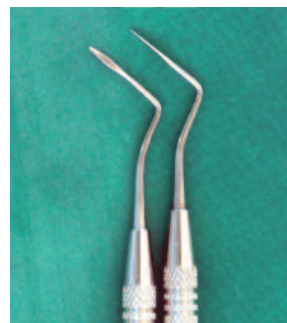

Fig. 4: John West Repair Instrument for applying Biodentine.

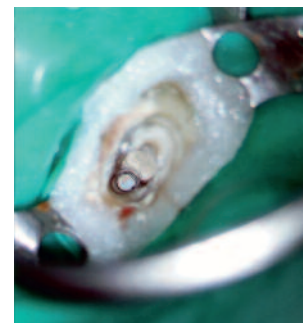

Fig. 5: Clinical image following application of Biodentine 28.04.2011.

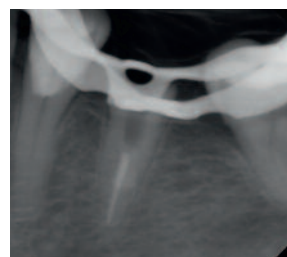


Fig. 6: Radiographic verification following placement of Biodentine 28.04.2011.

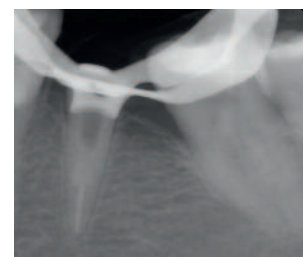


Fig. 7: Radiographic verification after preparation for the post, 28.04.2011.

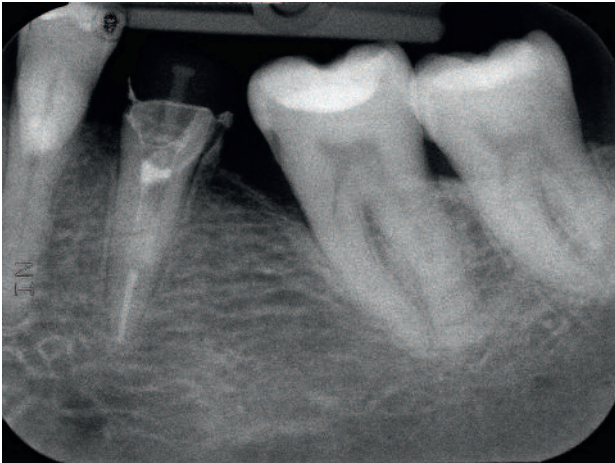


Fig. 8: Verification image before prosthetic treatment 26.05.2011.

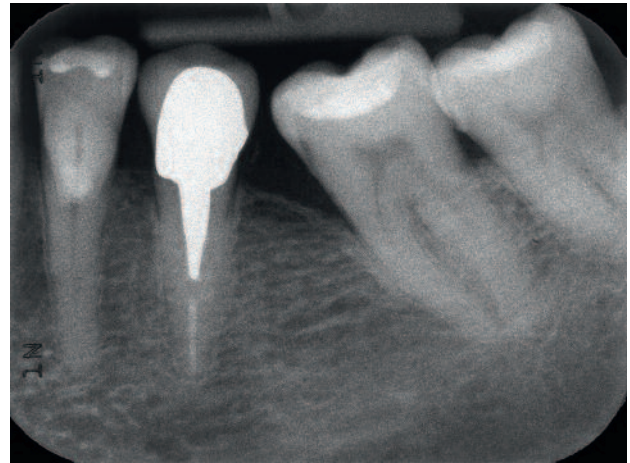


Fig. 9: Recall 28.01.2014.

crown. All treatment was carried out under dental microscope. The patient had no post-operative complaints. Then, the patient's primary dentist immediately treated the tooth with an individually molded NEM post and core structure and a veneer

crown. A radiograph obtained before the prosthetic treatment was unremarkable (Fig. 8). Follow-up in January 2014 showed a clinically and radiologically asymptomatic, fully functional tooth #35 with an adequate crown (Fig. 9).

Discussion

Perforations in the middle and apical third of the root have a significantly better prognosis than in the coronal third or the bottom of the pulp chamber because of the greater risk of microbial contamination in these cases (Fuss & Trope 1996). Additionally, the outcome depends on the time of treatment and the presence or absence of previous contamination. After a perforation has been found, treatment should be initiated immediately. Any delay may increase the risk of infection, thus worsening the prognosis of the tooth. This was unfortunately not the case here because the perforation was only adequately treated 8 months later at our facility. The calcium hydroxide and relatively tight temporary crown of the previous treating dentist surely helped to prevent an infection. Granulation tissue, which was displaced to the outside of the tooth by means of the collagen fleece, was already present at the perforation site itself. This barrier also prevented overstuffing of the Biodentine in this case, thus allowing for an

optimal seal of the root to the periodontal space. According to the literature, the placement of a barrier, e.g., with collagen fleece or calcium sulfate, has no significant effect on prognosis, but does prevent overstuffing with filling material (Rafter et al. 2002).

The influence of the size of the perforation on the prognosis of the tooth is controversial in the literature. Thus, Fuss & Trope (1996) found that the size of the perforation results in a worsening of the prognosis of the tooth. However, Mente et al. (2010) and Pontius et al. (2013) found no relationship in their studies. Holland et al. (2001) found reformation of cement in canine teeth subjected to iatrogenic lateral perforation and then treated with MTA after 180 days in most cases. In another study on canine teeth in 2007, they showed that immediate treatment with MTA resulted in significantly better histological findings after 90 days than when the treatment of the perforation wound was delayed by 7 days, even if it had been disinfected with chlorhexidine.

The quality of the coronal treatment is also a decisive factor for the prognosis of the tooth (Balto 2011). The dentist immediately treated tooth #35 with a post and core structure and a crown after covering the perforation, which is a

major factor in the outcome.

The advantage of Biodentine is the relatively short curing time, allowing for procedures of this type to be carried out in a single session. The reduced radiopacity is a disadvantage.

Summary

Biodentine's biocompatible properties made it an optimal material for covering the iatrogenic lateral root perforation in this case. Before the insertion of materials such as Mineral Trioxide Aggregate (MTA) or Biodentine, teeth compro-

mised in this way must be extracted. The low radiopacity of Biodentine is disadvantageous when verifying whether the defect has been sufficiently treated.



Author:

Dr. Heike Steffen

Senior Physician (Oberärztin), Center for Dentistry, Oral and Orthodontic Medicine, Polyclinic for Restorative Dentistry, Periodontology and Endodontology

Studied dentistry in Greifswald 1986–1991, doctorate in 1995, Senior Physician at the Clinic for Dentistry, Periodontology, Endodontology and Preventive Dentistry of the Ernst-Moritz-Arndt University in Greifswald since 2000;

specialist for endodontology at DGZ since 2005, 2004–2006 International Program at the Endodontic Department at the University of Philadelphia, PA, USA; since 2005, referrer practice for endodontics in Karlsburg 2 days/week and employee of that department for 3 days/week.

Principal fields: Endodontology and endodontic microsurgery, gold foil fillings

Member, AAE, DGET, ESE, AAGFO.

Address for correspondence:

Universitätsmedizin Greifswald

Zentrum für Zahn-, Mund- und Kieferheilkunde

Poliklinik für Zahnerhaltung, Parodontologie und Endodontologie

OÄ Dr. Heike Steffen

Rotgerberstrasse 8

17475 Greifswald

Tel. 0 38 34/8 61 96 14

Email hsteffen@uni-greifswald.de

Retrograde Root Canal Filling with Biodentine™

Prof. Dr. Till Dammaschke, Münster

Case Report

A 61-year-old patient presented to the Polyclinic for Restorative Dentistry of the University Hospital Münster with pain and swelling (diameter approx. 1 cm) in the turn-up of the right maxilla in the region of tooth #16. Tooth #16 was negative on sensitivity tests with dry ice and positive on percussion testing. The patient reported that

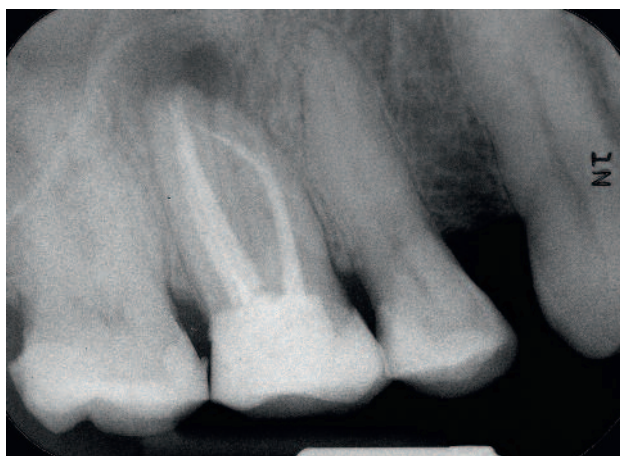

Fig. 1: 61-year-old patient presented with pain and swelling in the region of #16. The radiograph obtained showed apical brightening and a fractured root canal instrument at tooth #16 protruding over the apex of the mesiobuccal root canal.

this tooth had undergone root canal treatment elsewhere approximately one year before. The radiograph obtained (*Fig. 1*) showed apical brightening and a fractured root canal instrument that likely protruded over the apex of the mesiobuccal root canal. The filling of all four root canals appeared radiopaque, laterally well adapted, and free of signs of porosity of air pockets. After extensive consultation and discussion with the patient on the course of treatment, terminal infiltration anesthesia (Septanest, Septodont) was carried out on tooth #16. For acute treatment of the existing pain, the area was incised in order to ensure pus drainage. The wound was rinsed, and an iodoform strip was inserted.

One and four days after initial treatment, the patient re-presented for wound cleaning and changing of the iodoform strip. On both days, the patient reported no complaints. No more pus could be seen exiting the wound. Another three days later - after extensive consultation

and discussion with the patient - an apicoectomy was planned. After terminal anesthesia, a trapezoid mucogingival lobe was prepared in the area of #16. In order to expose the mesiobuccal root, the overlying bone was appropriately removed (Fig. 2), and an apicoectomy of the mesiobuccal root of tooth #16 was performed. The granulation tissue was completely removed and sent for histopathological investigation.

An ultrasound-driven angled instrument with a diamond coating was used for the retrograde preparation of both root canals of the mesiobuccal root (Fig. 3). The fractured instrument could thus be visualized (Fig. 4) and removed. Both mesiobuccal root canals were retrogradely prepared and cleaned with an ultrasound probe at a depth of approx. 3 mm. Biodentine™ (Septodont, St Maur des Fossés, France) was selected for retrograde filling of the root canal, mixed according to the manufacturer's instructions, and applied in the retrograde direction (Fig. 5). The mucogingival lobe was adapted and sutured. The postoperative radiograph showed complete removal of the fractured instruments, as well as an osseous defect about the mesiobuccal root tip (Fig. 6).

One week after the procedure, the sutures were removed. The wound healed without complication, and the patient was free of complaints. The histopathological investigation confirmed the diagnosis of an apical granuloma with accumulation of granulocytes and foam cells. No cyst-forming epithelium or malignant cells were detected. Three, seven, 16, and 39 months post apicoectomy, the patient was called in for follow-up. At all examinations, the patient was free of complaints, and tooth #16 was negative both to sensitivity and percussion testing. The radiographs obtained indicated the beginnings of osseous regeneration in the area of the mesiobuccal root tip already after three months (Fig. 7) and complete healing seven months after retrograde sealing with Biodentine™ (Fig. 8). The radiograph obtained 3 years and 3 months post apicoectomy showed apical stability (Fig. 9).

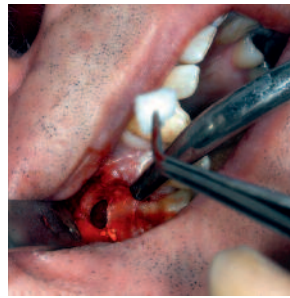

Fig. 2: Apicoectomy was performed in order to remove granulation tissue and the fractured instrument.

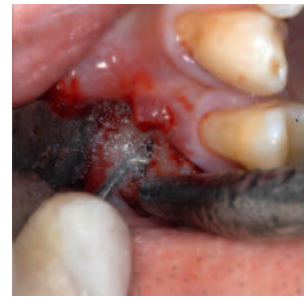

Fig. 3: Both mesiobuccal root canals were retrogradely prepared and cleaned with an angled, diamond-coated ultrasound probe.

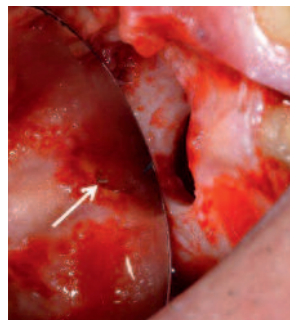


Fig. 4: The arrow indicates the exposed fractured root canal instrument at the mesiobuccal root.

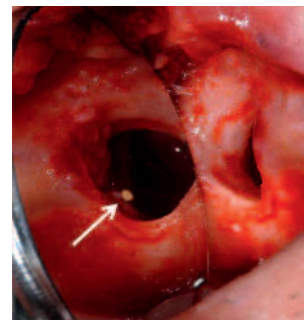


Fig. 5: Apicoectomy was performed in order to remove granulation tissue and the fractured instrument.

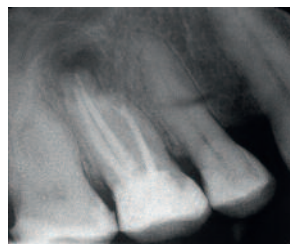

Fig. 6: The radiograph obtained immediately postoperatively shows an osseous defect about the mesiobuccal root tip. The fractured root canal instrument was completely removed. Due to the suboptimal radiopacity of Biodentine, the cement can barely be seen on radiography.

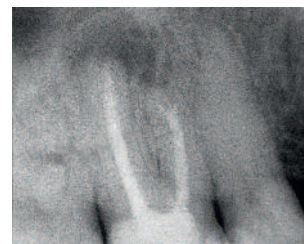


Fig. 7: Already 3 months post apicoectomy, the beginnings of osseous regeneration could be observed in the region of the procedure.

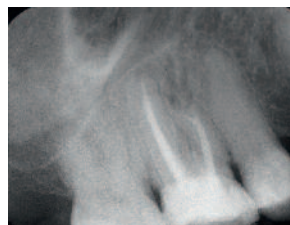


Fig. 8: The dental radiograph, obtained seven months post apicoectomy and retrograde sealing with Biodentine, shows complete osseous regeneration in the area of the mesiobuccal root. Pathological changes could not be seen apically on tooth #16.

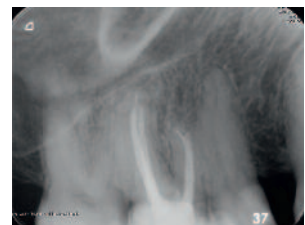


Fig. 9: Even 3 1/4 years after the procedure, apical stability was found.

Summary

For successful apicoectomy, retrograde sealing of resected root canals is indispensable, because gutta-percha alone is known not to be capable of inducing osseous regeneration at the root tip due to its material properties and surface composition.³ Additionally, the objective of retrograde sealing is to provide a bacteria-proof seal on the root canals and to avoid microleakage. In the past, various dental materials such as amalgam, reinforced zinc oxide-eugenol cement (IRM, Super-EBA), glass ionomer cement, and composite were used for this purpose.^{1,2,6} However, Mineral Trioxide Aggregate (MTA) is also increasingly recommended because this cement shows better clinical results. MTA is capable of providing a bacteria-proof seal on the root canal, and is both biocompatible and bioactive, i.e., osseous cell growth can be induced by this cement.^{1,5} However, MTA also has drawbacks: It is not always easy to handle; the setting time is relatively long. Pressure resistance, flexural strength, and Vickers hardness

are lower than that of dentin, and it is also relatively expensive. On the other hand, Biodentine™ appears to have advantages: Biodentine™ is also bioactive and biocompatible; the setting time is shorter, and pressure resistance, flexural strength, and Vickers hardness are on the order of dentin. As can be seen in this case, after the application of Biodentine™, complete osseous regeneration of the resection zone occurred already approx. 6 months after treatment. The positive effect on osseous cells, and thus the bioactivity of Biodentine™, was clearly demonstrated in vitro.⁴

The initial approx. 15 min setting time of Biodentine™ did not elapse in this case before the wound was closed because Biodentine™ - like other calcium silicate cements - also sets in moist environments. However, this likely does not result in optimal material properties, e.g., final hardness, which was observed clinically but is of secondary importance because the retrograde seal is not directly subject to chewing forces.



Author:
Prof. Dr. Till Dammaschke

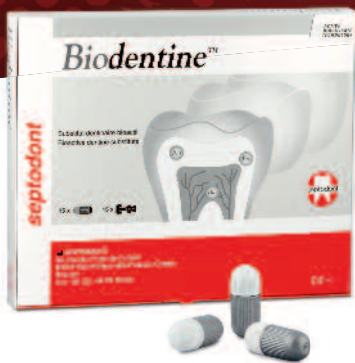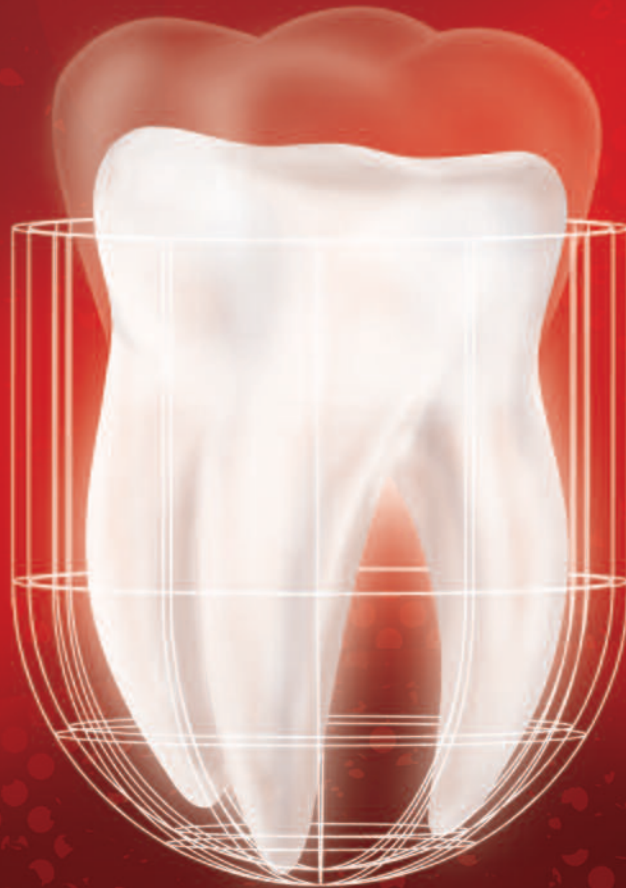Studied sociology, political science, and history in 1986 at Georg-August University Göttingen, 1987–1993; studied dentistry at Georg-August University Göttingen, research associate since 1994 for Prof. Dr. med. dent. K. Ott at the Polyclinic for Restorative Dentistry of the Westphalian Wilhelms-University Münster, doctorate in 1996 at Georg-August University Göttingen, Senior Physician (Oberarzt) since 1998 at Polyclinic for Restorative Dentistry of the Westphalian Wilhelms-University Münster; DGZ Prize 2000, prize in the category of endodontics in 2000, and second place in 2010, best-of-year prize for scientists of the DGZMK 2004, DGZ prize in 2004, since November 2002 on the board of the journal "Endodontie"; 2005–2011 head of "AGET Studiengruppe" Münster, made Assistant Professor [Akademischer Rat] in 2007, teaching qualification [Habilitation] 2008, made Senior Assistant Professor [Akademischer Oberrat] in 2009, made supernumerary Professor [außerplanmäßiger Professor] in 2012.

Address for correspondence:

Universitätsklinikum Münster
Zentrum für Zahn-, Mund- und Kieferheilkunde
Poliklinik für Zahnerhaltung
Prof. Dr. Till Dammaschke
Albert-Schweitzer-Campus 1, Gebäude W 30
Waldeyerstrasse 30 - 48149 Münster
Tel. 02 51/83-4 70 35 - Email tillda@uni-muenster.de

Biodentine™

The first and only dentin in a capsule



ACTIVE
BIOSILICATE
TECHNOLOGY

As the **first all-in-one** biocompatible and bioactive **dentin substitute**, Biodentine™ fully replaces dentin wherever it's damaged.

Biodentine™ helps the remineralization of dentin, preserves the pulp vitality and promotes pulp healing. It replaces dentin with similar biological and mechanical properties.

Improving on **Biodentine™** clinical implementation, you can now bond the composite onto Biodentine™ in the same visit and perform the **full restoration in a single session**.

To enjoy the clinical benefits of the first and only dentin in a capsule, ask your dental distributor for Biodentine™.



Learn more with
the Biodentine™ brochure





The Dental Pharmaceutical Company

INNOVATIVE, SAFE AND EFFECTIVE SOLUTIONS FOR DENTISTRY WORLDWIDE