

Septodont Case Studies Collection

No. 10 - March 2015

R.T.R.

USE OF R.T.R. AND PRF AS FILLING MATERIAL IN POST EXTRACTION SOCKETS

PATRICIO GONZÁLEZ, OMAR GONZÁLEZ,
CLAUDIA ZENTENO, JOAQUÍN URRIZOLA

BIODENTINE™

IN CORRECTIVE SURGERY:

A SOLUTION TO THE ROOT PERFORATIONS

ALICIA CARO MOLINA

BIODENTINE™

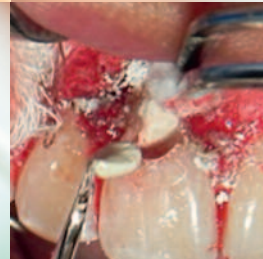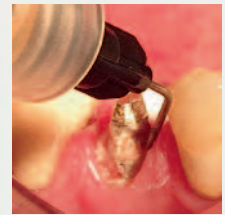
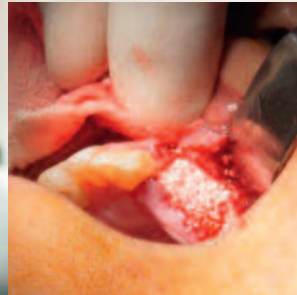
APEXIFICATION AS TREATMENT IN IMMATURE APEX USING BIODENTINE™

MERCADO VELÁZQUEZ CYNTHIA

RACEGEL

GINGIVAL PREPARATION WITH RACEGEL

LUIS FABIÁN BROTONS DUHART



Editorial

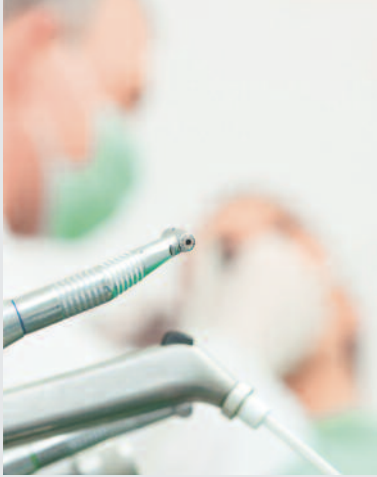

Photo © Arnie8001

Since its foundation Septodont has developed, manufactured and distributed a wide range of high quality products for dental professionals.

Septodont recently innovated in the field of gingival preparation, composites and dentine care with the introduction of Racegel, the N'Durance® line and Biodentine™, which are appreciated by clinicians around the globe.

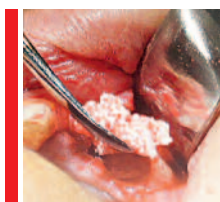Septodont created the “Septodont Case Studies Collection” to share their experience and the benefits of using these innovations in your daily practice.

This Collection consists in a series of case reports and is published on a regular basis.

This 10th issue is dedicated to three of Septodont’s innovative products:

- R.T.R., an easy-to-use synthetic bone grafting material. In addition to its ability to provide an optimal osteoconductive environment to promote the growth of new dense bone, R.T.R. comes in 3 different presentations to suit all the clinical situations.
- Biodentine™, the first biocompatible and bioactive dentin replacement material. Biodentine™ uniqueness not only lies in its innovative bioactive and “pulp-protective” chemistry, but also in its universal application, both in the crown and in the root.
- Racegel, a unique reversible thermo-gelifiable gel for gingival preparation that creates a dry and clean environment for high quality impressions.

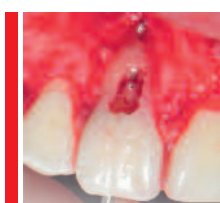Content



Use of R.T.R. and PRF as filling material in post extraction sockets

Patricio González, Omar González,
Claudia Zenteno, Joaquín Urrizola

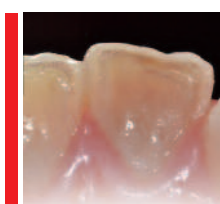
04



Biodentine™ in corrective surgery: A solution to the root perforations

Alicia Caro Molina

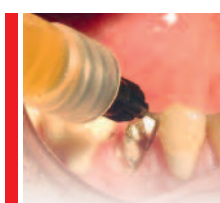08



Apexification as treatment in immature apex using Biodentine™

Mercado Velázquez Cynthia

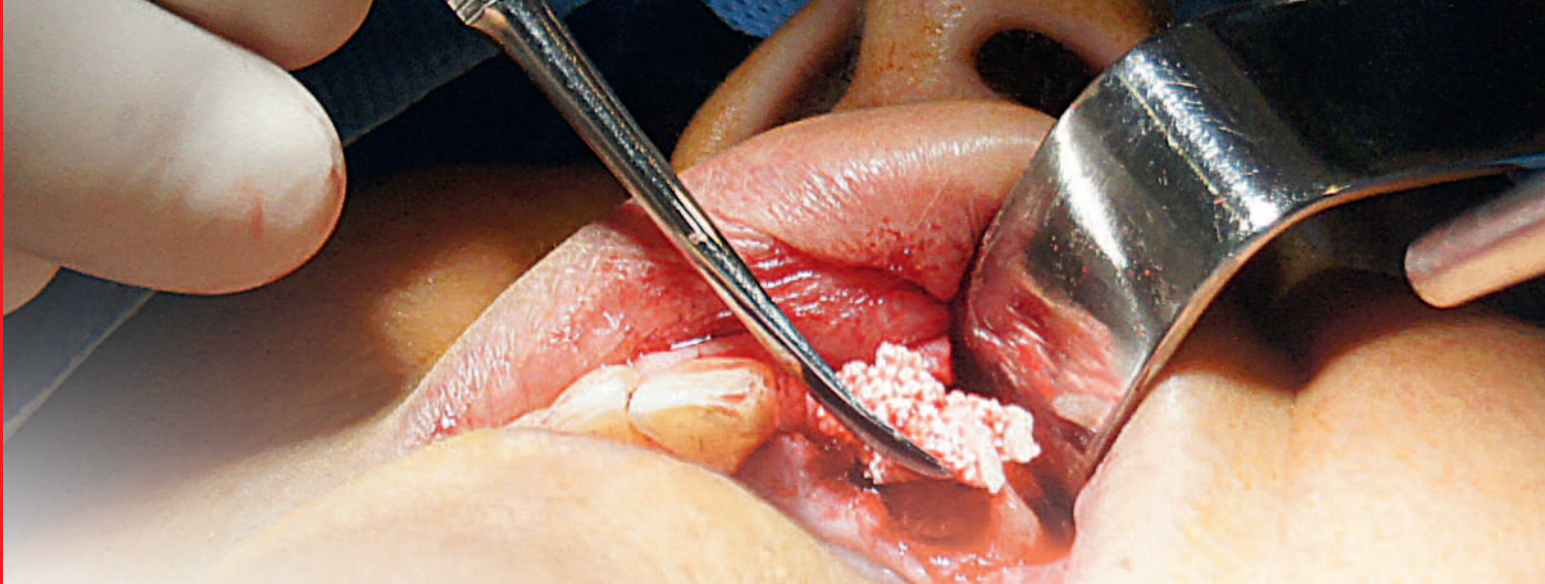
14



Gingival preparation with Racegel

Luis Fabián Brotos Duhart

19



Use of R.T.R. and PRF as filling material in post extraction sockets

Dr. Patricio González, Dr. Omar González, Dr. Claudia Zenteno, Dr. Joaquín Urrizola
San Sebastian University, Concepción, Chile

Introduction

Currently, the great majority of the extractions are followed by the immediate use of an implant. In some cases the bone volume is not enough to get the desired primary stability, in that case the clinician will need a first surgery where he would win the bone volume required for that implant, and then a second surgery for the final placement of the implant¹.

To obtain the best results possible, the use of a material that guides the bone regeneration is necessary and β -tricalcium phosphate has proven a great efficacy in helping and maintaining the space for the bone regeneration². In addition to

this, the use of platelet rich fibrin (PRF), a second generation platelet concentrate, that acts as a bioscaffold and has multiple growth factors, can accelerate the process of regeneration³.

The characteristics of R.T.R. are its porosity, that helps in the formation of stronger clots, no systemic toxicity and its resorbability that promotes new bone formation in 3 - 6 months. In synergy with this, PRF thanks to its growth factors promotes the new bone formation and, as an optimized clot, helps to get a faster regeneration of the extraction socket and to have a more predictable outcome^{4,5}.

Case report

A 59 year-old woman, systemically healthy and under periodontal treatment, requires the extraction of the left central incisor (2.1) and left lateral incisor (2.2) to be rehabilitated with osseointegrated implants in a second surgery after the alveolar preservation surgery. The lateral incisor presents a radiolucent lesion around the root and no presence of vestibular wall in 2.1. The surgery

was explained to the patient with the risks and benefits and an informed consent was signed. Local anesthesia was administered to the patient. The teeth were extracted with a forceps taking care to preserve the alveolar walls. After the extraction, a full mucoperiosteal flap was elevated which allowed to confirm the great loss of alveolar bone.

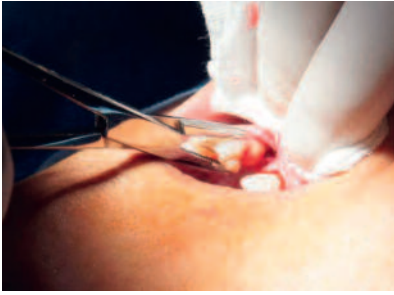

Fig. 1: Extraction of 2.1

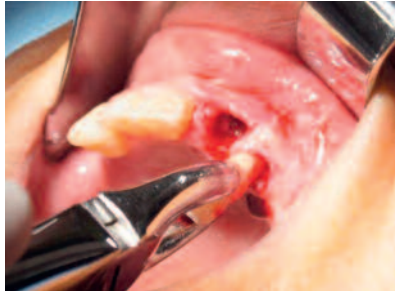


Fig. 2: Extraction of 2.2

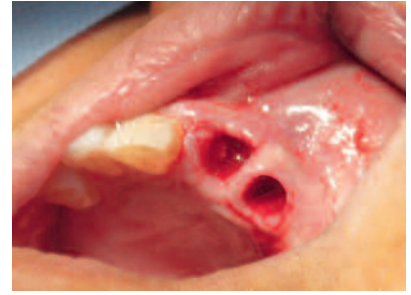


Fig. 3: The two alveolar sockets

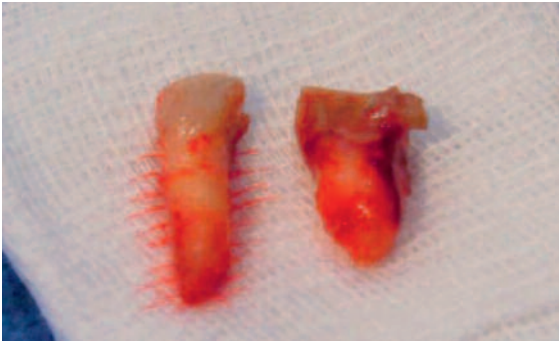


Fig. 4: The extracted dental pieces

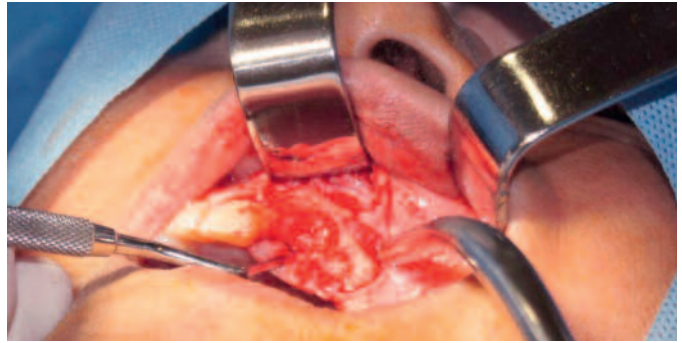


Fig. 5: Mucoperiosteal flap elevation

Two blood tubes of 9 ml without anticoagulant were obtained from the patient's ante cubital vein for the production of the PRF. The PRF was produced following Choukroun protocol (3000 rpm by 10 min)^{6, 7} and then compressed into two membranes^{8, 9}. The exudate of the compression was collected with a syringe to be applied over the bone graft. One of them was cut and mixed with R.T.R. fragments to be used as the bone graft and the other one was

used as a membrane^{6, 7}.

R.T.R. was fragmented to get a better adaptation to the defects, and once mixed with the PRF membrane, it was placed in the defects. When the graft was ready the exudate was then applied to it. When suturing, the membrane was applied with a pocket technique to ensure its intimate contact with the bone graft¹⁰. The flap was closed with simple stitches and in first intention.




Fig. 6: R.T.R. cone

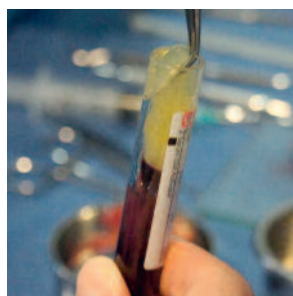

Fig. 7: PRF clot

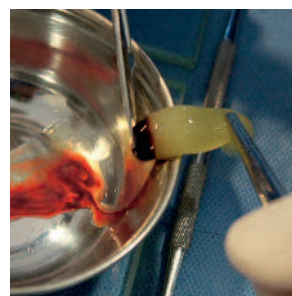


Fig. 8: PRF clot before mixing with the graft

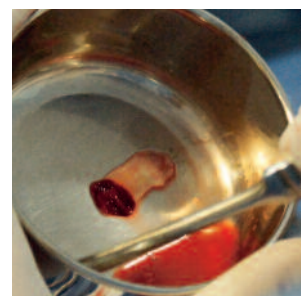


Fig. 9: PRF membrane mixed with the graft

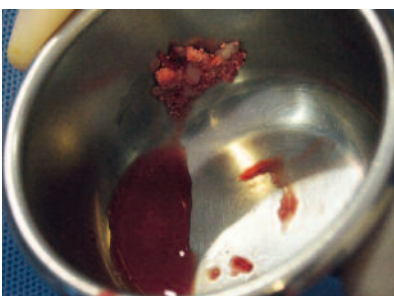

Fig. 10: Application of the graft

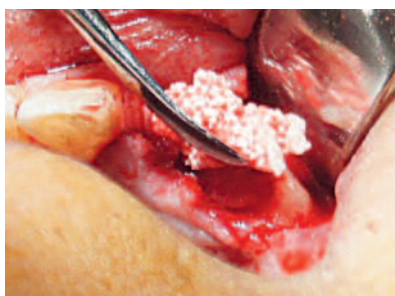

Fig. 11: Graft placed

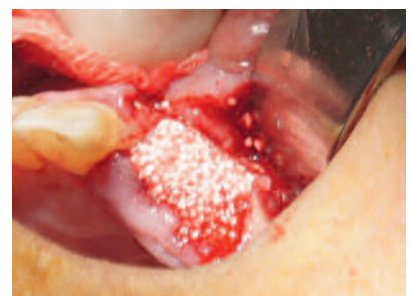

Fig. 11: Graft placed

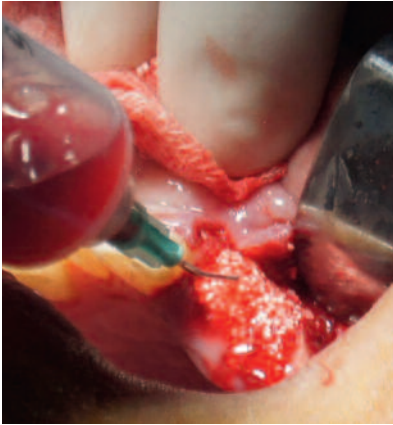

Fig. 12: Application of the exudate

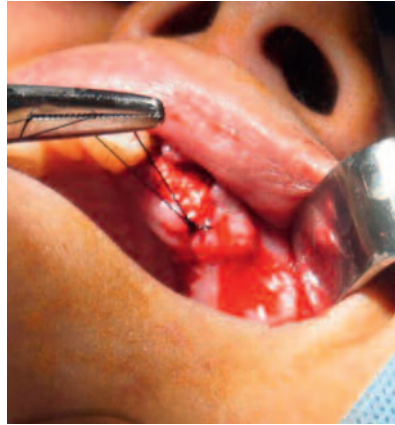

Fig. 13: Suture

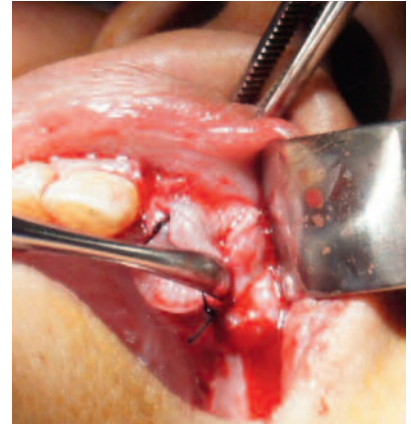


Fig. 14: PRF membrane

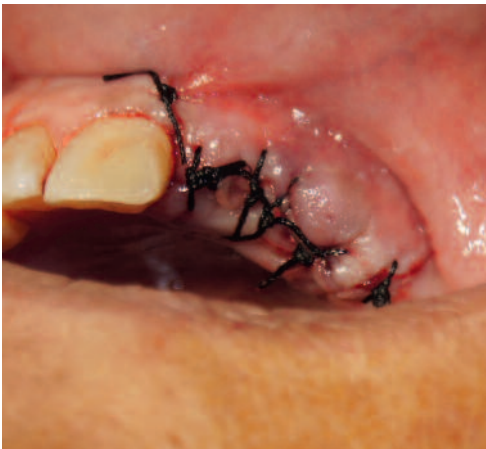

Fig. 15: Immediate post-operative situation

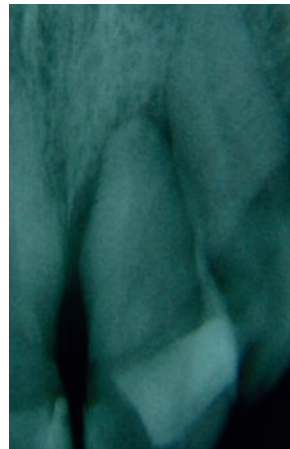

Fig. 16: X-ray pre-operative

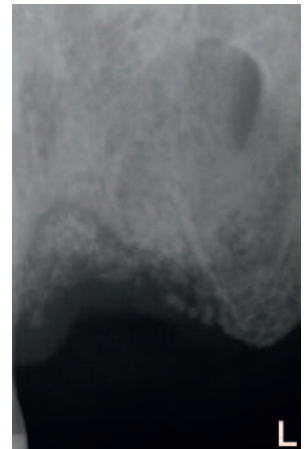


Fig. 17: X-ray 1 week post-operative

Discussion

The use of platelet concentrates has become popular during the last 10 years, but among them, one of the simplest and cheapest form has raised as one of the best options, the PRF. As a cheap and free access platelet concentrate, its homogenous bibliography supports its good results as an adjuvant in multiple surgeries like sinus lifts, intrabony defect fillings and of course bone grafting^{6, 7}. Although PRF acts as a bioscaffold, it lacks a good resistance and resorbs in around 28 days, thus the use of a material that sustains bone regeneration is necessary, and that material is R.T.R.

Beta-Tricalcium Phosphate has a proven biocompatibility, osteoconductivity and resorbability. As it resorbs, R.T.R. releases calcium and phosphate ions which help in the neo formation of the bone¹¹.

The combination of two materials with not known local or systemic toxicity and that synergize in the formation of bone should reduce the time needed to place the implants. The bone graft that best suits the PRF characteristics still needs further and deep study, but R.T.R. seems to perfectly fit all the characteristics to maximize the bone regeneration.



Authors

Dr. Patricio González Catalán: Oral Surgeon, University of Concepción, Chile. Specialist of Periodontics and Implantology, University of Chile. Specialist of Oral Pathology, University of Concepción, Chile. Resident in department of Maxillofacial Surgery, St Sebastian University, Chile. Ex-docent of Periodontics Chair, University for Development, Concepción, Chile. National and international speaker.

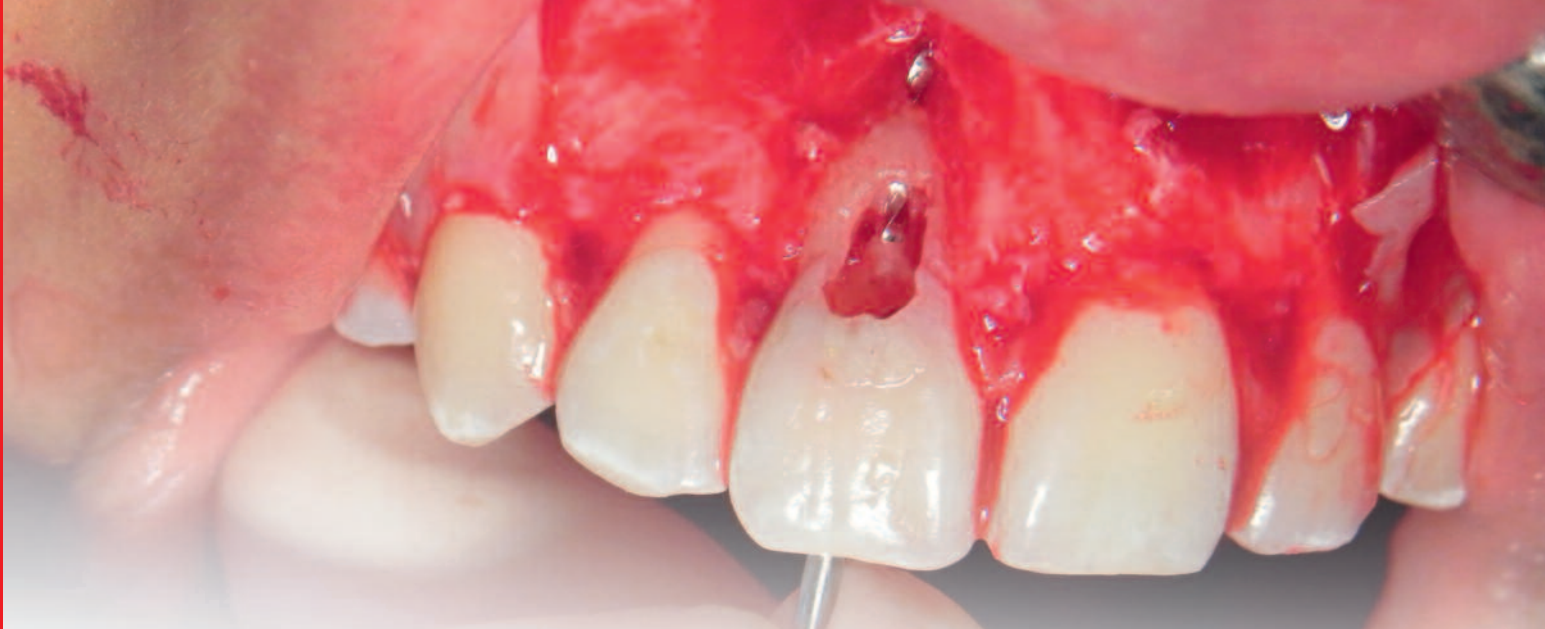Dr. Omar González: Oral Surgeon, University of Concepción, Chile. Docent, Chair of Anatomy, St Sebastian University, Concepción, Chile. Resident in department of Oral Rehabilitation, St Sebastian University, Concepción, Chile.

Dr. Claudia Zenteno: Specialist of Oral Rehabilitation. Master in Education in Catholic University of the Most Holy Conception, Chile. Docent coordinator of adult clinic and pre-clinic in San Sebastián University, Concepción, Chile. Secretary and active member of the Society for Oral Rehabilitation, University of Conception, Chile.

Dr. Joaquín Urrizola: Degree in Dentistry, St Sebastian University, Concepción, Chile. Pending certification.

References

1. Ten Heggeler, J. M. a G., Slot, D. E. & Van der Weijden, G. a. Effect of socket preservation therapies following tooth extraction in non-molar regions in humans: a systematic review. *Clin. Oral Implants Res.* 22, 779–88 (2011).
2. Geurs, N. et al. Using growth factors in human extraction sockets: a histologic and histomorphometric evaluation of short-term healing. *Int. J. Oral Maxillofac. Implants* 29, 485–96 (2014).
3. Kang, Y.-H. et al. Platelet-rich fibrin is a Bioscaffold and reservoir of growth factors for tissue regeneration. *Tissue Eng. Part A* 17, 349–59 (2011).
4. Dohan Ehrenfest, D. M., Del Corso, M., Diss, A., Mouhyi, J. & Charrier, J.-B. Three-dimensional architecture and cell composition of a Choukroun's platelet-rich fibrin clot and membrane. *J. Periodontol.* 81, 546–55 (2010).
5. Choukroun, J. et al. Platelet-rich fibrin (PRF): a second-generation platelet concentrate. Part IV: clinical effects on tissue healing. *Oral Surg. Oral Med. Oral Pathol. Oral Radiol. Endod.* 101, e56–60 (2006).
6. Del Corso, M. et al. Current Knowledge and Perspectives for the Use of Platelet-Rich Plasma (PRP) and Platelet-Rich Fibrin (PRF) in Oral and Maxillofacial Surgery Part 1: Periodontal and Dentoalveolar Surgery. *Curr. Pharm. Biotechnol.* 13, 1207–1230 (2012).
7. Simonpieri, A. et al. Current Knowledge and Perspectives for the Use of Platelet-Rich Plasma (PRP) and Platelet-Rich Fibrin (PRF) in Oral and Maxillofacial Surgery Part 2 : Bone Graft , Implant and Reconstructive Surgery. 1231–1256 (2012).
8. Dohan Ehrenfest, D. M. How to optimize the preparation of leukocyte- and platelet-rich fibrin (L-PRF, Choukroun's technique) clots and membranes: introducing the PRF Box. *Oral Surg. Oral Med. Oral Pathol. Oral Radiol. Endod.* 110, 275–8; author reply 278–80 (2010).
9. Kobayashi, M. et al. A proposed protocol for the standardized preparation of PRF membranes for clinical use. *Biologicals* 40, 323–9 (2012).
10. Dohan Ehrenfest, D. M., Doglioli, P., de Peppo, G. M., Del Corso, M. & Charrier, J.-B. Choukroun's platelet-rich fibrin (PRF) stimulates in vitro proliferation and differentiation of human oral bone mesenchymal stem cell in a dose-dependent way. *Arch. Oral Biol.* 55, 185–94 (2010).
11. Observations, H., Brkovic, B. M. B. & Prasad, H. S. Pratique Simple Preservation of a Maxillary Extraction Socket Using Beta-tricalcium Phosphate with Type I Collagen : Preliminary Clinical and. 74, 523–528 (2008).



Biodentine™ in corrective surgery: A solution to the root perforations

Dra. Alicia Caro Molina
Surgeon-Dentist - Specialist in Endodontics

The objective of this presentation is to show the use of Biodentine™ in the surgical treatment of root perforations of pathological origin, whether by Endo or Exorizalis. The first option is the intracanal sealed using microscopy and conventional endodontics¹, but when the extent of the defect requires it or because the intracanal seal has failed, the alternative to follow is the surgical procedure known cone Corrective Surgery, a Paraendodóntica type of surgery*.

The article refers to one of the clinical cases treated successfully using this versatile new material.

Introduction

Root resorption is a serious dental problem because it affects the root structure of the teeth, negatively affecting prognosis thereof. Clinical handling is not easy and is also little predictive often extraction indicating whether the extent of reabsorption is extensive. The causes are not yet clear, however the associated factors are known: a history of trauma, fixed prostheses, chronic infections, polished root, whitening, orthodontic movements among others².

The most affected teeth are the upper antero in young patients, where the replacement of the natural tooth with an implant is sometimes not possible for any of the following factors: - age (lack of bone maturation of the jaws) -for cost -

or because aesthetics is highly committed. It is known that the emergence of a single implant in the anterior sector, not always, meets all the features found in a natural tooth, then the option to preserve the natural tooth takes great relevance.

Corrective surgery is a solution that has shown very good results, but no precise protocols for each case since many factors involved. The emergence of new materials and new microsurgical techniques for retrieving Paraendodóntica wall lost root and stop the process rizalasis, so it is an indication that must be considered when these cases are presented.

* Own term coined by University of Valparaíso for all types of surgeries that resolve pathologies of endodontic origin that can not be resolved with a conventional endodontics. Derived and modified from the original term "Paraendodóntica Surgery" consensus in the IV International Congress of endodontics, in Rio de Janeiro, in 1979, to refer to this type of intervention.

Root perforation

Rizalis drilling root defined as the loss of root tissue with or without communication with the exterior of the same³.

They are usually asymptomatic and usually presenting complaint stems from a complication of them or just for radiographic finding during a routine check. When drilling rizalis diagnosed, treatment should be as soon as possible as periodontal damage occurred is proportional to time as well as the degree of bacterial contamination. Known that the more time, the higher the degree of formation and evolution of a more complex biofilm. That is why among the factors that can handle and helps significantly to forecast, is the opportunity to correct the defect, especially

if the drilling communicates with Saliva and oral cavity, since the risk of contamination is higher. There are several classifications of pathological root resorption, but have chosen this simple.

They are classified into:

A - Internal resorption, no piercing

B - Internal, perforating resorption

C - External root resorption

C.1. inflammatory root resorption

C.2. resorption by substitution

C.3. idiopathic or cervical resorption.

Corrective surgery is defined as surgery that repairs all types of perforations occurred in the dental roots, whether iatrogenic and pathological origin.⁴

Treatment

Currently the dental rating has been changed, since modern concepts of health and beauty, especially from the point of view of patients related to Bio-aesthetic Oral, make all the teeth in the mouth have a high value, especially if they are the anterior and tends to preserve natural teeth. Therefore, any treatment aimed at sealing a puncture and that positions said teeth in the mouth is a clear indication.

Treatment protocols will depend on:

Firstly if this is piercing or not. That is why the indication of CT scan should be requested to make a correct diagnosis.

If not perforator: the indication is intracanal sealing via microscopy.

If piercing, it will depend on the size of it: small extension, no more than 2-3 mm should be attempted intracanal sealed. Extension beyond 4 mm recommend Corrective Surgery. It is important to note that this is general information, since in each case must be considered symptoms, location of the tooth, surgical skills, materials available, etc.

Another factor to consider is the default root communication with the oral environment, especially in the selection of material, consider setting time, dissolution, aesthetic commitment, etc.

As for the materials used in the sealing of perforations may be mentioned: the amalgam Ionomer glassy, mineral trioxide aggregate (MTA) and of Septodont Biodentine™ lately. MTA is the most investigated, with excellent results due to its high biocompatibility, adhesion to the walls of the tooth and integration into the surrounding bone tissue, which finally results in a significant low microfiltration⁵, resulting in practice in an excellent material for the treatment of the perforations⁶. Microscopic observations periodontal surrounding the MTA have demonstrated their recovery and repair, in addition to formation of new cementum about this material^{7,8}. The drawback of the MTA is its difficult handling, slow setting, 3-4 hours, with the possibility of solubilized by being in contact with oral fluids as this process occurs. The Biodentine™, on the other

hand has a fast setting, so if perforations are communicated to the oral cavity use is recommended. Another factor to Consider the Biodentine™ is their coloration, similar to the dental tissues and produces no staining of these, as if it the MTA.

Recommend that once the material has been placed filling and sealing of the root drilling, this is protected with a membrane, the resorbable type, regardless of the material used. You can use a collagen membrane or the like or a membrane Rica Platelet Fibrin (PRF) blood from the patient, in this way we avoid the epithelial tissue that grows faster invade the area, giving more time to the bone to repair the surrounding osteolytic bone lesion and the remainder is over drilling repaired. Recomos membrane using FRP, because being an autograft avoids the risk of rejection, accelerates the healing of lesions, whose combined composition platelet rich in growth factors and leukocytes, which reduces the risk of postoperative infection, and thus allows the bone tissue repair better and faster^{9, 10}.

Case description: Corrective surgery as a solution to a perforating rizális using as filler: Biodentine™.

Background Patient: Female, 23 years, no relevant medical history, was with Fixed Orthodontics 10 years ago. 1 month ago began with an acute and spontaneous symptoms, increased volume in relation to vestibular tooth 1.1, consulted private dentist and underwent trepanation pulp was derived endodontic specialty clinic Valparaiso University.

Clinical examination discoloration on cervical third volume increase buccal cavity and probing cervical, periodontal pocket of 10mm, bloody discharge is observed (Fig. 1).

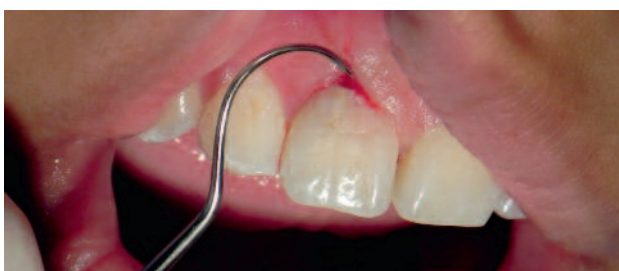

Fig. 1

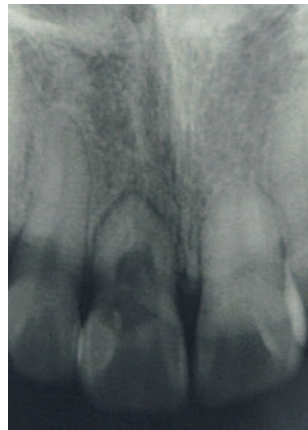

Fig. 2

When radiographic examination is observed short root, periodontal ligament fully thickened, extensive root resorption, rectangular residual ridge with vestibular depression, is displayed narrow root canal, untreated (Fig. 2).

When examining Computed Tomography note: Commitment buccal bone plate, vestibular rizális in the middle third and cervical cancer, cervical third perforated zone in labial, apical commitment (Fig 3 and 4).

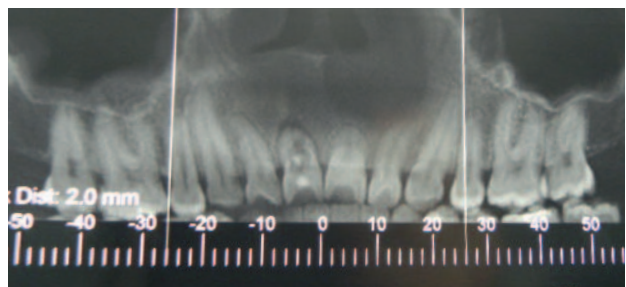


Fig. 3

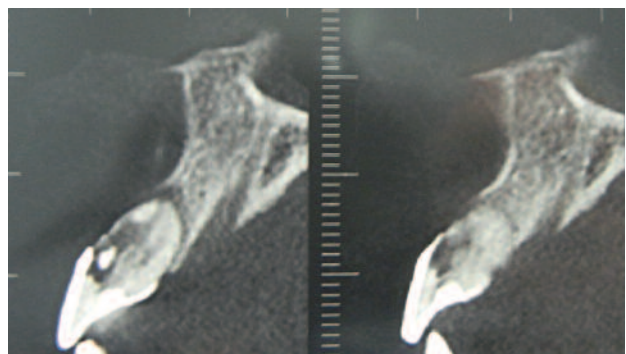


Fig. 4

Clinical Diagnosis: Rizális piercing with oral communication medium.

Pulp Diagnosis: Tooth intervened.

Periapical Diagnosis: symptomatic apical periodontitis.

Drilling Type: Class F Kim and Kratchamn, 2006¹¹ (presence of root perforation with complete loss of vestibular table, but no tooth mobility).

Corrective Surgery:

Premedication: Amoxicillin 2 g. 1 hour before surgery, 15 mg meloxicam. 1 hour before surgery, mouthwash CHX 0.12%, 2% Chlorhexidine topical.

Anesthesia infiltration with cloridrato of 4% articaine, epinephrine 1 / 100,000 of Septodont, 2 tubes.

Dieresis: seminwman flap, intrasulcular, full thickness, fig. 5. Removal of the involved tooth tissue and granulation tissue. Vestibular complete loss of bone tissue and extensive root wall loss is observed (Fig. 6). It channels the canal and is prepared with limes k to N ° 110, filled with gutta-percha and sealer (Fig. 7) and defect filling with Biodentine™ (Fig. 8a, b, c, d).

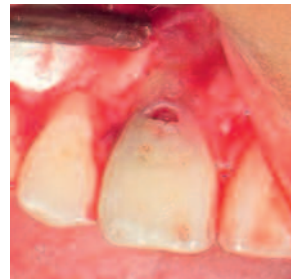
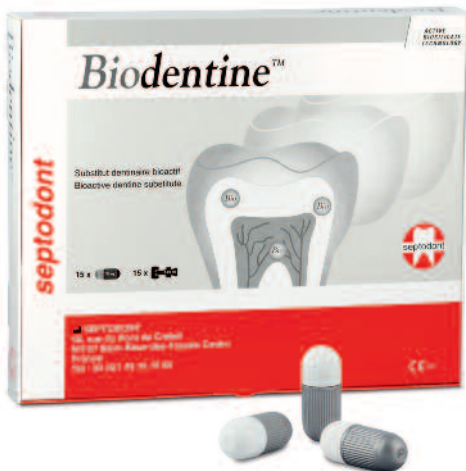
Fig. 5

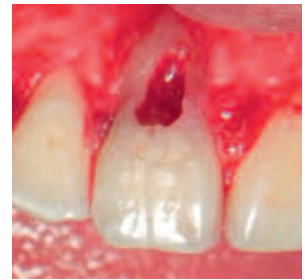

Fig. 6

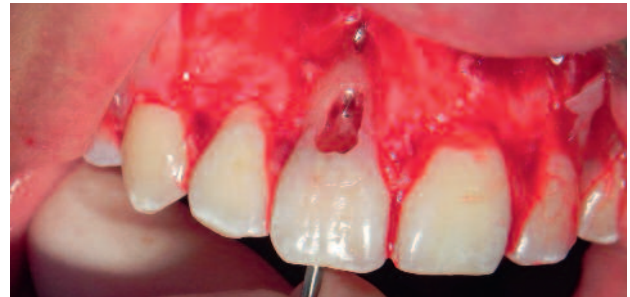


Fig. 7



Fig. 8a

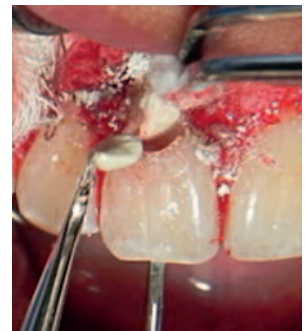

Fig. 8b

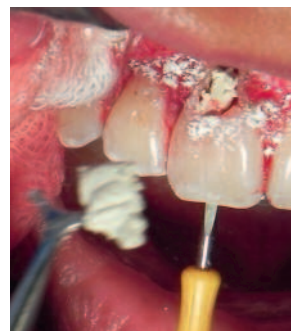

Fig. 8c

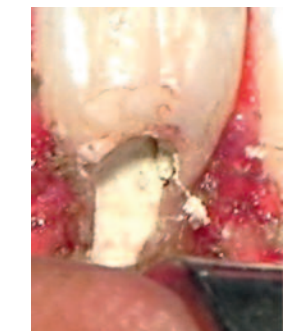

Fig. 8d

Subsequently Biodentine™ with glass ionomer, (Fig. 9) and this in turn with an autogenous fibrin membrane Rica Platelet covered (Fig. 10a, b).

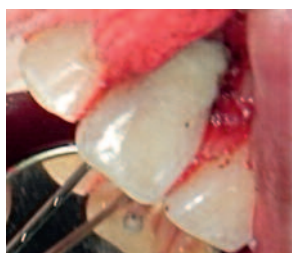

Fig. 9

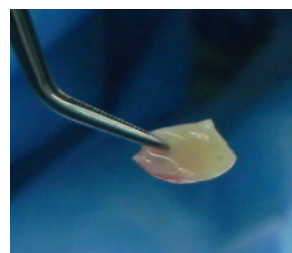


Fig. 10a

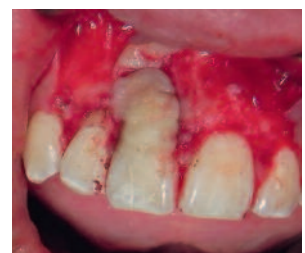
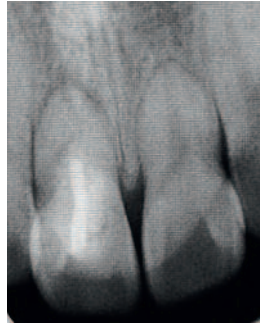
Fig. 10b

Close and suture. Indications postoperative: Meloxicam 15 mg, analgesics SOS, local ice, habitual hygiene, soft diet, control and removal of sutures in four days. Immediate post operative Control



Radiographic and Clinical Control (Fig.11, 12a, 12b), 6 months.

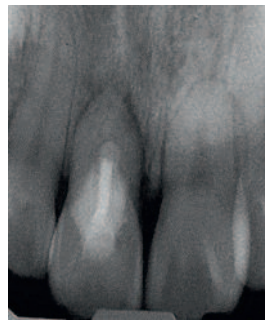


Fig. 11

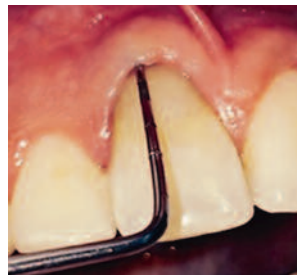
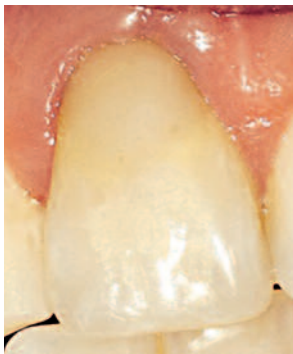
Fig. 12

Conclusions

- Successful Surgery Endodontic depends on the complexity of the case, but also the skill and expertise of the surgeon.
- There is no established protocol against its treatment, since the variables involved are many.

He can consider alternative treatment Biodentine™ sealing large perforations. She holds appropriate for this type of case properties (suitable working time, relatively easy to handle, white color, good sealing, biocompatible, among others).

- Place Membrane on the correction of the defect favors prognosis because it acts as an insulator of invasive cells, and promote bone formation.

Fiber autograft platelet rich recommended by the absence of rejection.

- Maintain natural teeth in the mouth is highly valued by patients. Corrective surgery provides an alternative treatment for teeth with extensive pathological root resorption.



Author: Dra. Alicia Caro Molina

Surgeon-Dentist.

Specialist in Endodontics.

Head of Chair Endodontics, University of Valparaiso.

Specialty Program Director Endodontics, University of Valparaiso.

Graduate Program Director and Creative Problem Resolution Surgical Endodontics.

Magister in curriculum development and educational projects.

President Society of Endodontics Valparaiso, V Region, Chile.

References

1. Arnaldo Castellucci MD, DDS, ENDODONTICS, Vol III, cap 34, Microsurgical Endodontics.
2. Gutmann JL, Dumsha TC, Lovdahl PE, Hovland EJ, editores. Problem Solving in Endodontics. 4a. edición. Mosby, 2007:311-335.
3. American Association of Endodontists: Glossary of Endodontic Terms. 7th ed. Chicago: American Association of Endodontists; 2003.
4. Caro M. Alicia, Revista canal Abierto de la Sociedad de Endodoncia de Chile, ISSN 0718-2368, N° 28, septiembre 2013, pag. 6-10
5. Seung-Jong Lee, M. Torabinejad, et al. Sealing Ability of a Mineral Trioxide Aggregate for Repair of Lateral Root Perforations. (1993) J. Endod, Seoul, Korea,19(11):541-4
6. Renato Menezes, DDS, MS, Ulisses Xavier da Silva Neto, DDS, MS, Everdan Carneiro, DDS, MS, Ariadne Letra, DDS, MS, Clovis Monteiro Bramante, DDS, MS, PhD, and Norberti Bernadinelli, DDS, MS, PhD, MTA Repair of a Supracrestal Perforation, JOE — Volume 31, Number 3, March 2005.
7. Lee SJ, Monsef M, Torabinejad M. Sealing ability of a mineral trioxide aggregate for repair of lateral root perforations. J Endod 1993;19:541– 4.
8. Pitt Ford TR, Torabinejad M, McKendry DJ, Hong CU, Kariyawasam SP. Use of mineral trioxide aggregate for repair of furcal perforations. Oral Surg Oral Med Oral Pathol Oral Radiol Endod 1995;79:756–63.
9. Kim S. Endodontic microsurgery. In: Cohen S, Burns RC, eds. Pathways of the pulp, 8th ed. St. Louis: Mosby, 2002;718 –21.
10. Dohan DM, Choukroun J, Diss A, Dohan SL, Dohan AJ, Mouhyi J, Gogly B. Oral Surg Oral Med Oral Pathol Oral Radiol Endod. 2006 Mar;101(3):e51-5. - Platelet-rich fibrin (PRF): a second-generation platelet concentrate. Part III: leucocyte activation: a new feature for platelet concentrates?
11. Kim S, Kratchman S. Modern Endodontic Surgery Concepts and Practice: A Review. J Endod 2006; 32:601-623.

Download the complete series

Septodont Case Studies Collection

www.septodont.com





Apexification as treatment in immature apex using Biodentine™

C.D.E.E. [Dentist Specializing in Endodontics] Mercado Velázquez Cynthia
C.D [Dentist] Gómez Martínez Guillermo
C.D. [Dentist] Cuahonte Sanchez Anali
UNITEC (Universidad Tecnológica de México) [Technological University of Mexico]

Introduction

Endodontic treatment of permanent teeth with necrotic pulp and incomplete root formation, with or without apical pathology, raises several clinical challenges. There is the risk of inducing a fracture of the dentine wall during instrumentation or extrusion of the gutta-percha toward the periapical tissue during compacting of the root canal filling. Endodontic treatment options for non-vital permanent teeth with immature apices conventionally include surgical techniques, use of calcium hydroxide to achieve apexification, placement of mineral trioxide aggregate (MTA) as an apical stop to favour apexification and to minimize apical extrusion of filling material such as gutta-percha. Naseem and Wigler^{1,2}.

In 1961 Nygaard-Ostby³, pioneer of regenerative endodontics procedures, demonstrated that new vascularized tissue can be induced in the apical third of the root canal of mature teeth with treatment of canals with necrotic pulps

and apical lesions. This was achieved through the creation of a blood clot in the apical third of a root canal cleaned and disinfected with a manual instrument inside the apical root canal extending to just before filling of the root canal. In 1966, Rule and Winter⁴ documented the development of the roots and formation of an apical barrier in cases of pulp necrosis in children. Occasional cases of regeneration of apical tissues after traumatic avulsion and replantation led to the search for the possibility of regeneration of all pulp tissue in a necrotic tooth.

Cvek⁵, in his study, found that the frequency of root fracture in the cervical third was markedly higher in immature teeth with endodontic treatment than in mature teeth, and that it varied in incidence from 28% to 77%, depending on the stage of development of the roots. This finding emphasized the importance of preserving the pulp vitality of immature teeth involved in dental

trauma or deep caries. Frank⁶ published an article that describes a clinical technique intended to induce apical closure. Through repeated use of calcium hydroxide (Ca(OH)₂) dressings during a period of 3 to 6 months, the author demonstrated that it was possible not only to induce healing of the apical lesion, but also to induce closure of the apex of the root with calcified tissue (apexification).

An alternative with Ca(OH)₂ to achieve apexification was suggested by Torabinejad and Chivian⁷. They suggested that cleaning the root canal and sealing the open apex with MTA in 1 or 2 visits could decrease the risk of overfilling of the root canal and promote apical repair. Simon⁸ evaluated the results of this technique in just 1 appointment in teeth with open apices and apical lesions, and concluded that it was not a reasonable and predictable treatment alternative. Although this procedure offered a favourable result and the work requires only 1 appointment⁹, it still did not do much to improve the apexification technique because it has 2 deficiencies of Ca(OH)₂: the predisposition of the root to fracture and the failure to stimulate root development⁵. These deficiencies led doctors to continue the search for a procedure that promotes post-treatment pulp regeneration, dentine formation and root development.

According to the Statement of the American Association of Endodontists on regenerative procedures¹⁰, there are currently no evidence-based guidelines to support a protocol that provides the most favourable outcome in the treatment of infected immature permanent teeth. A recently mixed aqueous paste of Ca(OH)₂ has a pH of 12.5 and is potentially toxic for bacterial and human cells. However, several favourable biological properties have been attributed to it when used clinically. It is antimicrobial, has the ability to dissolve necrotic tissue in the root canal, and can induce apical closure through the formation of hard tissue.

Due to its high pH, some authors affirm that the use of Ca(OH)₂ in revascularization can destroy cells vital for the repair process².

However, apexification induced with calcium hydroxide has several limitations¹¹. It can require 6 to 24 months for barrier formation. The barrier formed is often not porous and continuous or compact, and therefore requires canal filling after barrier formation, with all its inherent problems of achieving fluid-tight hermetic closure without breaking the tooth. Even if successful, apexification can only induce a hard tissue barrier at the apex. Furthermore, root development does not occur. An intracanal calcium hydroxide dressing can also make the tooth brittle because of its hygroscopic behaviour¹². Hoshino et al.¹³ introduced a combination of medications called triple antibiotic paste, which consists of ciprofloxacin, metronidazole, and minocycline, which they affirmed was sufficiently potent to eradicate bacteria from the dentine of the infected root and promote healing of apical tissues. The effect of minocycline is dentine discoloration, so internal whitening is recommended following treatment of the tooth.

MTA is a biocompatible material, has osteoinductive properties, and hardens in the presence of moisture, and treatment can be completed in a single session. However, it does not reinforce the remaining tooth structure, but has disadvantages such as difficult handling and bismuth oxide pigmentation, and a setting time of 48 hours minimum¹.

Biodentine™ is a bioactive tricalcium silicate in which secretion of TGF-β1 from pulp cells increases significantly¹⁴. Main advantages of this material have been reported as its ability to create a firm anchoring to dentine, its bioactivity which leads to the formation of reparative dentine, and improved mechanical properties, which are similar to dentine. The^{15,16} differentiation of odontoblast cells confirms that material's bioactivity has been observed and it increases cell proliferation and biomineralization¹⁶. Extended release of calcium ions (28 days)¹⁷, formation of thicker dentinal bridges compared with MTA¹⁸ setting time of 15 minutes, in addition to its non-pigmentation.

Case report

Male patient, 9 years old, who came to the UNITEC clinic, to the Graduate School for Paediatric Dentistry, from where he was referred to the Graduate School for Endodontics, mentioning discomfort in tooth #11. Clinically, no changes were seen. The corresponding x-rays were taken and an open apex was seen in tooth #11. Sensitivity tests were done, in which he did not respond to CO₂, responded with pain to percussion, and with no pain to mastication and palpation. The probe is 1 on all faces of the tooth. According to the previously mentioned diagnostic tests, the pulp and periapical diagnosis was Pulp necrosis / Chronic apical abscess with immature apex.

The option of Apexification treatment through the apical barrier with Biodentine™ was selected.

Treatment was carried out over 2 appointments. At the first appointment, local anaesthesia was administered with 3% Scandonest (Septodont, Saint-Maur-des-Fossés, France), followed by placement of the rubber dam to isolate the operatory field with interproximal wedjets. Access was then carried out with the number 4 round bur. 20 mm measurement of the root canal was taken and instrumentation was carried out with the #90 file, irrigating abundantly with 5.25% sodium hypochlorite throughout the treatment, and leaving calcium hydroxide as intracanal medication for 1 week, sealing the chamber with Teflon and Provisit.

At the second appointment, the calcium hydroxide was removed with 5.25% sodium hypochlorite and 17% EDTA. Then, the final irrigation protocol with 5.25% sodium hypochlorite, saline solution, and 17% EDTA was carried out. All solutions were carried out with active irrigation. The canal was dried with paper tips. Then, a collagen matrix was placed in the apical third as a stop for the material, and using an amalgam carrier, the Biodentine™ was placed in the canal,

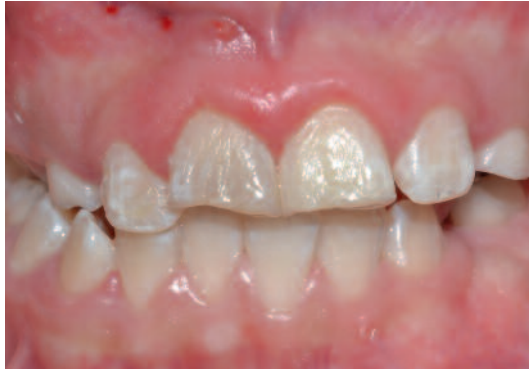
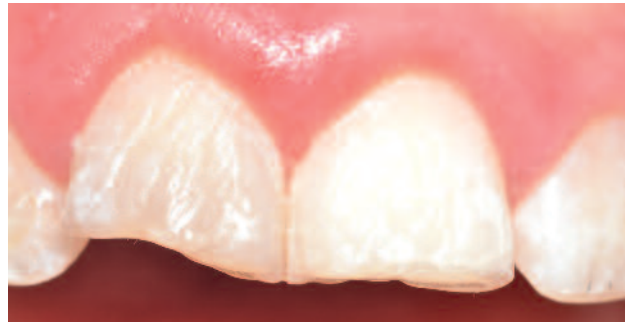
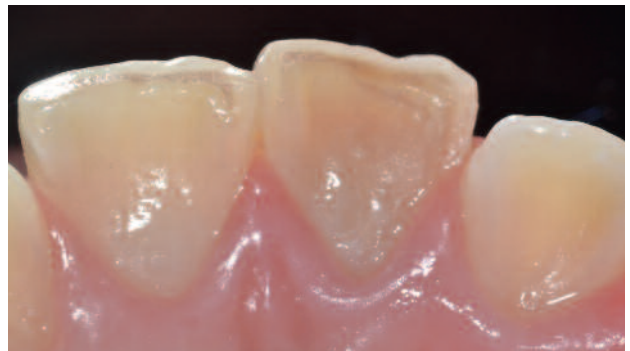Fig. 1: Initial X-ray - November 2013



Buccal View - November 2013



Palatine View - November 2013

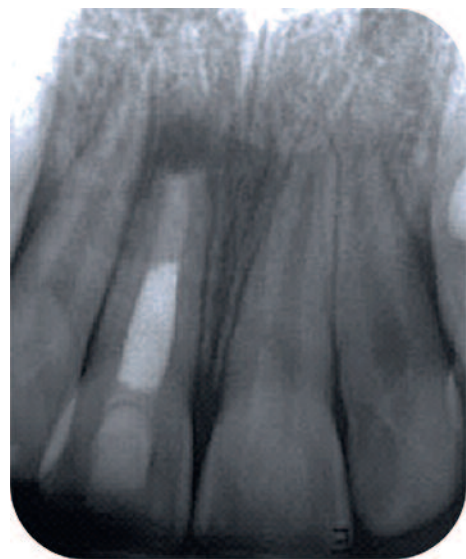


Fig. 2: Rx Final Filling X-ray - November 2013

4 mm of the length of the canal, and compressed; the rest of the canal was then filled with gutta-percha. Finally, resin was placed at the Graduate School for Paediatric Dentistry as final restoration.

Check-ups were done at 6, 10 and 14 months

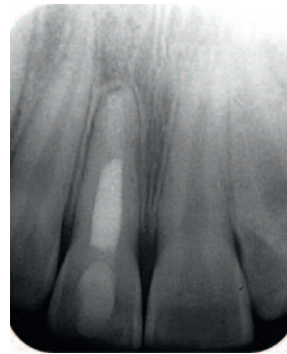


Fig. 3: 10-month check-up - September 2014

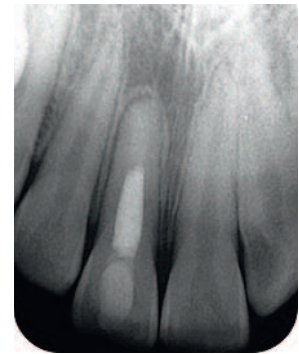

Fig. 4: 14-month check-up - January 2015

Conclusion

In this case, apical closure was achieved using Biodentine™ in which favourable results have been seen since formation of the apex around the material was observed.

Biodentine™ (Septodont) seems to be a good material with high sealing properties, which is

easy to handle, especially in difficult to access areas. Its colour, consistency and hardness mean that the product can be used in places where aesthetics are important and, due to its bioactive characteristics, it can induce the formation of dentine.

Authors:



C.D.E.E. Mercado Velázquez Cynthia

Graduate of the Universidad Tecnológica de México.

Specialty in endodontics, Universidad Tecnológica de México.

Certificate from the Consejo Mexicano de Endodoncia (Mexican Council of Endodontics).

Full professor at the graduate school for endodontics of the Universidad Tecnológica de México.

Full undergraduate professor at the Instituto Politecnico Nacional (National Polytechnic Institute).

Former undergraduate professor of the Universidad Tecnológica de México.

Member of the Asociación Mexicana de Endodoncia (Mexican Association of Endodontists).

Former chair of the Asociación Tecnológica de México de Endodoncia AC. (Technological Association of Endodontists of Mexico).

Opinion leader.

Participation in various national and international courses.

Private practice limited to endodontics and apical surgery in Mexico City.



C.D. Gómez Martínez Guillermo

Dental surgery graduate of the Unam School of Dentistry.

Student in the speciality of endodontics at the Universidad Tecnológica de México.

Certified by the Asociación Dental Mexicana.



C.D. Cuahonte Sanchez Anali

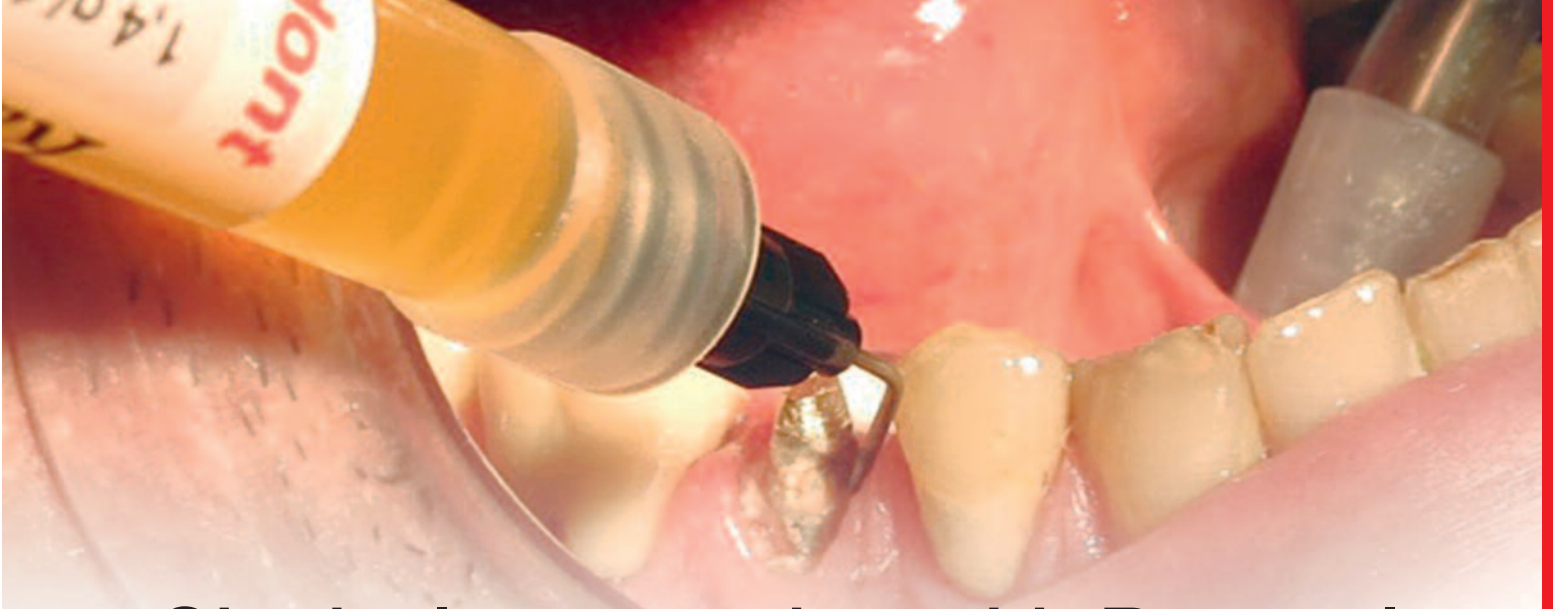Dental surgery graduate of the Instituto Politecnico Nacional Santo Tomas IPN (Santo Tomas IPN National Polytechnic Institute).

Student in the speciality of endodontics at the Universidad Tecnológica de México.

Certified by the Asociación Dental Mexicana.

References

1. Naseem Shah. Efficacy of Revascularization to Induce Apexification/Apexogenesis in Infected, Nonvital, Immature Teeth: A Pilot Clinical Study. *J Endod* 2008; 34: 919-925
3. Ostby BN. The role of the blood clot in endodontic therapy: an experimental histologic study. *Acta Odontol Scand* 1961;19:324-353.
4. Rule DC, Winter GB. Root growth and apical repair subsequent to pulpal necrosis in children. *Br Dent J* 1966;120:586-90.
5. Cvek M. Prognosis of luxated non-vital maxillary incisors treated with calcium hydroxide and filled with gutta-percha: a retrospective clinical study. *Endod Dent Traumatol* 1992;8:45-55
6. Frank AL. Therapy for the divergent pulpless tooth by continued apical formation. *J Am Dent Assoc* 1966;72:87-93.
7. Torabinejad M, Chivian N. Clinical applications of mineral trioxide aggregate. *J Endod* 1999;25:197-205.
8. Simon S, Rilliard F, Berdal A, Machtou P. The use of mineral trioxide aggregate in one-visit apexification treatment: a prospective study. *Int Endod J* 2007;40:186-97.
9. Mente J, Hage N, Pfefferle T, et al. Mineral trioxide aggregate apical plugs in teeth with open apical foramina: a retrospective analysis of treatment outcome. *J Endod* 2009;35:1354-8.
10. American Association of Endodontists. Considerations for Regenerative Procedures. Available at: <http://www.aae.org/Professionals/Content.aspx?id=3496&terms=revascularization>. Accessed October 7, 2012.
11. Kleier DJ, Barr ES. A study of endodontically apexified teeth. *Endod Dent Traumatol* 1991;7:112.
12. Andreasen JO, Farik B, Munksgaard EC. Long-term calcium hydroxide as a root canal dressing may increase the risk of root fracture. *Dent Traumatol* 2002;18:134-7.
13. Hoshino E, Kurihara-Ando N, Sato I, et al. In-vitro antibacterial susceptibility of bacteria taken from infected root dentine to a mixture of ciprofloxacin, metronidazole and minocycline. *Int Endod J* 1996;29:125-30.
14. P. Laurent. Biodentine™ induces TGF-β1 release from human pulp cells and early dental pulp mineralization. *Int. J. End. J* 439-448, 2012
15. Koubi G, Colon P, Franquin JC, Hartmann A, Richard G, Faure MO, Lambert G. Clinical evaluation of the performance and safety of a new dentine substitute, Biodentine™, in the restoration of posterior teeth - a prospective study. *Clin Oral Investig* 2013;17(1):243-9.
16. Zanini M, Sautier JM, Berdal A, Simon S. Biodentine™ induces immortalized murine pulp cell differentiation into odontoblast-like cells and stimulates biomineralization. *J Endod* 2012;38(9):1220-6.
17. Maria Giovanna, et al. In vitro Screening of the appetite-forming ability, biointeractivity and physical properties of a tricalcium silicate material for endodontics and restorative dentistry, *Dent. J*, 2013
18. Andiara De Rossi, Comparison of Pulpal Responses to Pulpotomy and Pulp Capping with Biodentine™ and Mineral Trioxide Aggregate in Dogs, *JOE*, 2014.



Gingival preparation with Racegel

Looking for a quick and excellent option in retraction and hemostasis

Dr. Luis Fabián Brotos Duhart
Private Practice in Montevideo, Uruguay

Introduction

Beyond the great advances in materials, techniques and procedures in the dental laboratory, as well as in impression materials, there remains an undoubtedly critical point in indirect techniques: the achieving of proper gingival retraction and effective control of bleeding and gingival fluid in the critical area of the cut margins at the gingival level of the preparations. This is the area that most often has errors from the standpoint of accumulation of blood, lymphatic exudates and cutting remains.

To achieve quality results in all work performed in regular practice, it is not only necessary to have periodontal health parameters, such as a lack of gingival inflammation and periodontal pockets through treatment and prevention carried out with the patient, as well as identification of the different dental, periodontal, bone, biotypical and anatomical particularities of each case, but also to have a fast, predictable and effective method of gingival retraction and hemostasis that makes it applicable to 100% of cases.

Of course, these features are not always fulfilled by techniques such as the retraction cord in all its different forms, tissue laser, pastes, gels, etc.

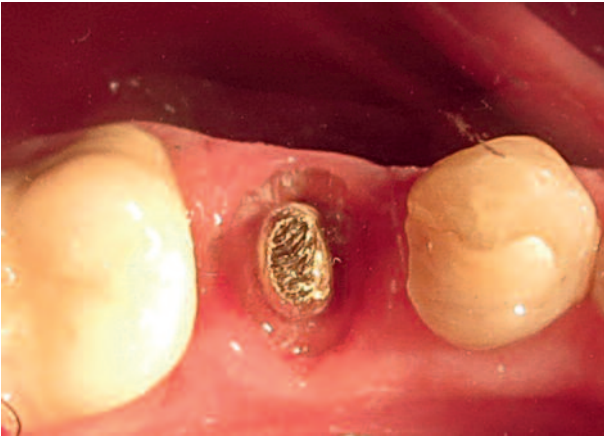These materials used alone or in combination with others can become effective, but barely meet the need of ease of application, which is essential for it to be used in all clinical cases.

The most significant point is that, especially in thin gingival biotypes, over-manipulation of the tissue will result in a possible gingival recession. Racegel is ideal for this type of case since it brings together several advantages, and because its presentation in the form of a syringe with a fine dispenser tip allows a perfect application around the preparation. Furthermore, its main features are:

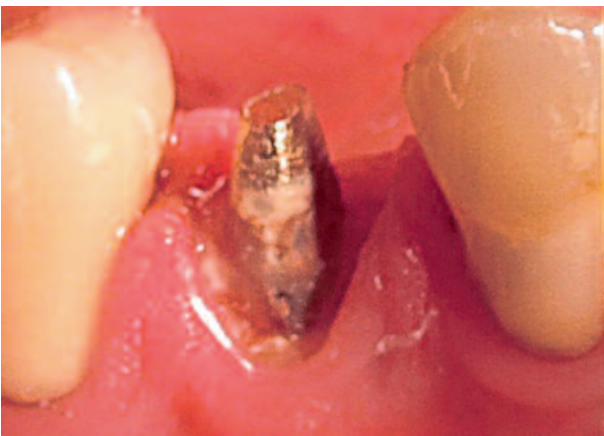- Thermodynamic chemistry that creates increased viscosity in the oral cavity, which is reversed when water is applied for easy removal.
- It is orange in color, so it is easily seen during its application and its complete removal can be verified.
- It contains 25% aluminum chloride for optimal control of bleeding and gingival fluid.
- It can be used alone or in combination with a retraction cord, and can also be used alone for control of hemostasis.

Case Report no.1

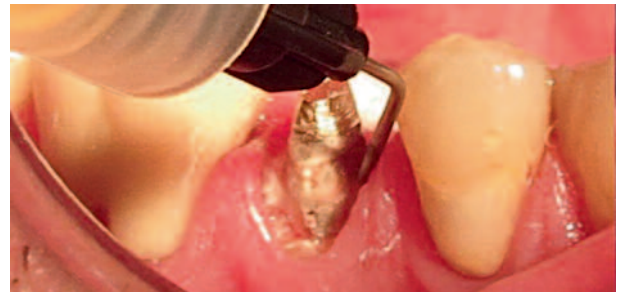Here we have a typical case of a lower second premolar, where the stump has just been cut to take an impression and create a ceramic crown. As is typical for this type of case, the cut was done taking the preparation shoulder margin slightly below the crest, within the gingival sulcus, but the space found in this sulcus is not the most suitable for placing a traditional retraction cord, since it would traumatize the gingival tissue; even finer cords would compromise the junctional epithelium,... especially in an example such as this case, where the gingival biotype is thin.



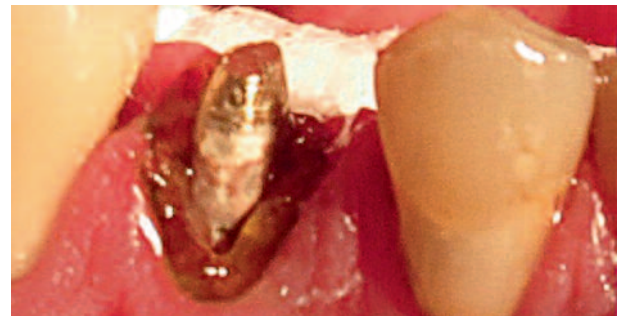
Here we can see that the use of a gingival retraction method is imperative to carry out the final impression of the stump.



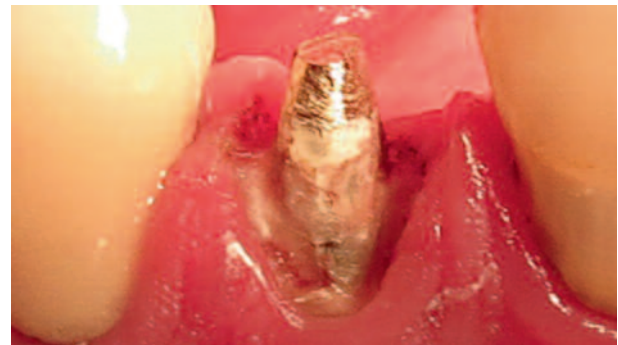Application of the retraction cord would involve a risk of altering the junctional epithelium.



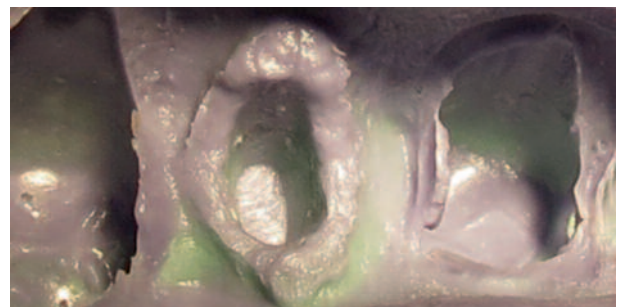
Racegel applicator tip provides superior control and accuracy when dispensing the product in the exact place.



Because of its color, Racegel contrasts sharply with the surrounding tissue.

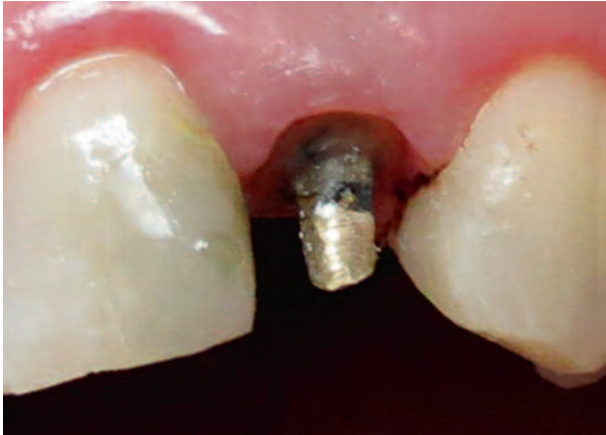

One to three minutes after the application of Racegel, it can be clearly seen how the shoulder margins are left cleanly and clearly exposed.

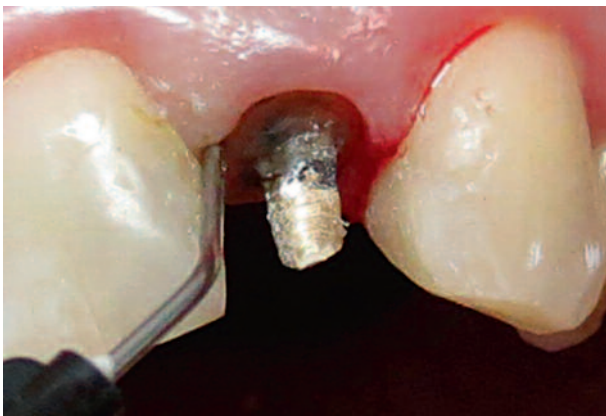


The resulting impression shows how Racegel fulfilled the task of properly exposing the preparation margins, affording an excellent working model for the laboratory.

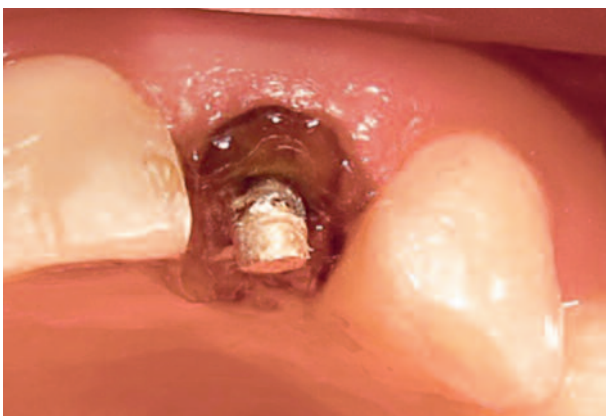Case Report no.2



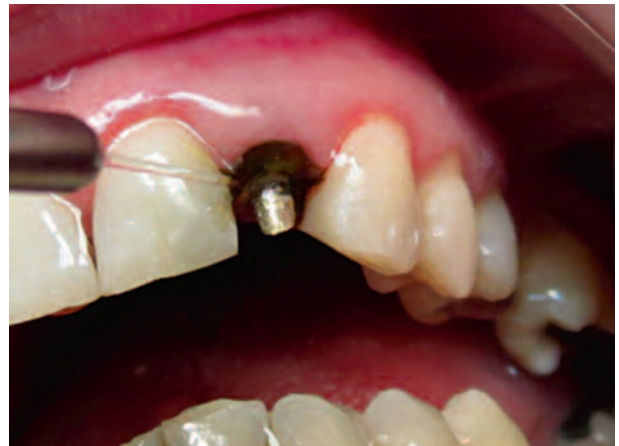In this case, the gingival biotype is medium, but it is imperative to effectively achieve a good retraction since the area is of very high functional and aesthetic compromise, where the stability of the gingival tissue and the need for a good impression are critical.




Beginning of syringe application.



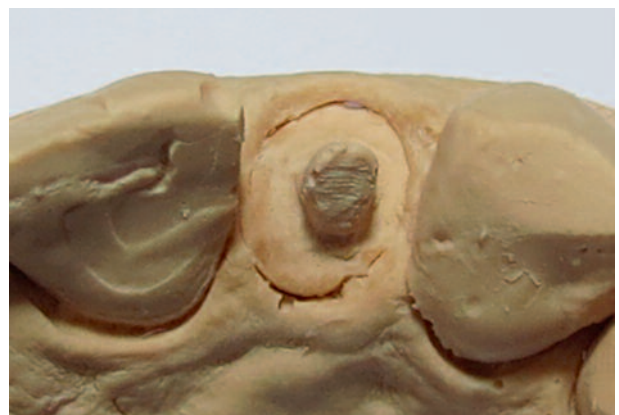Racegel works for 1 to 3 min.



It is removed with a water jet, taking advantage of the thermodynamic characteristic of Racegel.



The preparation margins can be clearly seen in



the impression
The margins can be clearly seen in the model.

Conclusion

In the effort to achieve excellence in the vast majority of clinical cases that are seen in the busy offices of current dental practice, there is no doubt that Racegel is one of the best options for gingival preparation, since it effectively brings

together retraction and hemostasis with speed and simplicity of application. However, each case should always be evaluated individually to find the best technique to perform.



Dr. Luis Fabián Brotos Duhart

Private Practice in Montevideo, Uruguay.

Volunteer Internship, Dental Surgery area, APEX Cerro in 1998.

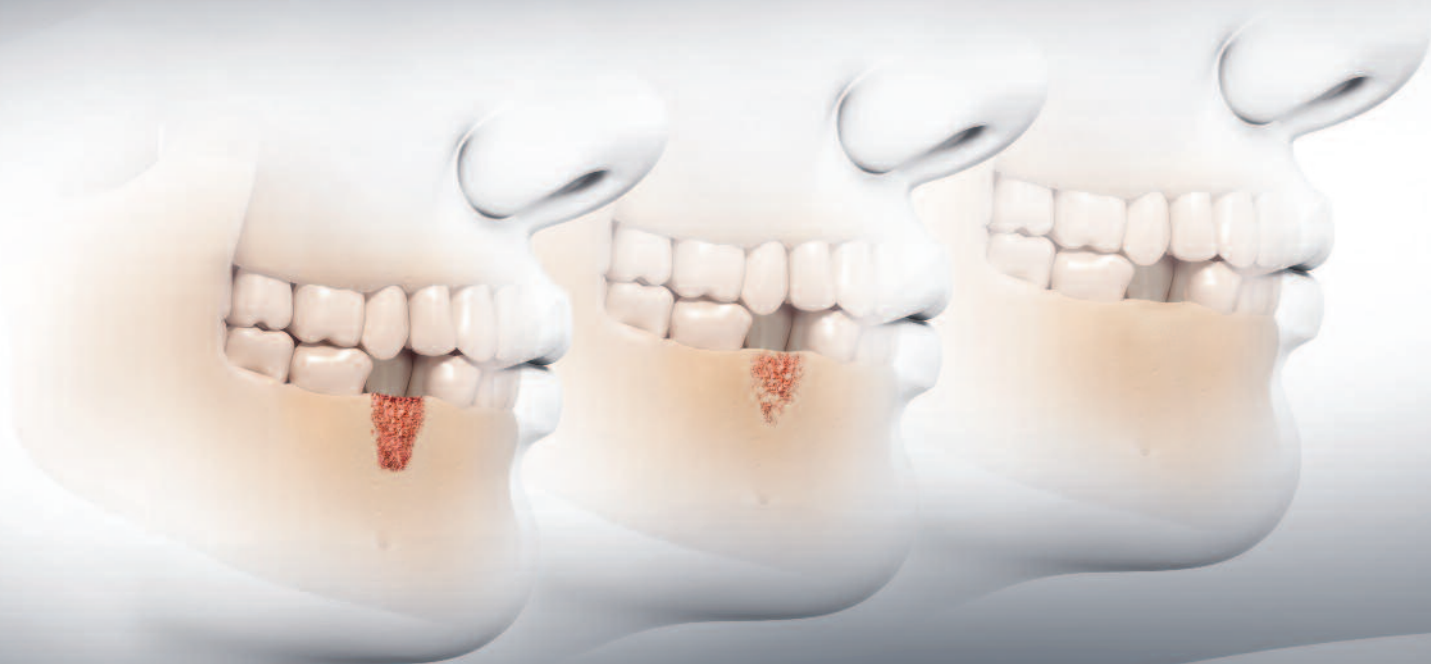Level II Professor of Occlusion and Prosthodontics Universidad de la República, Montevideo, Uruguay.

Clinic Assistant in Continuing Education Courses, Clínica Dr. Juan Carlos Ibañez, Córdoba, Argentina.

R.T.R.

Full resorption...

...Strong new bone formation



Cone



Syringe



Granules

R.T.R. (Resorbable Tissue Replacement) is a highly pure β -tricalcium phosphate bone grafting material that helps to safely create new bone formation following an extraction or any bone loss (intrabony defect, sinus-lift...).

- **Resorbs progressively and fully:** R.T.R. releases calcium and phosphate ions helping to promote strong new bone formation.
- **Regenerates natural bone growth.** Osteoconductive micro and macroporous structures foster dense new bone growth.
- **Restores volume:** R.T.R. renews the bone integrity within 3-6 months.
- **Available in 3 presentations** (Cone, Syringe, Granules) to suit all clinical situations.

Improve your patients' extraction therapy and bone loss repair to promote future implant success with R.T.R.

R.T.R. Cone contains collagen from bovine origin





The Dental Pharmaceutical Company

INNOVATIVE, SAFE AND EFFECTIVE SOLUTIONS FOR DENTISTRY WORLDWIDE