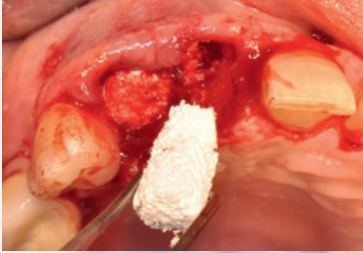

Septodont Case Studies Collection

No. 18 - june 2019

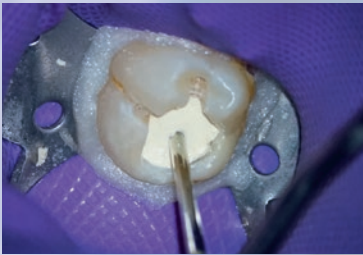
Alveolar ridge preservation with RTR

Dr Bozidar Brkovic



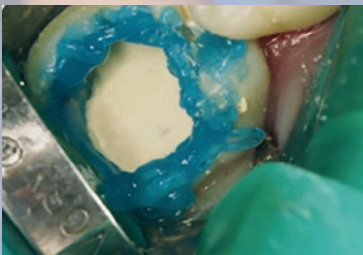Direct pulp capping with Biodentine™

Dr Jenner Argueta



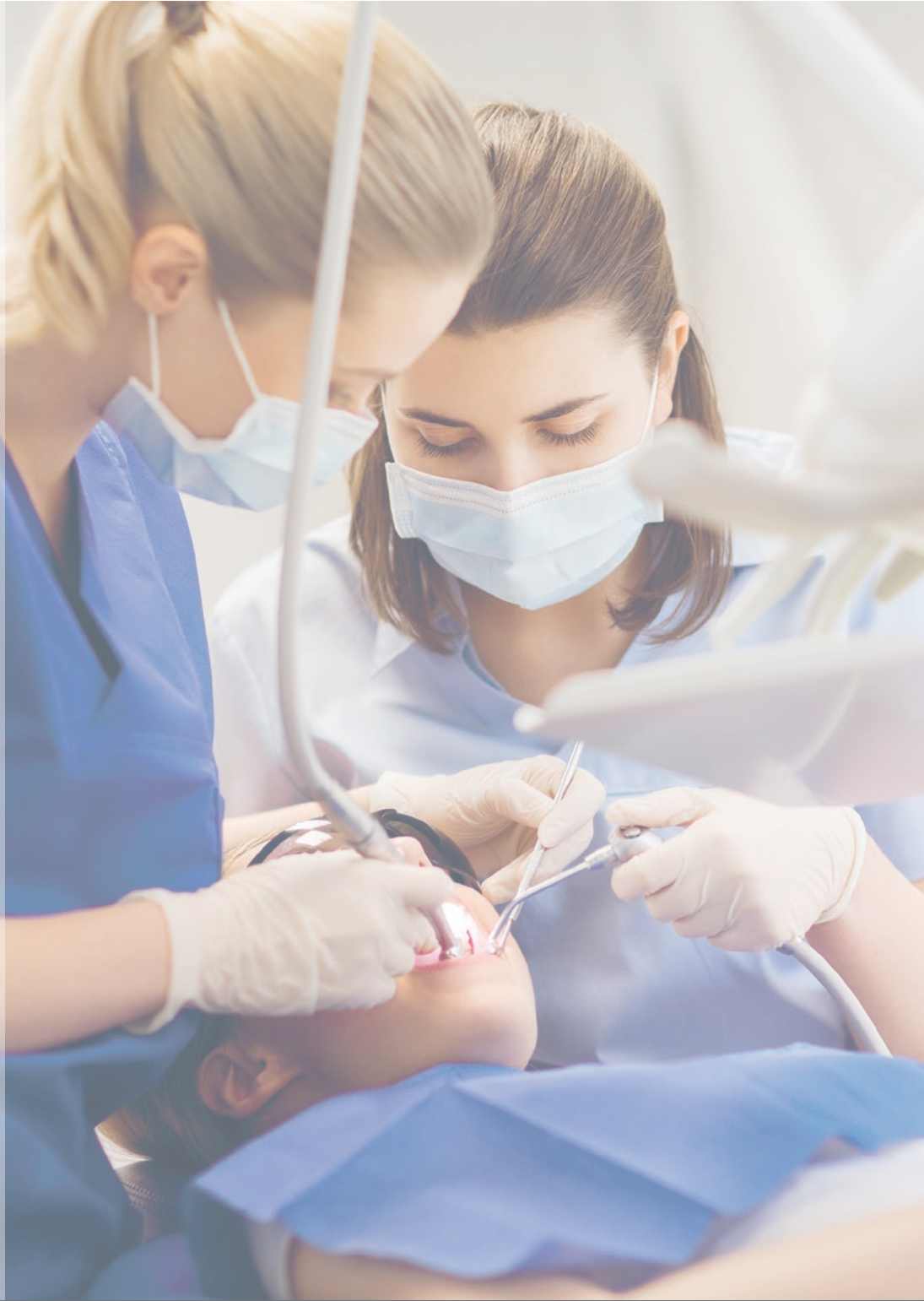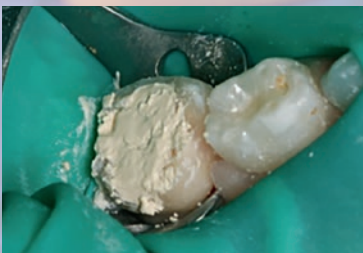
Direct pulp capping of immature teeth

Dr Gloria Saavedra

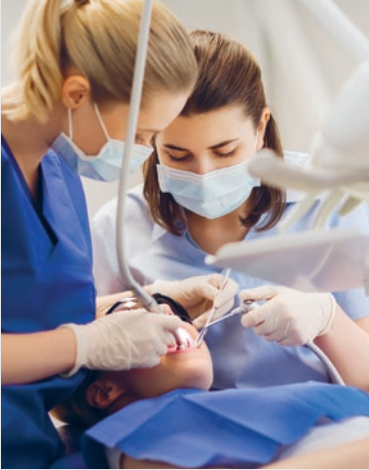

Pulpotomy in primary teeth

Dr Gloria Saavedra



Editorial



Since its foundation Septodont has developed, manufactured and distributed a wide range of high quality products for dental professionals.

Septodont recently innovated in the field of endodontics, dentine care, bone grafting and gingival preparation with the introduction of BioRoot™ RCS, Biodentine™, RTR and Racegel which are appreciated by clinicians around the globe.

Septodont created the “Septodont Case Studies Collection” - a series of case reports - in 2012 to share with you their experience and the benefits of using these innovations in daily practice.

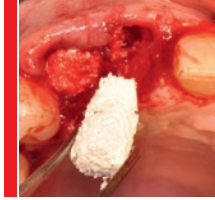
Over the past 6 years, authors from more than 15 countries have generously contributed to the success of our magazine that is now distributed on the 5 continents.

Each new issue of the Case Studies Collection is the opportunity to discover new clinical challenges and their treatment solutions.

This 18th issue features one RTR case and three Biodentine™ cases:

- RTR Bone grafting aims at preserving bone dimensions especially when tooth removal is discussed. It is fully resorbable & osteoconductive. Its remarkable properties promotes formation of patient’s new bone & paves the way for future successful treatment plans.
- Biodentine™, the first biocompatible and bioactive dentin replacement material. Biodentine™ uniqueness not only lies in its innovative bioactive and “pulp-protective” chemistry, but also in its universal application, both in the crown and in the root.

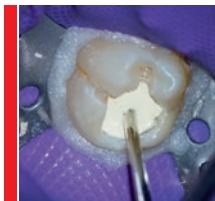Content



Alveolar ridge preservation with RTR

Dr Bozidar Brkovic

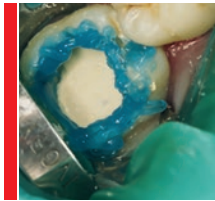04



Direct pulp capping with Biodentine™

Dr Jenner Argueta

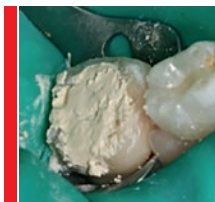10



Direct pulp capping of immature teeth

Dr Gloria Saavedra

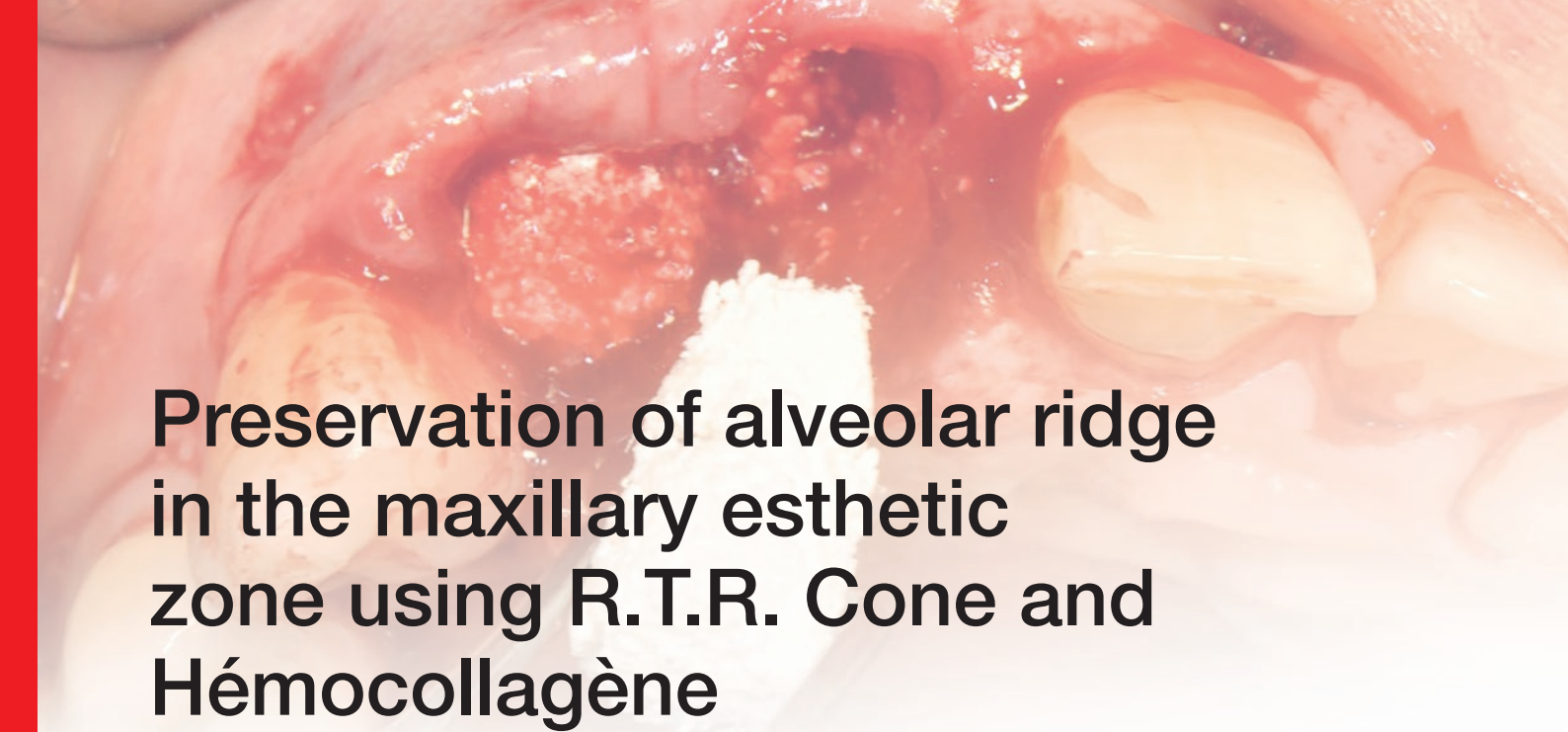
15



Pulpotomy in primary teeth

Dr Gloria Saavedra

19



Preservation of alveolar ridge in the maxillary esthetic zone using R.T.R. Cone and Hémocollagène

Author: Prof. Božidar Brkovic DDS, MSc, PhD
Professor of Oral Surgery, Implant Dentistry and Dental Anaesthesia, School of Dental Medicine, University of Belgrade, Serbia.

Introduction

Timing of placement implant in the esthetic zone is closely related to the reduction of risk of esthetic complications and obtaining the primary implant stability in the 3D implant position. Following tooth extraction implant can be placed immediately, then early, with soft tissue healing and partial bone consideration, or after completed bone healing and remodeling of alveolar ridge.

Although the late implant placement can obtain initial stability of implants and adequate structure and quality of residual bone, early implant placement is determined with increased level of cellular osteogenic activities inside the socket walls with a soft tissue healing that can provide the adequate volume and counter of soft tissue with enough keratinized gingiva of esthetic zone. On the other hand, timing of immediate implant placement is followed with strict indications depending of alveolar socket morphology and possibility of resulting in primary implant stability. However, all of timing protocols for implant placements are characterized by a greater or lesser extent of slight flattening to significant resorption of socket walls requiring contour augmentation

using bone substitutes (Buser et al. 2007, Chen, Buser 2008).

Beta tricalcium-phosphate (betaTCP) has a composition and structure very close to natural bone which ensure osteoconductive and biodegradable effect. BetaTCP can promote osteoblast differentiation and proliferation which is increase in a combination with the type I collagen because of a biocompatibility with variety of human cells and proteins in a process of bone healing (Ormianer et al. 2006, Yang et al. 2013). The bioactivity of betaTCP and type I collagen (R.T.R. Cone, Septodont, France) has been confirmed in previous clinical, in vitro and in vivo studies (Brkovic et al. 2008, 2012, Schwartz et al. 2007, Zou et al. 2005).

Preservation al alveolar ridge immediately after tooth extraction may provide reliable support to maintain the initial volume and morphology of bone and soft tissue in the esthetic zone (Vignoletti et al. 2012). This procedure is a less invasive procedure of augmentation of alveolar ridge which change a structural architecture of the regenerate bone inside the socket and

to minimize the absorption of external tissue. Therefore, the preservation of alveolar ridge volume is essential to achieving a successful and esthetically-driven implant prosthodontic rehabilitation in esthetic zone.

Since there is no data showing the effect of a composition of betaTCP and type I collagen (betaTCP/C1g) in the maxillary esthetic zone

used for the preservation of alveolar ridge immediately after tooth extraction and for stabilization of the alveolar soft tissue with collagen sponge of bovine origin at the same preservation sites, the aim of this report was to point out surgical steps, characteristic of method and positive results of bone and soft tissue regeneration.

Report of case (surgical steps and results)

A 45-year old healthy women was presented for implant placement in the maxillary esthetic zone at the position of #11, #12 with a periodontal disease (*Fig. 1*). Minimal invasive tooth extraction was done with subsequent curettage of granulation tissue and debridement of post-extraction sockets. After teeth extraction, exploration of post-extraction socket walls showed 4-walls defect of central incisor and 2-walls defect of lateral incisor with associated reduction of crestal bone walls as a result of periodontal disease (*Fig. 2*).

After minimal invasive extraction of teeth, debridement of socket walls was done regarding peri-radicular granulation tissue. Two blocks of R.T.R. Cone were trimmed to fit properly to socket walls using surgical knife or scissor (*Fig. 5*). Particles of trimmed cones were combining with solid form of cones were leave inside the sockets and in contact with mucoperiosteal tissue were periodontal disease destroyed socket wall bones (*Fig. 3*). R.T.R. Cone was positioned to the level of the most crestal marginal bone (*Fig. 4*). Regarding the absence of buccal bone wall and

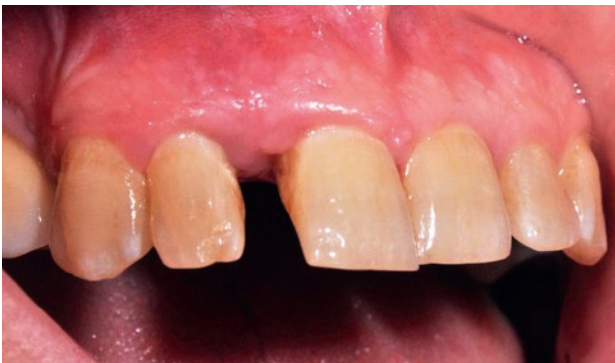

Fig. 1: Periodontal disease - indication for extraction

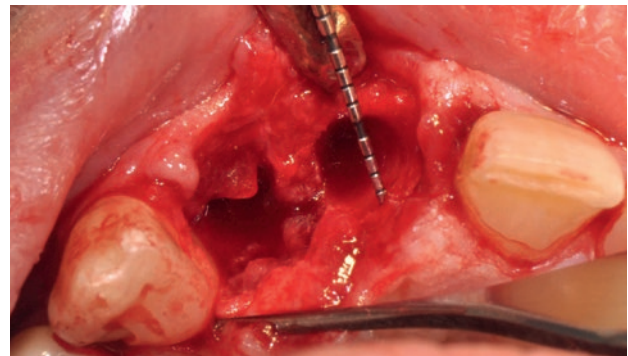


Fig. 2: Postextraction sockets with socket wall deficiency

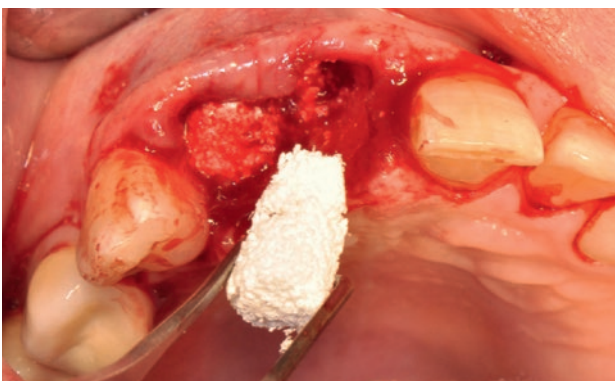

Fig. 3: R.T.R. Cone insertion for preservation of alveolar ridge in the maxillary esthetic zone

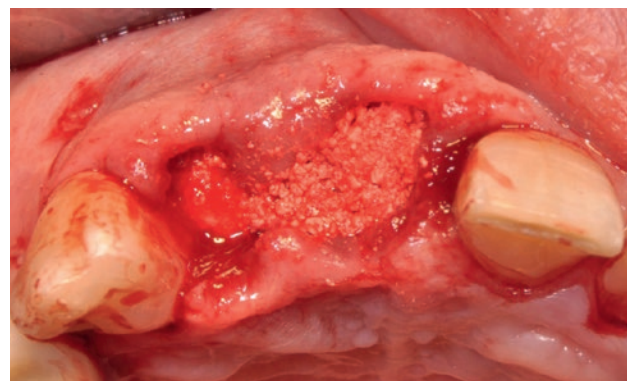


Fig. 4: R.T.R. Cone inside the socket walls



Fig. 5: Preparation of R.T.R. Cone and Hémocollagène

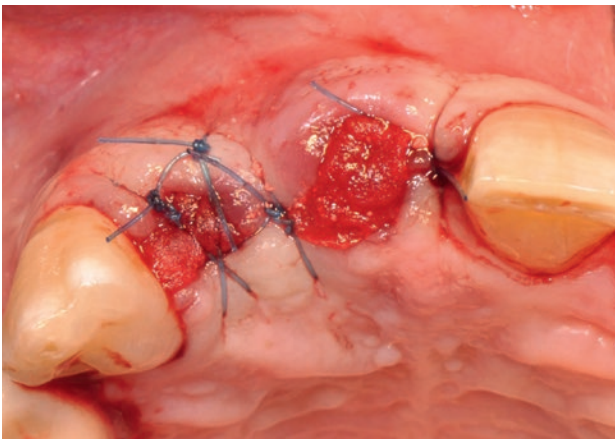


Fig. 6: R.T.R. Cone and Hémocollagène secured with sutures

reduction of crestal bone the filled sockets were covered with sponge collagen (Hémocollagène, Septodont, France) prepared for this indication. The collagen block was separated in two pieces with a sterile scissor and then modified by finger pressure to the form of one-layer membrane. One side of Hémocollagène membrane was positioned under the buccal while other side under the palatal attached gingiva which were previously elevated for surgical exploration of sockets. Material and gingiva were secured with interrupted sutures for 7 days leaving the central part which corresponds with socket opening, to healing spontaneously (*Fig. 6*). The process of epithelization of the external surface of Hémocollagène membrane was taken approximately 20 days of healing what was accepted tie for clinical intraoral socket healing. During that period no side effects were recorded. After 4 months of regeneration, the preserved site was open and explored for implant insertion (AstraTech TX Implant System) (*Fig. 7-11*).

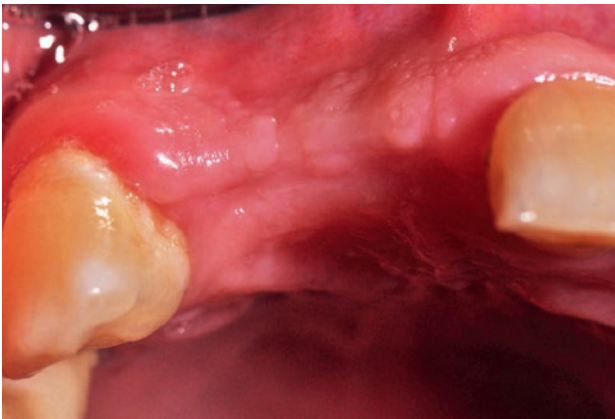

Fig. 7: Preservation of alveolar ridge after 4 months

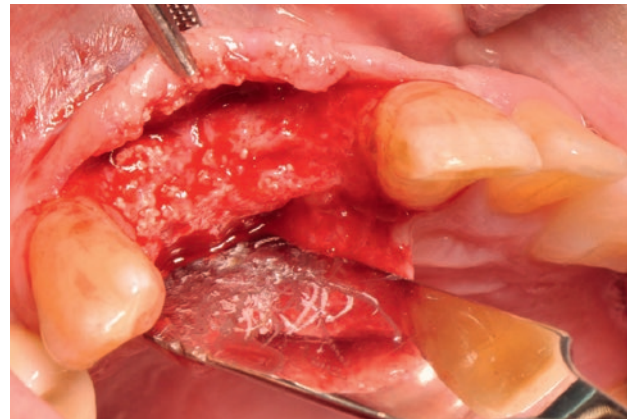


Fig. 8: Preserved surgical site before implant placement, 4 months of healing

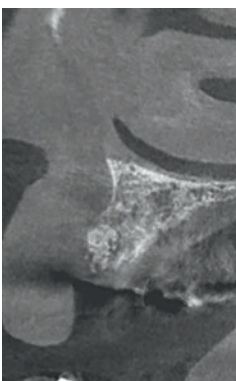


Fig. 9: CBCT view of 4 months healing

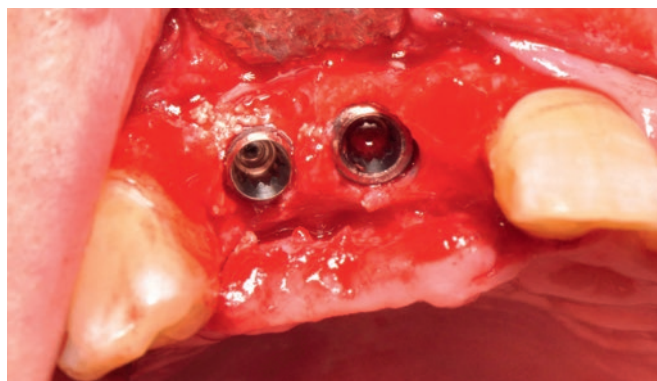


Fig. 10: Implants AstraTech TX placement in the preserved sockets

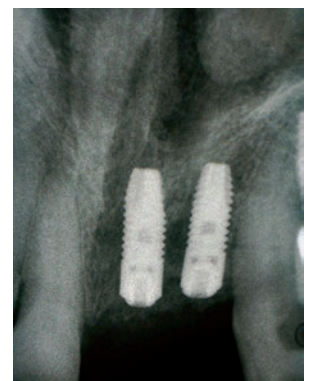

Fig. 11: Radiography of inserted implants

Discussion

The placement of implants in the anterior maxilla has been a major challenge to surgeon due to insufficient bone volume in the maxillary esthetic zone as a result of expected physiological bone remodeling.

Different studies have shown that the anterior maxillary sites after tooth extraction have a high risk for bone remodeling and consequent reduction due to thin and vulnerable buccal bone walls (Morjaria et al. 2014). It has been demonstrated that the most sites in the esthetic zone have a less than 1 mm of buccal bone wall thickness, while almost 50% of sites have a thickens less than 0.5 mm (Januario et al. 2011). Furthermore, sites in the esthetic zone undergo significant vertical reduction within 8 weeks of healing with a thickness of buccal bone wall less of 1 mm, as shown in the CBCT analysis (Chappuis et al. 2013). Another interesting outcome is documented in the retrospective study of Lee and Poon (2016) reported that a secondary augmentation in the esthetic zone was less after preservation of alveolar ridge, than after spontaneous post-extraction socket healing. These facts are of special concern especially when tooth extractions are related with periodontal disease where is objectively expected to have initial reduction of residual bone in both width and height. Most usually that condition is treated prior to horizontal and vertical augmentation including the principle of guided bone regeneration than with preservation method.

The use of betaTCP with collagen type I for preservation of alveolar ridge is now a standard method with promising results. It has been shown that healing of post-extraction sockets resulted in approximately 42% of new bone and marrow bone with 10% of residual graft,

during the healing period of 9 months (Brkovic et al. 2012). The chemical composition of betaTCP has an influence in the enhancement of mineralization due to a local increase in a concentration of Na and phosphate ions directly stimulated osteoblast activity (Zerbo et al 2005). Similar histomorphometric results of new bone formation were reported by Szabo et al. (2005) using betaTCP in patients undergoing sinus floor augmentation in period of 6 months of healing. In the same surgical model of sinus lift procedure, Perieira et al. (2017) recently reported similar amount of new bone formation after betaTCP alone or in combination with autogenous bone (approximately 45%) with positive immunostaining of bone samples demonstrated high cellular activity for both materials. Regarding the stability of grafted area, de O. Gorla et al (2015) have shown that betaTCP alone or in combination with autogenous bone presented satisfactory results for maxillary sinus lifting procedure regarding the maintenance of graft volume during the healing phase before the insertion of implants, as assessed by means of CBCT.

One of the important results which have to be underlined is the effects of collagen not only as a composite of betaTCP in R.T.R. Cone but also as a material for socket healing stabilization in a form of Hémocollagène sponge. Namely, the use of type I collagen, clinically may cover and, in direct contact with blood clot, bond the socket opening what will secure particles of material during early phase of healing. From the standpoint of biology, addition usage of type I collagen may decrease time for collagen development, stimulate precursor cells, increase osteoblast activity and increase of quality of regeneration (Zou et al 2005).



Authors:

Dr Božidar Brkovic (DMD, MSc, PhD) is Professor of Oral Surgery, Implant Dentistry and Dental Anesthesia employed at the School of Dental Medicine, University of Belgrade, Serbia since 1998. He completed his specialization program of oral surgery at the same university in 2004. From 2006 to 2007 he attended a Postdoctoral Fellow Program at Department of Oral and Maxillofacial Surgery, Faculty of Dentistry, University of Toronto, Canada, as well as a Scholar Program at Division of Oral and Maxillofacial Pathology, School of Dentistry, University of Minnesota, USA, focusing on implant dentistry and regenerative treatments of bone and soft tissue. In that field, Prof Brkovic was completed different research programs of molecular, cellular and tissue level of oral tissue regeneration in healthy and diabetic patients and animal models collaborated with University of Liege, Belgium, University of Tampere, Finland, Companies Dentsply Sirona, Straumann, Nobel Biocare. Special interest was obtained with Septodont Company, France, which included 2 Grants for bone regeneration treatments and local anesthesia in experimental and clinical cases. He published 32 original articles, several chapters, books and presented over 90 lectures. He is a mentor of 10 PhD thesis involved in several domestic and international scientific projects and an opinion leader for clinical courses and education for Septodont and AstraTech Implant System. Prof Brkovic has been an ITI Fellow since 2008. He is currently professor of integrated and postgraduate programs of oral surgery, implantology and dental anesthesia at the University of Belgrade.

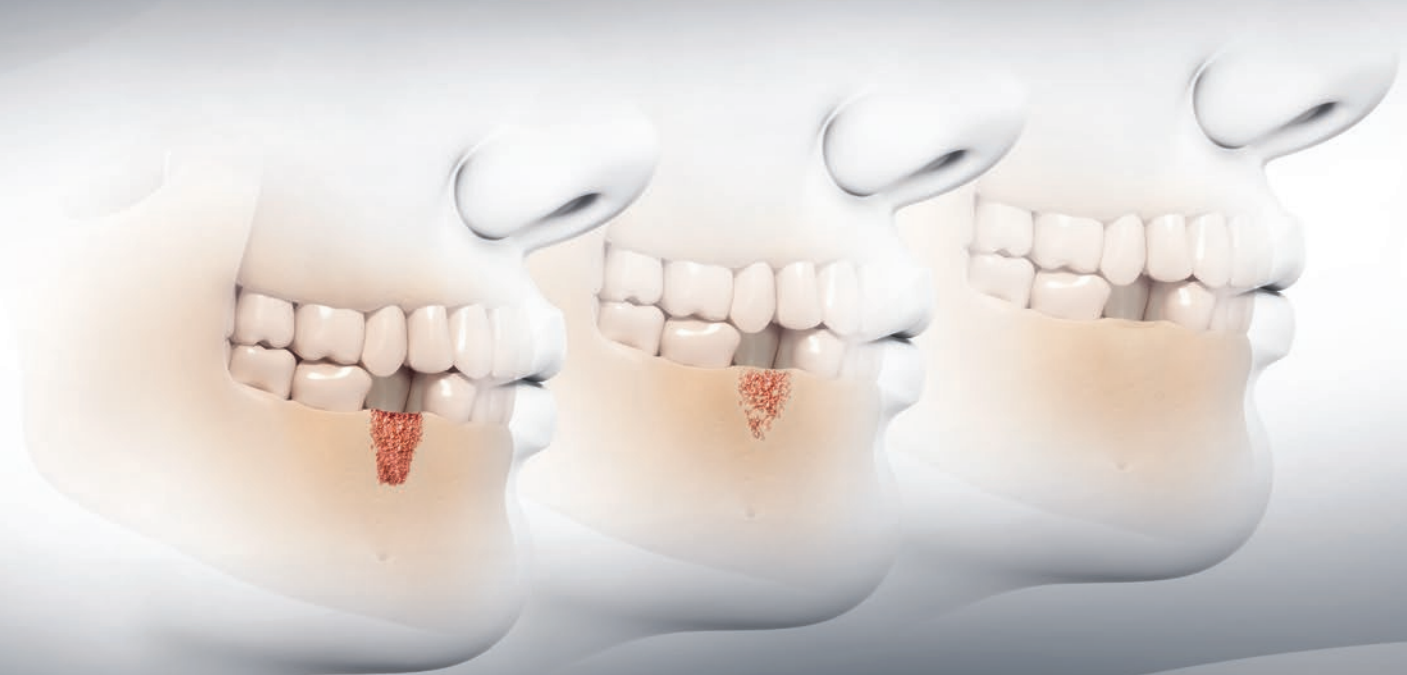References


1. Brkovic B, Prasad, H, Rohrer M, Konandreas G, Agrogianis G, Antunovic D, Sandor G. Beta-tricalcium phosphate/type I collagen cones with or without a barrier membrane in human extraction socket healing: clinical, histologic, histomorphometric, and immunohistochemical evaluation. *Clin Oral Invest* 2012;16:581-590.
2. Brkovic B, Prasad, H, , Konandreas G, Radulovic M, Antunovic D, Sandor G, Rohrer M. Simple preservation of a maxillary extraction socket using beta-tricalcium phosphate with type I collagen: preliminary clinical and histomorphometric observation. *JCDA* 2008;16:581-590.
3. Buser D, Belser U, Wismeier D. Implant therapy in the esthetic zone – single tooth replacement. Berlin, London. Quintessence, 2007.
4. Chappuis V, Engel O, Reyes M, Shahim K, Nolte LP, Buser D. Ridge alterations post-extraction in the esthetic zone: a 3D analysis with CBCT. *J Dent Res* 2013;92:195S-201S.
5. Chen S, Buser D. Implant placement in the post-extraction sites – treatment options. Berlin, London. Quintessence, 2008.
6. Januario AL, Duarte WR, Barriviera M. Dimension of the facial bone wall in the anterior maxilla: a cone-beam computed tomography study. *Clin Oral Impl Res* 2011;22:1168-71.
7. Lee AMH, Poon CY. The clinical effectiveness of alveolar ridge preservation in the maxillary anterior esthetic zone - a retrospective study. *J Esthetic Restorative Dent* 2017;29:137-145.
8. Morjaria K, Wilson R, Palmer R. Bone healing after tooth extraction with or without an intervention: a systemic review of randomized controlled trials. *Clin Implant Dent Related Res* 2014;16:1-20.
9. Ormianer Z, Palti A, Shifman A. Survival of immediately loaded dental implants in deficient alveolar bone sites augmented with beta-tricalcium phosphate. *Implant Dent* 2006;15:396-401.

10. Schwarz F, Herten M, Ferrari D, Wieland M, Schmitz L, Engelhardt E, Becker J. Guided bone regeneration at dehiscence-type defects using biphasic hydroxyapatite + beta tricalcium phosphate (Bone Ceramic) or a collagen-coated natural bone mineral (BioOss Collagen): an immunohistochemical study in dogs. *Int J Oral Maxillofac Surg* 2007;36:1198-206.
11. Szabo G, Huys L, Coulthard P, Maiorana C, Garagiola U, Barabas J et al. A prospective multicenter randomized clinical trial of autogenous bone versus beta-tricalcium phosphate graft alone for bilateral sinus elevation: histologic and histomorphometric evaluation. *Int J oral Maxillofac Implants* 2005;20:37-381.
12. Zerbo IR, Bronckers AL, de Lange G, Burger E. Localization of osteogenic cells and osteoplastic cells in porous beta-tricalcium phosphate particles used for human maxillary sinus floor elevation. *Biomaterials* 2005;26:1445-1451.
13. Zou C, Weng W, Deng X, Cheng K, Liu X, Du P et al. Preparation and characterization of porous beta-tricalcium phosphate/collagen composites with an integrated structure. *Biomaterials* 2005;26:5276-5284.
14. Vignoletti F, Matesanz P, Rodrigo D, Figuero E, Martin C, Sanz M. Surgical protocols for ridge preservation after tooth extraction. A systematic review. *Clin Oral Implants Res* 2012;23 Suppl 5:22-38.
15. Yang C, Unursaikhan O, Lee J, Jung U, Kim C, Choi S. Osteoconductivity and biodegradation of synthetic bone substitutes with different tricalcium phosphate contents in rabbits. *J Biomed Mat Res* 2013;6:1-9.

R.T.R.

A complete solution
for your bone needs





Biodentine™ as direct pulp capping material in teeth with mature apices.

Authors: Jenner Argueta D.D.S. M.Sc. -- Melisa Valenzuela, Br.

Introduction

Awareness of the importance of preserving the vitality of the pulpo-dentinal complex has resulted in conservative management of pulpal pathologies becoming more and more popular over time; this is due in part to current advances in regard to protocols and appropriate materials for vital pulp therapy procedures, and the economic factors that influence decision-making in many countries and lead many patients to opt for premature tooth extraction because of the costs involved in root canal treatment and subsequent restoration (1, 2).

Pulp tissue may become exposed to the oral environment, whether due to dental caries, or mechanically as a result of restorative or prosthetic procedures. One treatment option for pulp exposure is the application of conservative vital pulp therapy procedures, which may include direct pulp capping, indirect pulp capping if the tissue is not fully exposed, and partial or total pulpotomy; this permits the preservation of the vitality of the tooth, its

nociceptive functions, and the defense system of the body itself. Thanks to the abovementioned items, among others, it has been shown that longer survival time is achieved in teeth without root canal treatment when compared with endodontically treated teeth (1, 3-5).

Included amongst the materials used to perform pulp therapy procedures are bio-ceramic cements; these biocompatible materials are divided into three basic groups: 1. High strength bio-inert cements; 2. Bioactive cements, which form chemical bonds with mineralized tissue; and 3. Biodegradable materials that participate actively in the body's metabolic processes (6). Multiple bioceramic materials are currently available on the market; the most well known of these materials are MTA and Biodentine™, both of which belong to the bioactive cements group. Biodentine™ is a dentin substitute and dentinogenesis promoter with the following properties: alkaline pH, biocompatibility, antibacterial action, release

of calcium and hydroxyl ions, radiodensity similar to dentin, setting time of approximately 12 minutes, insolubility, outstanding sealing properties, and causes no tooth discoloration (7-11); this last property makes it the material of choice when treatments need to be performed involving the coronal and cervical areas whether of anterior or posterior teeth.

At the dental undergraduate clinics of the Faculty of Dentistry of the Mariano Gálvez University of Guatemala and at the Argueta-Orellana private dental clinic, 20 direct pulp-capping procedures were performed on teeth with mature apices clinically diagnosed with reversible pulpitis and with no history of spontaneous pain; all pulp exposures were performed mechanically via the removal of caries (*Fig. 1*) in patients between 16 and 45 years of age. All procedures were performed by the same operator (an endodontist with over eight years' clinical experience), following the same protocol in each case. Clinical and radiographic examinations were performed on each of the patients at 3, 6 and 12 months post-treatment; after 12 months' monitoring, a high percentage of the cases presented radiographic evidence of dentin bridge formation (*Fig. 2*). Below we present a clinical case intended to show the pulp-capping protocol applied for all patients.

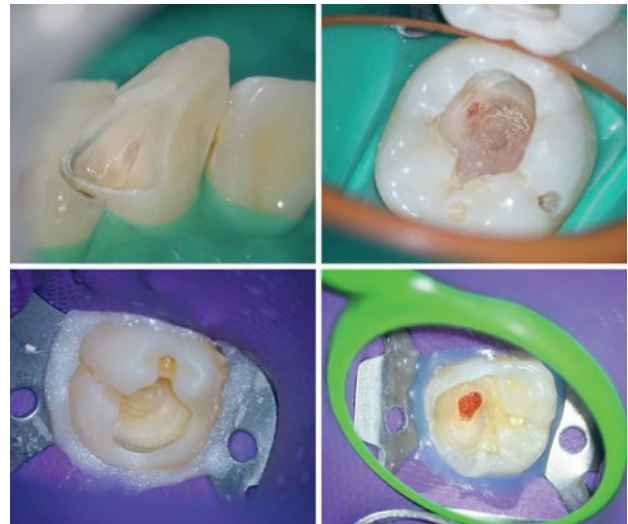

Fig. 1

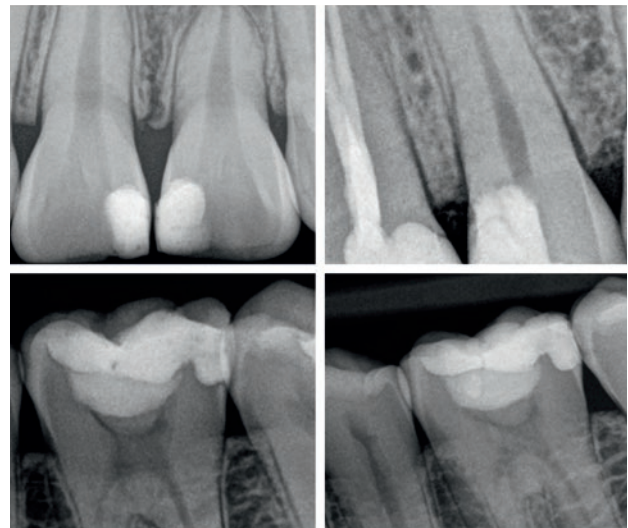


Fig. 2

Clinical case

Patient, 22 years of age, visits the dental clinic presenting short-duration elicited pain in tooth no. 19 (*Fig. 3 and 4*); having established a diagnosis of reversible pulpitis, we proceeded to caries removal under absolute isolation (*Fig. 5*) producing a slight pulpal exposure with no hemorrhaging; this type of exposure may go unnoticed if a correct assessment of the preparation floor is not performed with an endodontic explorer (*Fig. 6*). In the cases where hemorrhage did occur, it was stopped by the application of sustained pressure for 10 seconds with a cotton swab moistened with sterile saline solution; in this particular case

this step did not need to be performed, so the cavity was disinfected with sodium hypochlorite 2.5%, and Biodentine™ was placed to serve as a direct pulp-capping material (*Fig. 7*) using the "MAP System" dental materials micro-aplicator. Approximately 75% of the cavity was filled with Biodentine™ (*Fig. 8*); Cavit-G was then placed over this to serve as a provisional restorative material, and seven days after the procedure the patient was evaluated to confirm that he was completely asymptomatic and that the tooth was responding normally to sensitivity tests so that we could proceed to final restoration (*Fig. 9 and 10*).

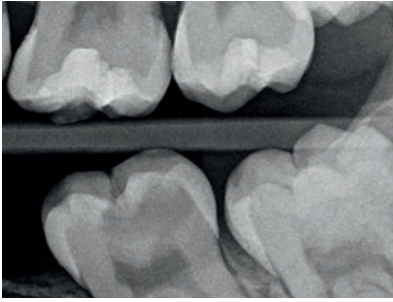


Fig. 3

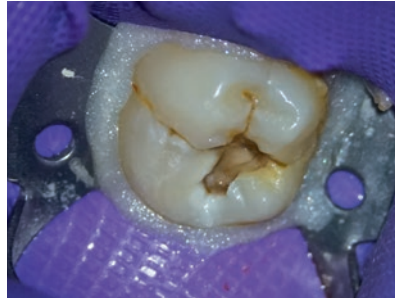

Fig. 4

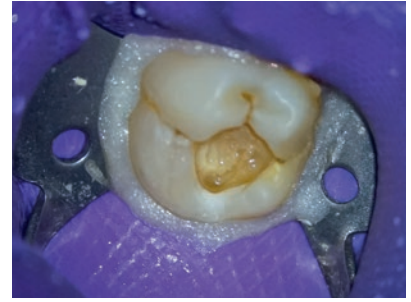


Fig. 5

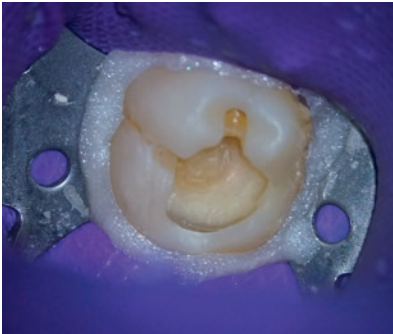


Fig. 6

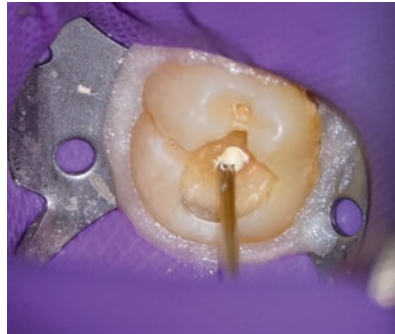


Fig. 7

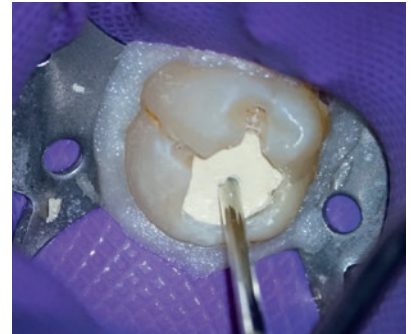


Fig. 8

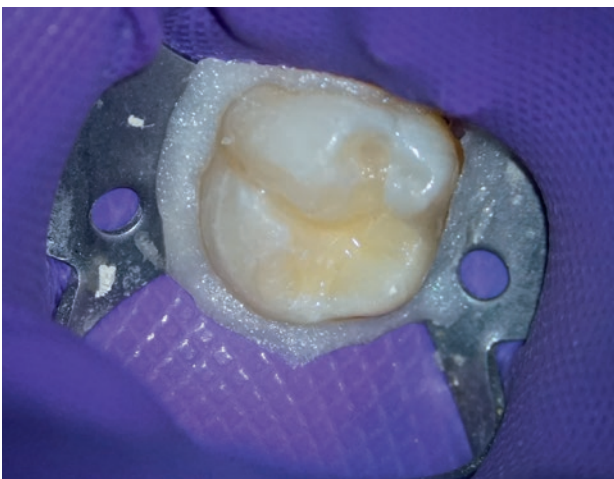


Fig. 9

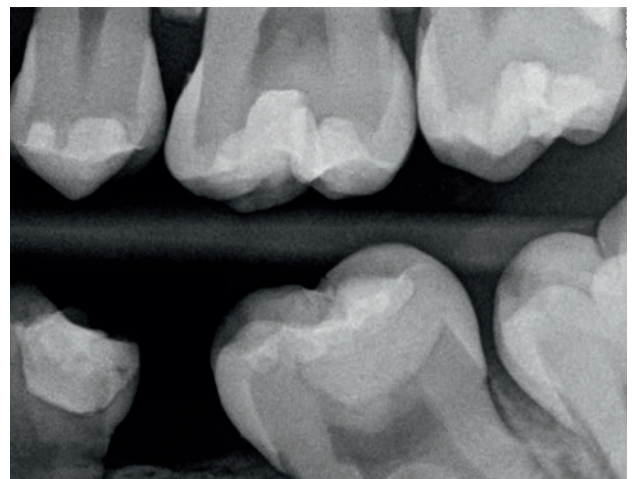


Fig. 10

Follow-up

All patients were re-evaluated at 3, 6 and 12 months after their pulp-capping appointment. In clinical situations such as this, we hope to see radiographic evidence of mineralized tissue formation under the cap between six and nine months post-procedure (12).

All 20 cases were re-examined at 12 months of follow-up, and in all cases the response to

the sensitivity tests was normal; all teeth went on to final restoration in acceptable conditions, and in 14 of the 20 cases (70%) it was possible to clearly observe radiographic evidence of mineralized tissue formation under the pulp capping material; a supplementary examination is planned at 24 months post-procedure for all these cases.

Discussion

From an entirely optimistic perspective, the ultimate goal of any dentist when performing restorative and/or endodontic procedures should be the maintenance of the pulp vitality and functionality of the tooth, with no discomfort for the patient (13).

Obtaining an adequate diagnosis is key to the success of conservative pulpal therapy; an ideal case is one where we have a diagnosis of reversible pulpitis with no history of spontaneous or long-lasting dental pain(14), as it is generally accepted that a history of spontaneous or nocturnal pain is associated with the presence of an irreversible pulp inflammation process(15, 16). In these cases, the success of direct pulp capping may be questionable (17), although some studies have shown that even in

these types of situations vital pulp therapy may achieve a successful outcome (1, 18-20).

In regard to the long-term success of conservative pulp procedures, it is extremely important that the tooth be provided with a definitive final restoration that guarantees an adequate marginal seal, since this last factor, in conjunction with the absence of bacterial contamination during the procedure, is among the most important factors to be taken into consideration in view of preventing subsequent pulp inflammation (21, 22). The reported success rate for vital pulp therapy procedures using bioactive cements is greater than 80% in examinations at up to 10 years (23); this is a very high percentage for a dental procedure in such operational time frames.

Conclusion

Based on the clinical results obtained in the present series of cases and taking into consideration the limitations inherent in the study, we can conclude that direct pulp capping

with Biodentine™ teeth presenting reversible pulpitis is highly effective for the maintenance of pulp vitality.



Authors:

Jenner Argueta, D.D.S. – M.Sc.

Master of Endodontics

Associate Professor of Endodontics Mariano Gálvez University of Guatemala

President Guatemalan Endodontics Academy



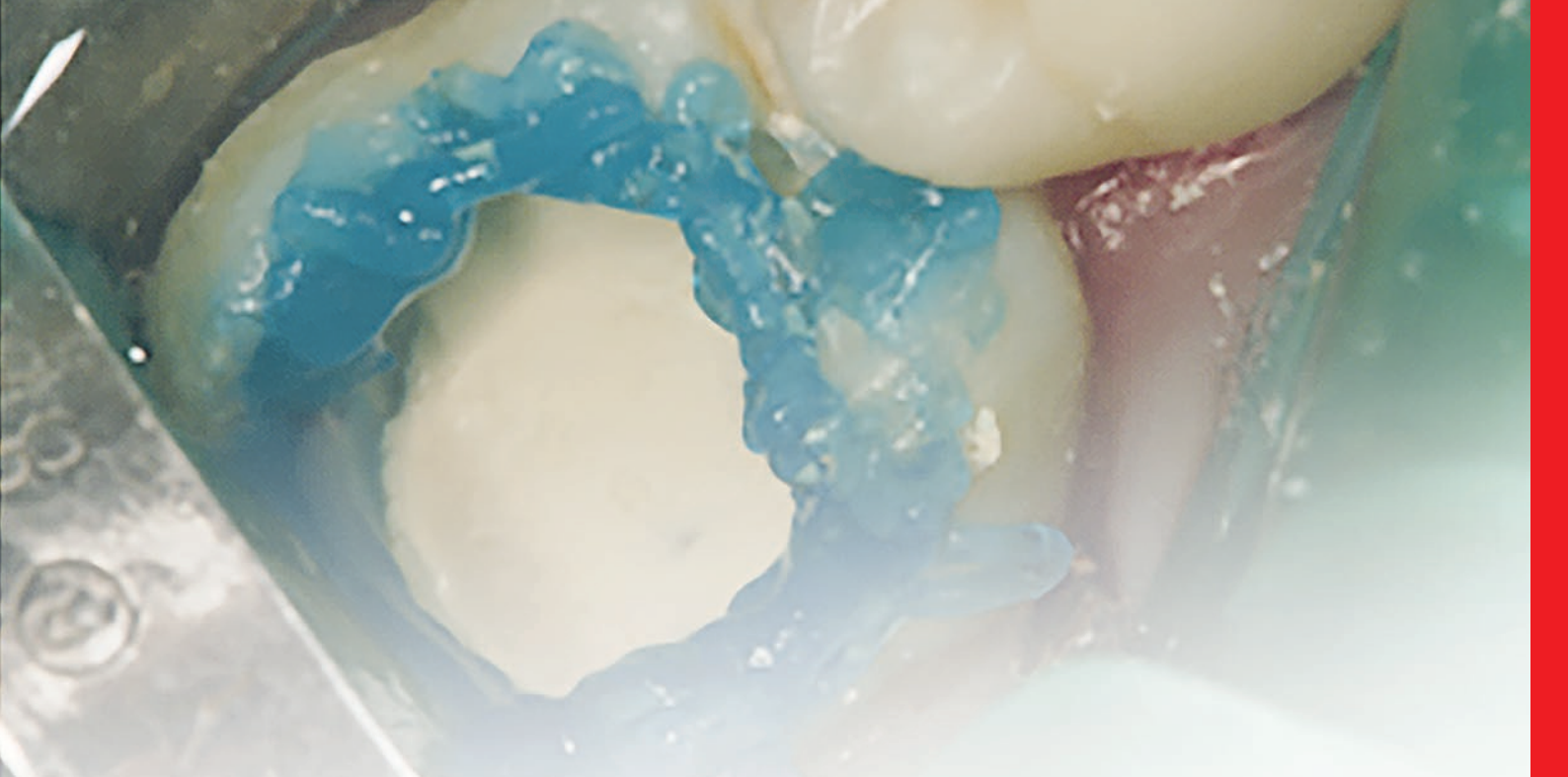
Melisa Valenzuela, Br

Dentistry Student

Mariano Gálvez University of Guatemala

References

1. Asgary S, Eghbal MJ, Fazlyab M, Baghban AA, Ghoddusi J. Five-year results of vital pulp therapy in permanent molars with irreversible pulpitis: a non-inferiority multicenter randomized clinical trial. *Clin Oral Investig* 2015;19(2):335-341.
2. Asgary S, Eghbal MJ. Treatment outcomes of pulpotomy in permanent molars with irreversible pulpitis using biomaterials: a multi-center randomized controlled trial. *Acta Odontol Scand* 2013;71(1):130-136.
3. Aguilar P, Linsuwuanont P. Vital pulp therapy in vital permanent teeth with cariously exposed pulp: A systematic review. *Journal of Endodontics* 2012;37(5).
4. Asgary S, Eghbal MJ, Ghoddusi J, Yazdani S. One-year results of vital pulp therapy in permanent molars with irreversible pulpitis: an ongoing multicenter, randomized, non-inferiority clinical trial. *Clin Oral Investig* 2013;17(2):431-439.
5. McDougal RA, Delano EO, Caplan D, Sigurdsson A, Trope M. Success of an alternative for interim management of irreversible pulpitis. *Journal of the American Dental Association* (1939) 2004;135(12):1707-1712.
6. Koch K, Brave D. EndoSequence: melding endodontics with restorative dentistry, part 3. *Dentistry today* 2009;28(3).
7. Bakhtiar H, Hossein M, Aminishakib P, Abedi F. Human Pulp Responses to Partial Pulpotomy Treatment with TheraCal as Compared with Biodentine and ProRoot MTA: A Clinical Trial. *Journal of Endodontics* 2017;Article In Press.
8. Malkondu O, Karapinar Kazandag M, Kazazoglu E. A review on biodentine, a contemporary dentine replacement and repair material. *Biomed Res Int* 2014;2014:160951.
9. Miller AA, Takimoto K, Wealleans J, Diogenes A. Effect of 3 Bioceramic Materials on Stem Cells of the Apical Papilla Proliferation and Differentiation Using a Dentin Disk Model. *J Endod* 2018.
10. Nowicka A, Lipski M, Parafiniuk M. response of human dental pulp capped with biodentine and mineral trioxide aggregate. *Journal of Endodontics* 2013;39(6).
11. Villat C, Grosogogeat B, Seux D, Farge P. Conservative approach of a symptomatic carious immature permanent tooth using a tricalcium silicate cement (Biodentine): a case report. *Restor Dent Endod* 2013;38(4):258-262.
12. Maroto M, Barberia E, Planells P, Garcia Godoy F. Dentin bridge formation after mineral trioxide aggregate (MTA) pulpotomies in primary teeth. *American journal of dentistry* 2005;18(3):151-154.
13. Zanini M, Meyer E, Simon S. Pulp Inflammation Diagnosis from Clinical to Inflammatory Mediators: A systematic review. *J Endod* 2017.
14. Camp J. Diagnosis dilemmas in vital pulp therapy: treatment for the toothache is changing, especially in young, immature teeth. *Journal of Endodontics* 2008;34(7S):S6.
15. Endodontics aAo. Endodontic Diagnosis Colleagues for Excellence 2013(Fall 2013).
16. Mejare IA, Axelsson S, Davidson T, Frisk F, Hakeberg M, Kvist T, et al. Diagnosis of the condition of the dental pulp: a systematic review. *International endodontic journal* 2012;45(7):597-613.
17. Barrieshi-Nusair KM, Qudeimat MA. A prospective clinical study of mineral trioxide aggregate for partial pulpotomy in cariously exposed permanent teeth. *J Endod* 2006;32(8):731-735.
18. Matsuo T, Nakanishi T, Shimizu H, Ebisu S. A clinical study of direct pulp capping applied to carious-exposed pulps. *J Endod* 1996;22(10):551-556.
19. Mejare I, Cvek M. Partial pulpotomy in young permanent teeth with deep carious lesions. *Endodontics & dental traumatology* 1993;9(6):238-242.
20. Caliskan MK. Pulpotomy of carious vital teeth with periapical involvement. *International endodontic journal* 1995;28(3):172-176.
21. Swift EJ, Trope M, Ritter AV. Vital pulp therapy for the mature tooth – can it work? *Endodontic Topics* 2003(5).
22. Rechenberg DK, Zehnder M. Molecular diagnostics in endodontics. *Endodontic Topics* 2014;30(1):51-65.
23. Johannes Mente et al. Treatment outcome of mineral trioxide aggregate or calcium hydroxide direct pulp capping: long-term results. *Journal of endodontics* 2014;40(11).



Direct pulp capping in immature permanent teeth

Authors: Dr. Gloria Saavedra-Marbán, Dr. Eugenio C. Grano de Oro-Cordero, Dr. Cristina González Aranda

Introduction

Direct pulp capping (DPC) is a procedure that is usually performed on children or young persons with permanent teeth that have open apices and are showing dental lesions close to the pulp tissue. This loss of dental structure can be caused by deep caries, trauma or mineralization defects in the tooth structure.

In these cases, the patient may notice some degree of discomfort to stimuli (primarily the cold or sugary foods), although not showing any signs of spontaneous sensitivity. X-rays usually show lesions close to the pulp without indications of pulpal degeneration, so there is likely to be pulpal exposure if the decayed tissue is completely removed during the operation.

The purpose of direct pulp capping is to stimulate reparative dentin formation which maintains the vitality of the pulp and, as a result, allowing the apex to continue developing. This is achieved by removing any microorganisms

present and ensuring the lesion is properly sealed using a material that is well-tolerated by the dental pulp.

Throughout history, different materials and techniques have been used for direct pulp capping in immature permanent teeth.

Traditionally, calcium hydroxide has been used as a material for pulp capping, due to its effective antibacterial properties. However, there are some long-term disadvantages due to its high solubility and inability to adhere to dentin. Subsequently, etching techniques have been used on the pulp for dentin bonding and sealing it with a permanent filling material, but several studies have shown poor biocompatibility of these resin-based materials with the pulp. (1,2)

The arrival of new bioactive materials has led to an increased success in direct pulp capping. Among them, MTA® and Biodentine™ are well-

known options. MTA has been used since 2000 due to its biocompatibility with the pulp and its insolubility, with numerous studies showing higher percentages of long-term success when using this material than when calcium hydroxide was used. (3)

Biodentine™ was introduced in 2010 and has very similar physical and biological properties to dentin, as it is a biocompatible and bioactive material that induces pulp repair. It has simpler handling properties to MTA, such as a shorter

setting time (12 minutes), and it does not cause dental discoloration because it does not contain bismuth oxide. (4-6)

Currently, there are numerous clinical studies on the effectiveness of Biodentine as a direct pulp-capping material. (7-11)

In our clinical practice, the direct pulp capping procedure consisted of caries removal up to the pulpal chamber, filling in the cavity with Biodentine™ and sealing it with, in our case, a composite resin.

Clinical case report

An 8-year-3-month-old patient visits our surgery for the first time. The clinical examination showed a deep caries lesion in molar 3.6. with clinical signs of reversible pulpitis.

The periapical X-ray confirms the proximity of the lesion to the pulp and the teeth with open apices. The proposed treatment plan was to remove the caries (with a high risk of pulpal exposure) and to protect the remaining healthy pulp for the apical closure to progress naturally. The clinical procedure was as follows:

1. Clinical and X-ray diagnosis. (Fig 1)
2. Local anesthesia is administered, and the tooth is isolated with a rubber dam.
3. The caries lesion is initially cleaned using a high-speed rotary instrument (Komet® 0.10 mm round diamond bur) and then complete caries removal is performed using a slow-speed rotary instrument (Komet® 0.10 mm round tungsten-carbide bur). (Fig. 2)
4. The cavity and the area where the pulp is exposed are cleaned for one minute using a cotton ball moistened with 5% sodium hypochlorite, checking there is no bleeding where the pulp tissue is exposed. (Fig. 3)
5. Biodentine™ is applied to the cavity close to

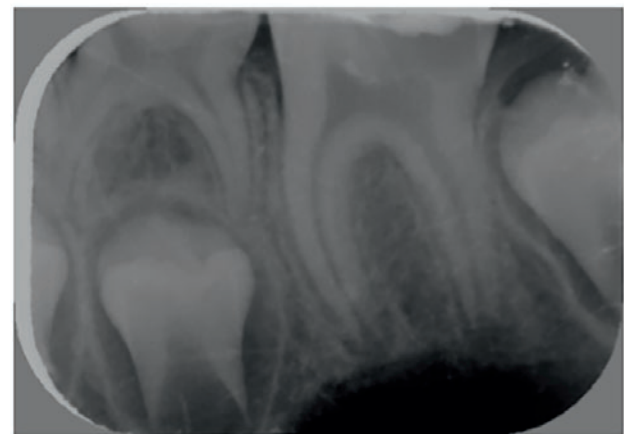


Fig. 1: Pre-operative X-ray showing the radiolucent image indicating caries near the pulp in tooth 3.6 with open apices.

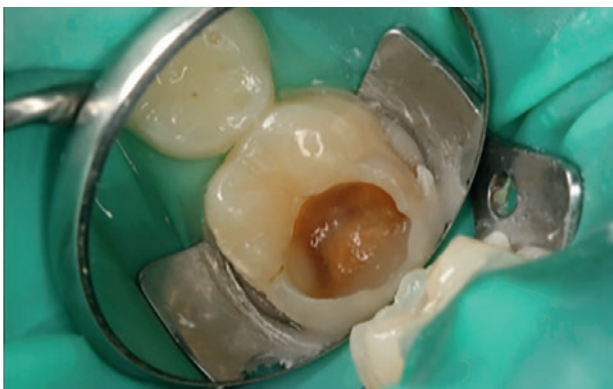

Fig. 2: Clinical view after the caries removal.

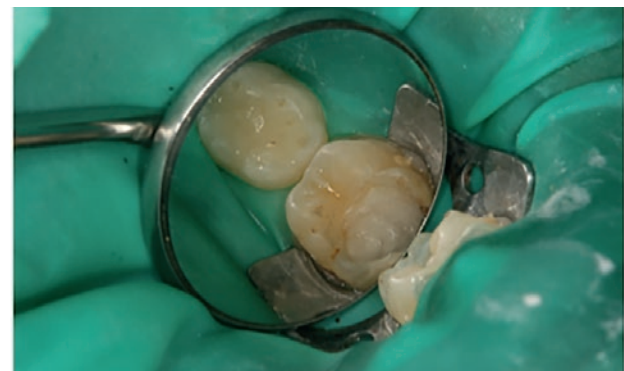

Fig. 3: The cavity and exposed pulpal cavity is disinfected using a cotton ball with 5% sodium hypochlorite.

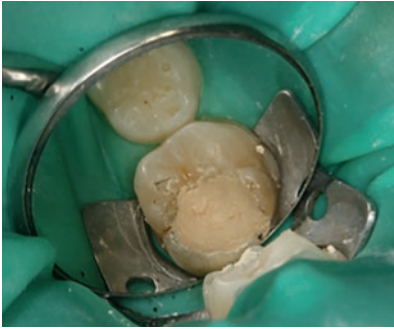

Fig. 4: Appearance after the application of Biodentine™.

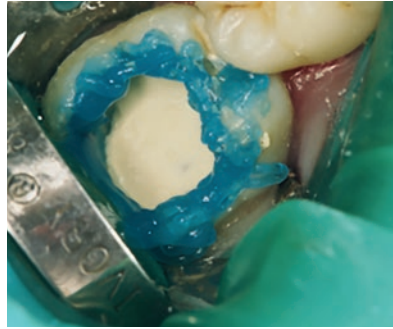

Fig. 5: 37% orthophosphoric acid applied to the enamel.

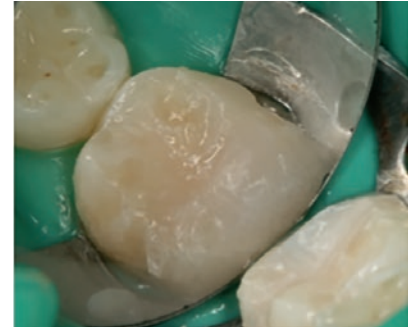

Fig. 6: Cavity filled with a hybrid resin composite.

the pulpal exposure using a plastic instrument according to the manufacturer's instructions. (*Fig. 4*)

6. 12 minutes after mixing the Biodentine™, following the manufacturer's instructions, the etch-and-rinse procedure is carried out using an enamel etchant (Scotchbond™ Etchant 3M™ ESPE™) which is then washed and dried, before an adhesive (Scotchbond™ Universal) is applied, then cured and sealed with a hybrid composite (Filtek Supreme XTE 3M™ ESPE™) using a layering technique. (*Figs. 5 and 6*)
7. The rubber dam is removed, and the bite is checked, and a post-operative X-ray is performed. (*Figs. 7 and 8*)

It is important to inform the patient that they need to return for follow-up appointments to check the apical closure and assess the pulp vitality. If these follow-up appointments, vitality tests and X-rays are not carried out, failure of the treatment due to a pupal necrosis following the treatment could go unnoticed. (*Figs. 9 and 10*)

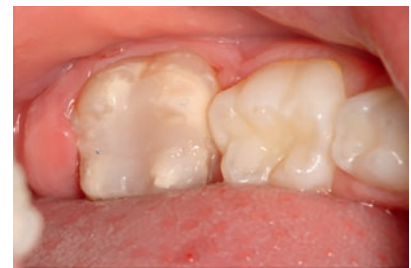

Fig. 7: Clinical view after the rubber dam is removed.

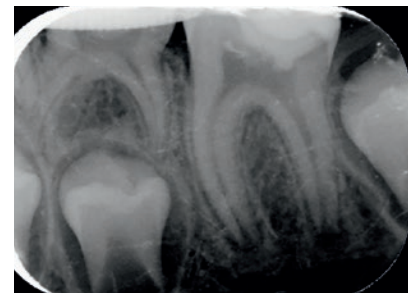


Fig. 8: Post-operative X-ray.

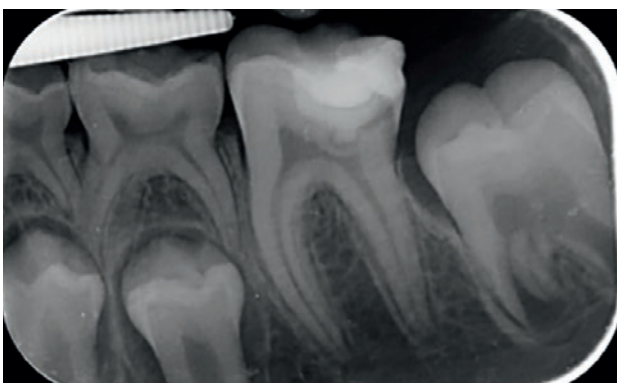


Fig. 9: X-ray at 18-month follow-up appointment showing dentin bridge formation underneath the Biodentine™, as well as apical closure.

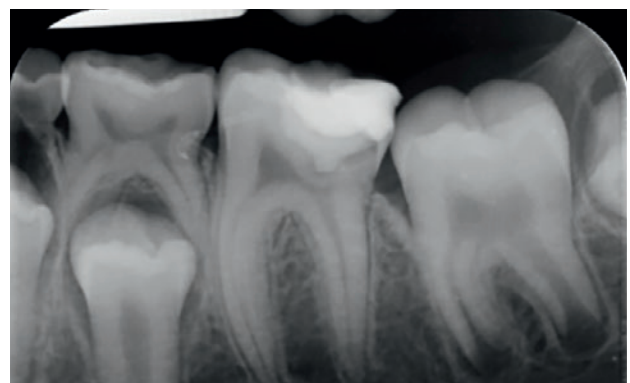



Fig. 10: X-ray at 30-month follow-up appointment showing the positive progression of the treatment.

Conclusion

In this clinical case study, the clinical and radiographic findings reveal that Biodentine™ exhibits good clinical and radiographic behavior in direct pulp capping treatment in immature permanent teeth.

References

1. Gwinnett AJ, Tay FR. Early and intermediate time response of the dental pulp to an acid etch technique in vivo. *Am J Dent* 1998;11:534-45
2. Rodrigues ML, Loguercio AD, Reis A, Muench, Cavalcanti de Araujo V. Adverse effects of human pulps after direct pulp capping with the different components from a total-etch, three-step adhesive system. *Dent Mater* 2005;21:599-607
3. Zhaofei L, Lihua C, Mingwen F, Qingan X. Direct Pulp Capping with Calcium Hydroxide or Mineral Trioxide Aggregate: A Meta-analysis. *J Endod* 2015;41:1412-7.
4. Cuadros C. Estudio clínico comparativo de diferentes agentes pulpaes en pulpotomías de molares primarios. [Comparative clinical study of different pulp agents for pulpotomy of primary molars] Doctorate thesis. Barcelona: International University of Catalonia. 2013.
5. Niranjani K, Prasad MG, Vasa AA, Divya G, Thakur MS, Saujanya K. Clinical evaluation of success of primary teeth pulpotomy using Mineral Trioxide Aggregate®, Laser and Biodentine™ an In Vivo Study. *J Clin Diagn Res* 2015; 9(4): 35-7.
6. Biodentine™. Active Biosilicate Technology™. Scientific File. Septodont Brochure.
7. Linu S, Lekshmi MS, Varunkumar VS and Sam Joseph VG: Treatment Outcome Following Direct Pulp Capping Using Bioceramic Materials in Mature Permanent Teeth with Carious Exposure: A Pilot Retrospective Study. *J Endod* 2017;43:1635-9.
8. Awawdeh L, Al-Qudah A, Hamouri H and Chakra RJ: Outcomes of Vital Pulp Therapy Using Mineral Trioxide Aggregate or Biodentine: A Prospective Randomized Clinical Trial. *J Endod* 2018;44:1603-9.
9. Parinyaprom N, Nirunsittirat A, Chuveera P, Lampang SN, Srisuwan T, Sastraruji T, Bua-on P, Simprasert S, Khoipanich I, Sutharaphan T, Theppimarn, S, Ue-srichai N, Tangtrakooljaroen W and Chompu-inwai P: Outcomes of Direct Pulp Capping by Using Either ProRoot Mineral Trioxide Aggregate or Biodentine in Permanent Teeth with Carious Pulp Exposure in 6 to 18 Year-Old Patients: A Randomized Controlled Trial. *J Endod* 2018;44:341-8.
10. Bakhtiar H, Nekoofar MH, Aminishakib P, Abedi F, Moosavi FN, Esnaashari E, Azizi A, Esmailian S, Ellini MR, Mesgarzadeh V, Sezavar M, and About I: Human Pulp Responses to Partial Pulpotomy Treatment with TheraCal as Compared with Biodentine and ProRoot MTA: A Clinical Trial. *J Endod* 2017;43:1786-91.
11. Brizuela C, Ormeño A, Cabrera C, Cabezas R, Inostroza C, Ramírez V and Mercadé M: Direct Pulp Capping with Calcium Hydroxide, Mineral Trioxide Aggregate, and Biodentine in Permanent Young Teeth with Caries: A Randomized Clinical Trial. *J Endod* 2017;43:1776-80.



Pulpotomy in primary teeth using Biodentine™: 18-month follow-up

Dr. Gloria Saavedra Marbán, Dr. Cristina González Aranda

Introduction

The pulpotomy treatment is performed on the primary tooth with deep caries or traumatic lesions, provided that it only affects the pulp in the pulpal chamber. In these cases, the radicular pulp is able to form tertiary dentin as a reparative response from the dentin-pulp complex. The purpose of this procedure is to preserve the vitality and function of the remaining radicular pulp until the primary tooth's physiological exfoliation. (1, 2).

The degree of damage to the primary tooth must be taken into account, because the pulpotomy treatment could fail if it is not possible to adequately reconstruct the tooth and seal the crown. (3,4).

Throughout history, different materials have been used to perform pulpotomies in primary teeth with different mechanisms of action in many cases. These materials had to meet the following requirements: present a bactericidal effect, be

innocuous to the pulp and surrounding tissues, as well as possess the ability to stimulate the healing of the radicular pulp without interfering with the physiological process of resorption, keeping the radicular pulp alive and healthy (4,5). The pulpotomy procedure is frequently categorized according to different treatment objectives: devitalization (mummification, cauterization), preservation (minimal devitalization) or regeneration (repair) (6).

Devitalization refers to the destruction of vital tissue, an effect achieved using formocresol, which, for decades, was considered the material of choice in pulpotomies in primary teeth. However, its cytotoxicity and its potential mutagenicity and carcinogenicity caused it to fall into disuse.

Preservation is achieved using materials that try to maintain the vital pulp, but without inducing the formation of reparative dentin. This can be

achieved with ferric sulphate or glutaraldehyde. Lastly, there is *regeneration* which is when the material used is able to maintain the vital pulp tissue as well as stimulate the formation of reparative dentin (7). The materials are made from calcium silicate, based on "Portland Cement"; MTA® being the most well-known product in this category. Pulpotomy studies with this material have reported very positive results (8-10). Recent studies show that Biodentine™ has very similar physical and biological properties to dentin, as it is a biocompatible and bioactive material that induces pulp repair. It has simpler handling properties than other bioactive mate-

rials with its shorter setting time. Additionally, its radiodensity is due to the fact that it contains zirconium oxide rather than bismuth oxide, so it doesn't discolor the tooth (11-13).

The working time is about 6 minutes, with the setting time being between 10 and 12 minutes after mixing. This allows the pulpotomy treatment and reconstruction to be carried out during the same clinical appointment, which is very advantageous when treating the child patient (13).

Below we present two clinical cases. In the first clinical case, we will provide a systematic review of the pulpotomy procedure using Biodentine™.

Clinical case report 1

A 5-year-7-month-old patient visits our surgery for the first time. The clinical examination showed a deep caries lesion in molar 8.5. with clinical signs of reversible pulpitis (*Fig. 1*). The bite-wing X-ray confirms the proximity of the lesion to the pulp, with no signs of lesions in the furcation or periapical areas (*Fig. 2*).

In our clinical practice, the pulpotomy procedure consisted of removing the coronal pulp and applying Biodentine™ over the root canal entry through performing the following steps:

1. Local anesthesia is administered, and the tooth is isolated with a rubber dam (*Fig. 3*).
2. The carious lesion is initially cleaned using a high-speed rotary instrument (Komet® 0.10 mm round diamond bur) and then

complete caries removal is performed using a slow-speed rotary instrument (Komet® 0.10 mm round tungsten-carbide bur). This step precedes the dentin removal from the chamber roof and opening to avoid pulp contamination.

3. A (Komet® 169L bur) is used to cut and (3M™ ESPE™) is used to adjust the preformed crown, prior to opening the pulp chamber to avoid contaminating the pulp chamber with residues.
4. The chamber roof is completely removed using a high-speed rotary device (Komet® 0.10 round diamond bur), with the opening wide enough to see the top of the root canals, taking into account the anatomy of each molar and the characteristics of the tooth being treated.

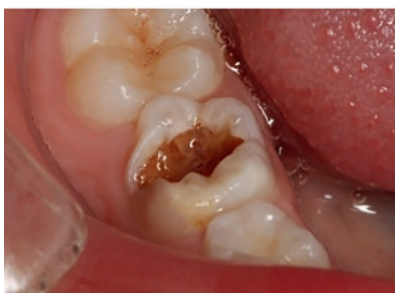

Fig. 1: Clinical view of molar 8.5.

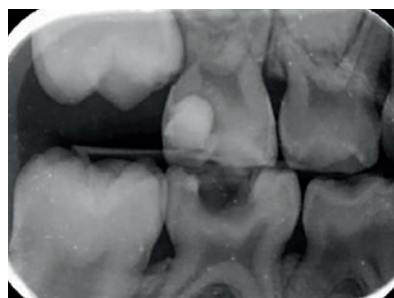


Fig. 2: Initial right bitewing X-ray.

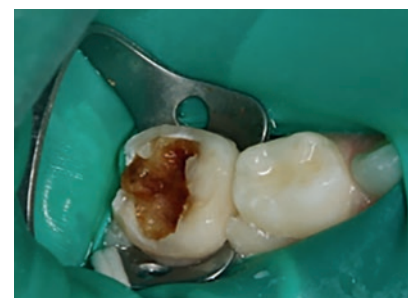

Fig. 3: Complete isolation of the fourth quadrant using a rubber dam.

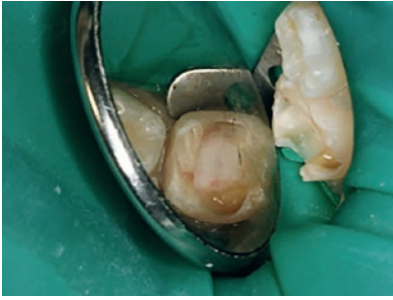

Fig. 4: Once the caries lesion was removed, the pulp chamber was dried with a cotton ball, the crown was then cut and adjusted, and the dental pulp was removed.

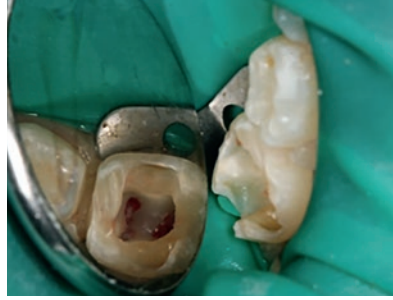

Fig. 5: Appearance of the opening to the root canals once it has clotted.

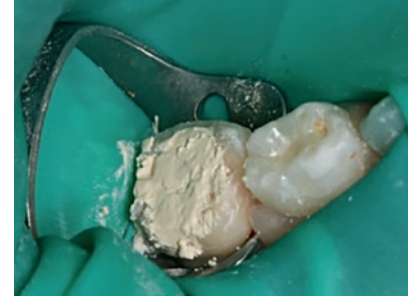


Fig. 6: Image after Biodentine™ has been applied.

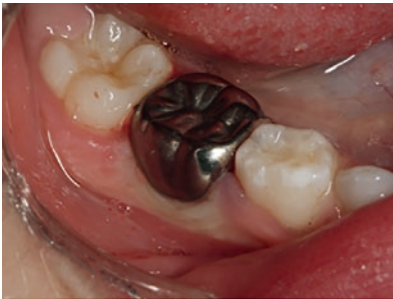

Fig. 7: Clinical view of the molar with the cemented crown, once the isolation was removed.

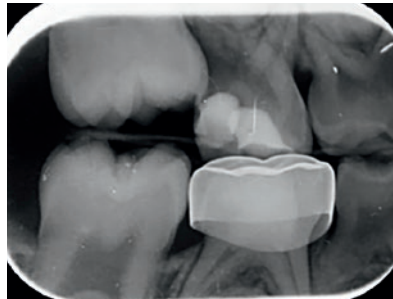


Fig. 8: Right bitewing X-ray after 6 months.

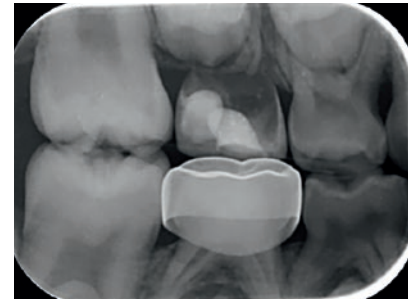


Fig. 9: Right bitewing X-ray after 18 months.

5. The dental pulp is cut out using a slow-speed rotary instrument with a large round bur (Komet® 0.21mm round tungsten-carbide bur), so that a clear and tear-free section of the pulp stumps remains at the opening to the radicular pulp.
6. The chamber is cleaned with water and dried with a piece of a cotton ball and checked to ensure that no pulp remains in the chamber (*Fig. 4*).
7. The pulp stumps are compressed using a cotton ball to clot the wound. Gentle pressure should be applied, and the lesion should be visually checked for clotting (*Fig. 5*).

8. Biodentine™ is applied to the pulp stumps and is used to fill the cavity (*Fig. 6*).
9. The preformed metal crown is adapted and cemented in (3M™ ESPE™) with self-curing glass-ionomer cement (Ketac™ Cem Easy Mix).
10. The isolation device is removed, the bite is checked, and the residual cement is cleaned up (*Fig. 7*).

In the follow-up appointments scheduled 6 and 18 months after the treatment, no clinical or radiographic signs or symptoms were found (*Figs. 8 and 9*).

Clinical case report 2

A 3-year-9-month-old patient visits our surgery for the first time. The clinical examination showed a deep caries lesion in molar 7.5. with clinical signs of reversible pulpitis. The periapical X-ray confirms the proximity of the lesion to the pulp without indicating any signs of lesion in the furcation or periapical areas, so the decision was to perform the pulpotomy treatment and reconstruct the tooth using a preformed

crown (Fig. 10). The clinical procedure was carried out using a system similar to the one previously described in Clinical Case Report 1 (Figs. 10, 11 and 12).

Figs. 13, 14, 15 and 16 show the X-rays taken immediately after the treatment, as well as those taken at the 6-month and 18-month follow-up appointments, which show dentin bridge formation.

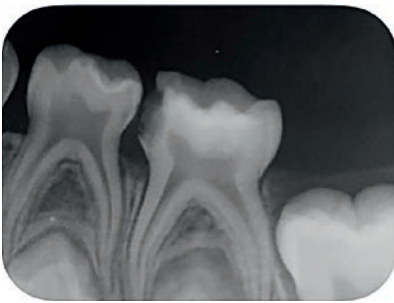


Fig. 10: Initial periapical X-ray of tooth 7.5 showing mesial-occlusal caries.

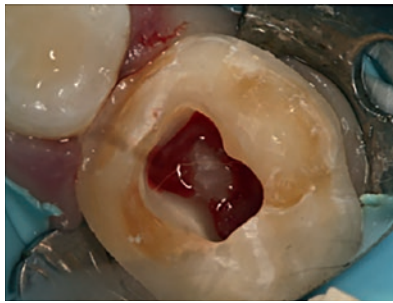


Fig. 11: Appearance of the opening to the root canals after clotting.

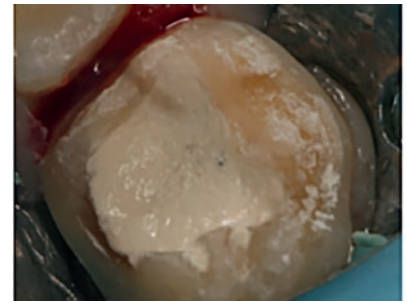


Fig. 12: Biodentine™ applied to the pulp chamber.

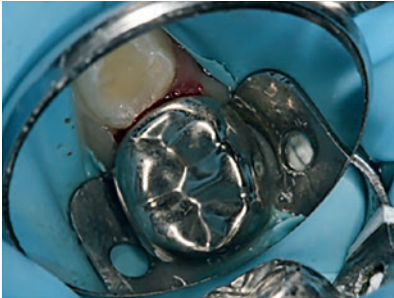


Fig. 13: Clinical view of the molar with the cemented crown, after the isolation system was removed.

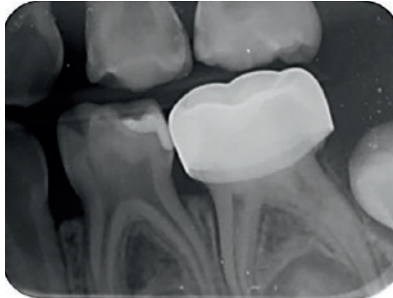


Fig. 14: Pulpotomy X-ray after Biodentine™ treatment.

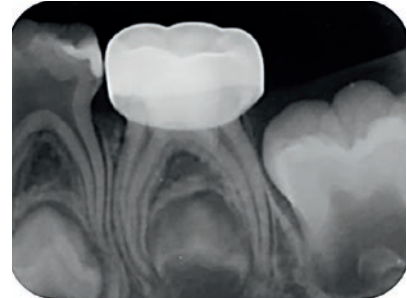


Fig. 15: X-ray taken at the 6-month follow-up appointment after Biodentine™ pulpotomy treatment.

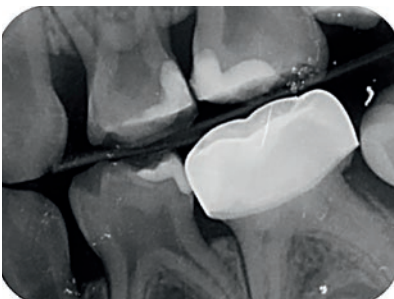


Fig. 16: X-ray taken at the 18-month follow-up appointment after Biodentine™ pulpotomy treatment. Dentin bridge formation can be seen in the mesial root.

Conclusion

In this clinical case study, the clinical and radiographic findings reveal that Biodentine™ exhibits good clinical and radiographic behavior in pulpotomies in primary teeth. However, more long-term randomized controlled clinical trials which support these observations would be desirable.



Author:

Dr Gloria Saavedrea Marbán

Bachelor's degree in Dentistry from Complutense University of Madrid (1994). Master's degree in Pediatric Dentistry from Complutense University of Madrid (1997). Specialist diploma in Dental Care in children with high-risk biological factors from Complutense University of Madrid (2001). Ph.D. in Dentistry from Complutense University of Madrid (2002).

Professor for the master's course in Pedodontics at Complutense University of Madrid (1998 to present).

Associate professor in the Department of Stomatology IV in the Faculty of Dentistry at Complutense University of Madrid (2009 to present).

Teaching coordinator for Pedodontics in the bachelor's degree in Dentistry at Alfonso X El Sabio University (1999 to 2008).

Ph.D. associate professor at Alfonso X El Sabio University (2005 to 2010).

Associate professor for the qualification "Specialist in Legal and Forensic Odontology" (2006 to present).

Representative for Pediatric Dentistry in the Science Committee at the Ilustre College of Dentists and Stomatologists in the First Region [Ilustre Colegio de Odontólogos y Estomatólogos de la I Región] (2011 to 2015).

Lecturer at many national courses and conferences.

Author of award-winning scientific papers for national and international conferences.

Author of publications and various chapters of books on Pediatric Dentistry.

Member of the Spanish Association of Pediatric Dentistry [S.E.O.P] (since 1996).

Private practice pediatric dentist in Madrid (since 1995).

References

1. Weisshaar S. Endodoncia en las denticiones primaria y mixta. Indicaciones, materiales y procedimientos para el tratamiento pulpar. [Endodontics in primary and mixed dentitions. Indications, materials and procedures for pulp therapy.] *Quintessence Int* 2001;52:371-9.
2. Fucks AB. Vital pulp therapy with new materials for primary teeth: new directions and treatment perspectives. *Pediatr Dent* 2008;30:211-9.
3. Rodd HD, Waterhouse PJ, Fucks AB, Fayle SA, Moffatuk MA. Pulp therapy for primary molars. National Clinical Guidelines in Paediatric Dentistry. *Int J Paediatr Dent* 2006;16 (Suppl. 1):15-23.
4. Maroto-Edo M. Estudio clínico del agregado trióxido mineral en pulpotomías de molares temporales. [Clinical study of the mineral trioxide aggregate in pulpotomies in primary molars.] Doctorate Thesis. Madrid: Complutense University of Madrid. 2003.
5. Sonmez D, Sari S, Cetinbas T. A comparison of four pulpotomy techniques in primary molars: a long term follow up. *J Endod* 2008;34(8):950-5.
6. Ng FK, Messer B. Mineral trioxide aggregate as a pulpotomy medicament: An evidence-based assessment. *Eur Arch Paediatr Dent* 2008;9(2):58-73.
7. Cortés-Lillo O, Boj-Quesada JR. Tratamientos pulpares en la dentición temporal. [Pulp therapy in primary dentition.] En Boj JR, Catalá M, García-Ballesta C, Mendoza A, Planells P, editores. *Odontopediatría. La evolución del niño al adulto joven. [Development from child to young adult.]* Madrid: Ed. Ripano SA; 2011, p 337-350.

8. Simancas-Pallares MA, Díaz-Caballero AJ, Luna-Ricardo LM. Mineral trioxide aggregate in primary teeth pulpotomy. A systematic literature review. *Med Oral Patol Oral Cir Bucal* 2010;15(6):942-6.
9. Aeinehchi M, Dadvand S, Fayazi S, Bayat-Movahed S. Randomized controlled trial of mineral trioxide aggregate and formocresol for pulpotomy in primary molar teeth. *Int Endod J* 2007;40:261–267
10. Ansari G, Ranjpour M. Mineral trioxide aggregate and formocresol pulpotomy of primary teeth: a 2-year follow-up. *Int Endod J* 2010;43:413–418.
11. Cuadros C. Estudio clínico comparativo de diferentes agentes pulpares en pulpotomías de molares primarios. [Comparative clinical study of different pulp agents for pulpotomy of primary molars] Doctorate thesis. Barcelona: International University of Catalonia. 2013
12. Niranjani K, Prasad MG, Vasa AA, Divya G, Thakur MS, Saujanya K. Clinical evaluation of success of primary teeth pulpotomy using Mineral Trioxide Aggregate®, Laser and Biodentine™ an In Vivo Study. *J Clin Diagn Res* 2015; 9(4): 35-7.
13. Biodentine™. Active Biosilicate Technology™. Scientific File. Septodont Brochure.

Download the complete series

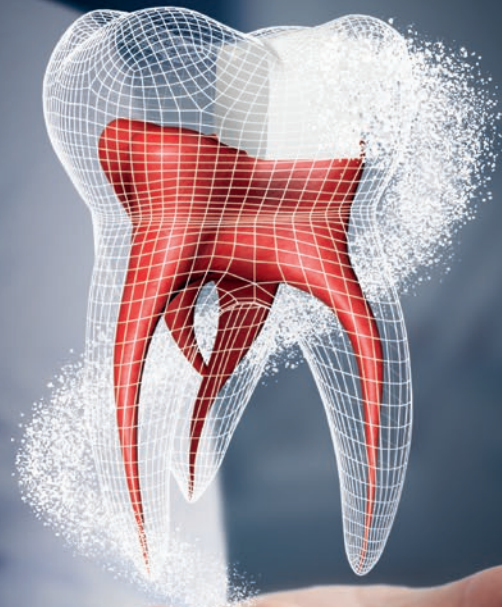
Septodont Case Studies Collection

www.septodont.com



Biodentine™

“First ever
Biological
Bulk Fill”



Pediatrics

Restorative

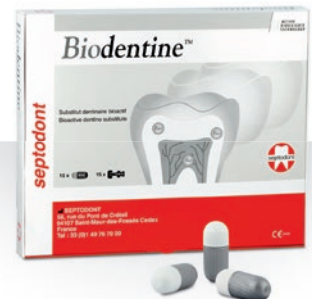Endodontics

For vital pulp therapy, bulk-filling the cavity with Biodentine™ makes your procedure better, easier and faster:

- Pulp healing promotion: proven biocompatibility and bioactivity
- Reduced risk of failure: strong sealing properties
- Only one material to fill the cavity from the pulp to the top
- Similar mechanical behavior as natural dentin: ideal for bulk filling

The final enamel restoration will be placed within 6 months.

Innovative by nature



ACTIVE
BIOSILICATE
TECHNOLOGY

Please visit our website for more information
www.septodont.com





The Dental Pharmaceutical Company

INNOVATIVE, SAFE AND EFFECTIVE SOLUTIONS FOR DENTISTRY WORLDWIDE