

# Septodont Case Studies *Collection*

No. 04 - March 2013

## Focus on:

### **BIODENTINE™**

TREATMENT OF TRAUMATIZED INCISORS  
RITA CAUWELS

### **N'DURANCE® CRISTAL**

CHOICE FOR CLINICAL SUCCESS  
MARKUS FIRLA

### **BIODENTINE™**

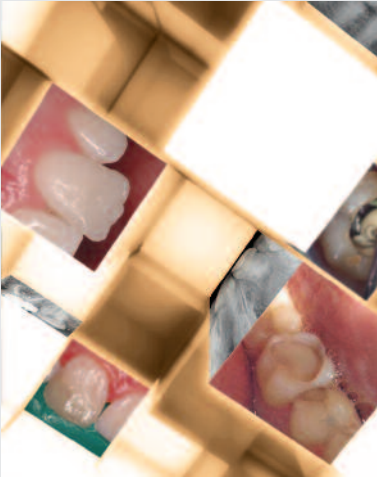PERFORATION REPAIR  
GODFREY CUTTS

### **BIODENTINE™**

DEEP CARIES TREATMENT  
OXANA DENGA



# Editorial



Since its foundation Septodont has developed, manufactured and distributed a wide range of high quality products for dental professionals.

Septodont has recently innovated in the field of gingival preparation, composites and dentine care with the introduction of Racegel, the N'Durance® line and Biodentine™, which are appreciated by clinicians around the globe.

Septodont created the “Septodont Case Studies Collection” to share with you their experience and the benefits of using these innovations in your daily practice.



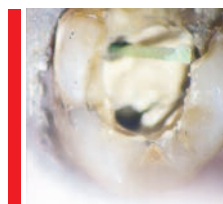

This Collection consists in a series of case reports and is published on a regular basis.

This fourth issue is dedicated to two of these innovations:

- **Biodentine™**: the first and only dentin in a capsule. Biodentine™ uniqueness not only lies in its innovative bioactive and ‘pulp-protective’ chemistry, but also in its universal application, both in the crown and in the root.
- **N'Durance® Cristal** : innovative composite based on our exclusive Nano-Dimer Technology. N'Durance® Cristal offers a selection of shades, designed for high-end anterior restorations, combined with both a low shrinkage and a high conversion.

This issue features case studies written by clinicians from 4 countries: Belgium, Germany, Ukraine and UK, illustrating the success of our innovations in a growing number of countries.

# Content

	<p><b>Biodentine™ Pulp therapy of traumatized immature incisors</b> Dr Rita Cauwels</p>	<b>04</b>
	<p><b>N'Durance® Cristal composite: A practitioner's choice for clinical success</b> Dr Markus T. Firla</p>	<b>09</b>
	<p><b>Repair of a perforation of the floor of the pulp chamber with Biodentine™</b> Dr Godfrey Cutts</p>	<b>14</b>
	<p><b>Clinical effectiveness of acute deep caries treatment</b> Prof Oxana Denga</p>	<b>16</b>



# Biodentine™ Pulp therapy of traumatized immature incisors

Dr Rita Cauwels  
University of Ghent, Belgium

## Introduction

Worldwide, the proportion of maxillofacial trauma in relation to all types of trauma varies from 9% to 33%. From all dental injuries 75% are related to the upper central incisors. The peak incidence of dental trauma in the permanent dentition is seen at 8 to 10 years of age.<sup>1</sup> The treatment of pulpal injury during this period provides a significant challenge for the clinician. At this particular age, the permanent incisors are not fully matured, characterized by an open apex and thin dentinal walls as a consequence of a wide flaring root canal. Depending upon the vitality of the affected pulp, two approaches are possible – apexogenesis or apexification.<sup>2</sup> Apexogenesis is a vital pulp therapy procedure performed to encourage continued physiological development and formation of the root end. In case of pulp necrosis, apexification is the treatment of choice inducing a calcified barrier in a root with an open apex or the continued apical development of an incomplete root.<sup>2</sup> Although the success rate of apexification with calcium hydroxide is 95%, its long-term prognosis appears to be compromised by cervical root fractures.<sup>3,4</sup> These fractures are strongly related to the stage of root development and defects at the cervical area.<sup>4</sup> However, this observation was also explained by the fact that long-term use of calcium hydroxide has a weakening effect on dentin due to a proteolytic reaction. In the early nineties, an alternative material based on calcium silicate, mineral trioxide aggregate (MTA), has been introduced.<sup>5</sup> MTA,

introduced as a material for apexification in a single visit, showed to cover some of the drawbacks of CH.<sup>6</sup> Biocompatible and bioactive properties of MTA as apical plug have been demonstrated in several studies.<sup>7,8</sup> Despite the formation of periapical abscesses with extensive periradicular bone resorption as a result of root canal infection in immature teeth, clinical studies using MTA reported conservative treatment allowing further root development.<sup>9,10,11</sup> However, because of its low mechanical properties, no strengthening effect was seen in weakened immature roots. Possible coronal discoloration after pulpotomy and long setting time are other drawbacks of MTA.

Biodentine™, a comparable tri-calcium silicate, has been developed as a dentine substitute in deep cavities. Comparable to MTA, Biodentine™ is biocompatible and in contact with vital tissues it has been demonstrated to be biologically active. In contrast with MTA, the material properties of Biodentine™ are similar to those of dentine. The compressive strength and elasticity modulus are comparable with dentine (Septodont; internal data). Moreover, no coronal discoloration has been reported. The material sets in 12 minutes and is capable to withstand deterioration when used as a temporary filling. Thanks to the excellent mechanical properties, comparable to those of dentine, Biodentine™ can be advised in weakened immature teeth.

## Case Report no.1 Apexification

A 9-year old girl was referred for treatment of pulp necrosis in an immature 21 as a consequence of a mild dental trauma a few weeks before. The immature maxillary central incisors 11 and 21 were involved. At that time, as Biodentine™ was not available yet, an MTA plug was placed for apexification with gutta-percha on top of it (Fig. 1.1). Three months later tooth 11 was also diagnosed with a necrotic pulp. After traditional rinsing of the canal with NaOCl but no instrumentation, 11 was filled with calcium hydroxide for 1 week awaiting a treatment with Biodentine™. In a second visit, the endodontic canal was obturated over the entire length with Biodentine™ (Fig. 1.2). No post-operative pain was reported. At 6 month follow-up no pathology was noticed on x-ray (Fig. 1.3). However, clinically, a light discoloration was observed for 21 which was treated with MTA (Fig. 1.4). It is known that MTA can be responsible for crown discoloration, in this case probably due to remnants of MTA at the cervical area. No pathology was seen at the apical zone in both incisors.

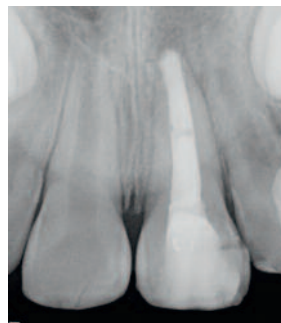


Fig. 1.1: One visit apexification with MTA and gutta percha of 21.

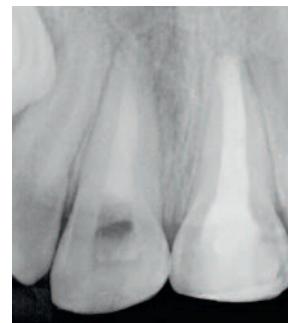

Fig. 1.2: Complete canal filling of 11 with Biodentine™.

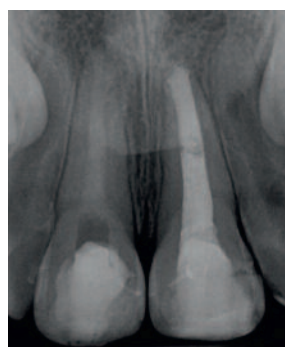


Fig. 1.3: X-ray at 6 months follow-up of 11 filled with Biodentine™ and 9 months follow-up of filled with 21 MTA plug + gutta-percha.

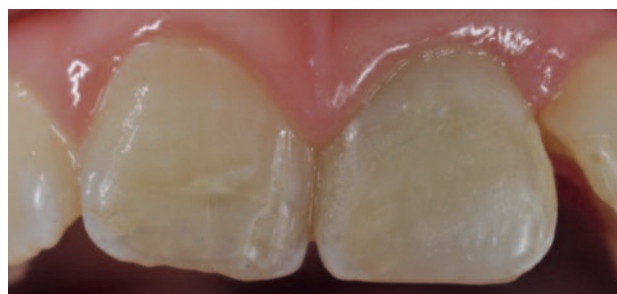

Fig. 1.4: Clinical view of 11 (Biodentine™) and 21 (MTA plug) revealing a light crown discoloration of 21.

## Case Report no.2 Apexification

A 9-year old boy was referred for treatment of an endodontic infection in 11. Ten months before, at the age of 8, he underwent a dental trauma resulting in luxation of 11 and 21 with uncomplicated enamel-dentine fractures and increased mobility. Both traumatized teeth were splinted for 2 weeks and restored with composite. Clinical examination revealed the presence of a fistula at the buccal side of 11 (Fig. 2.1). An x-ray showed an asymmetric development of both central incisors and a radiolucency at the apex of 11 (Fig. 2.2). This incisor remained in an

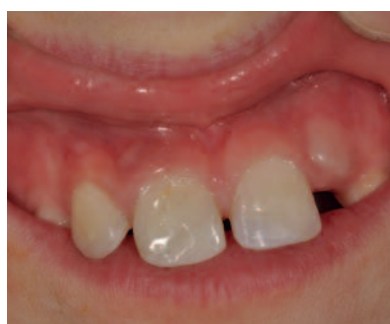

Fig. 2.1: Fistula (arrow) buccal from 11.

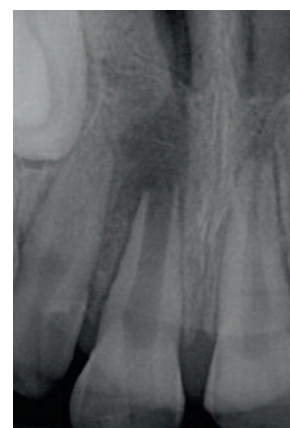

Fig. 2.2: Stop of root development of 11 due to pulp necrosis.

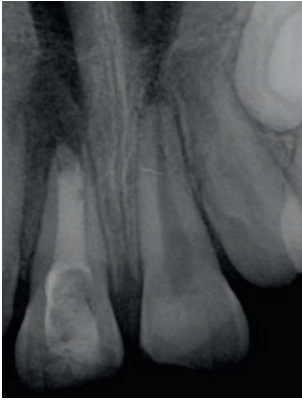

Fig. 2.3: 11 intermediate filled with calcium hydroxide.

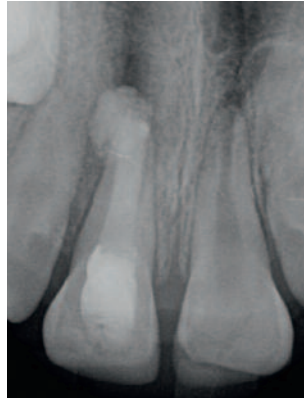

Fig. 2.4: 11 filled with Biodentine™ and showing an important apical extrusion of the material.

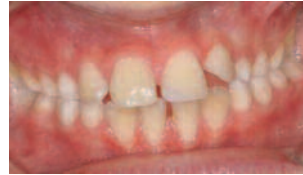

Fig. 2.5: Clinical view after 2 months showing healing.

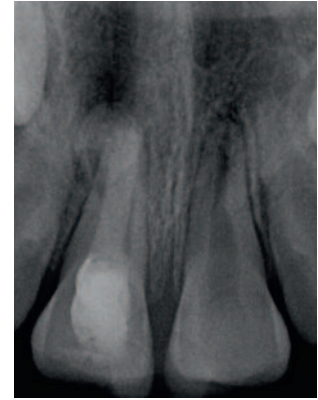

Fig. 2.6: A gradual resorption of the extruded material and healing of the apical granuloma was observed.

immature stage (open apex) revealing an arrested development due to pulp necrosis. In a first approach, the incisor was opened and endodontically rinsed with NaOCl in order to remove necrotic tissue. The canal was then dried and filled with calcium hydroxide paste for 2 weeks (Fig. 2.3). In a second setting, after removing calcium hydroxide, the canal was filled with

Biodentine™ (Fig. 2.4). An x-ray showed apical perforation of Biodentine™. No post-operative pain or tenderness was reported. After two months, clinically, the fistula disappeared and healing occurred (Fig. 2.5). A gradual resorption of the extruded material was shown in a radiograph (Fig. 2.6).

## Case Report no.3 - Apexogenesis

A 7-year old boy presented with a complicated crown fracture of 21. During sport activity he fractured his tooth (Fig. 3.1). The 21 was tender to percussion and the pulp was exposed. Local anesthesia was injected and the fracture side cleaned with saline solution. The

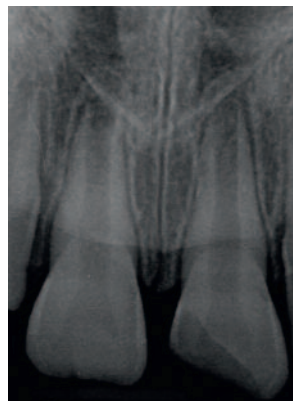

Fig. 3.1: Complicated crown fracture of 21, involving the dental pulp.

exposed pulp was covered in immediate contact with a layer of Biodentine™, which was simultaneously left as a temporary filling (Fig. 3.2). Four weeks later, a superficial layer of Biodentine™ was removed using a high speed diamond bur under water coolant and replaced by a

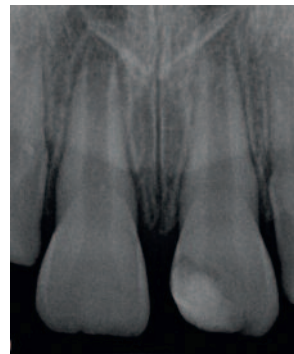


Fig. 3.2: Biodentine™ covering the pulp and left as a temporary filling.

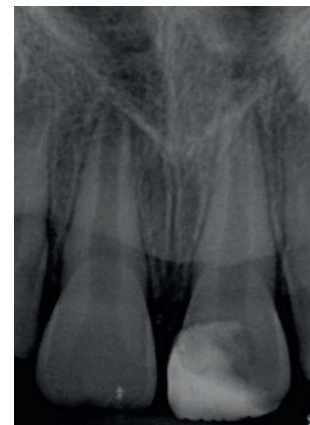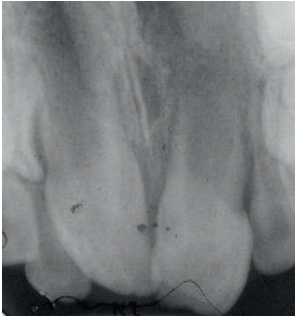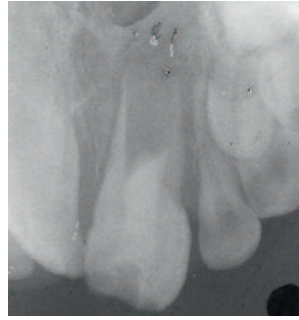


Fig. 3.3: X-ray revealing apexogenesis of both incisors during follow-up procedure. Biodentine™ was superficially replaced by a composite restoration.

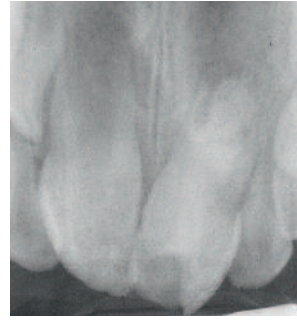
composite restoration. During this second visit, the patient did not complain from tenderness anymore. No pain was reported after the first visit. The x-ray did not reveal any sign of pathology. During the follow-up procedure, figure 3.3 shows a symmetrical apexogenesis of both central incisors.



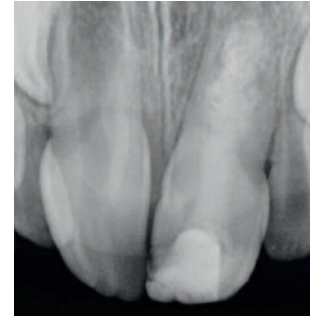*Fig. 4.1:* Abscess and apical radiolucency of 21



*Fig. 4.2:* Calcium hydroxide dressing in 21.



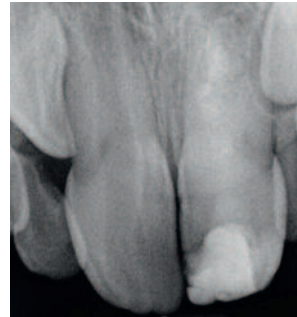*Fig. 4.3:* Biodentine™ filling in 21.



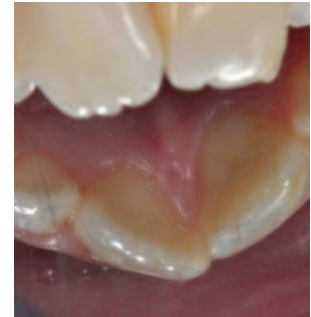*Fig. 4.4:* Apexogenesis after 6 months follow-up.

## Case Report no.4 Apexogenesis

A 6-year old boy was referred for treatment of an abscess of 21. He experienced a dental trauma 2 weeks before. A non-complicated crown fracture of 21 was diagnosed. Clinically he had a painful swelling buccally from 21 and pus was released from the sulcus during palpation. No pulp exposure however was present. The tooth showed an increased mobility and was tender to percussion. No sensitive reaction was felt in contact with cold stimulus, presuming complete pulp necrosis. X-ray revealed a highly immature incisor 21 with an important apical radiolucency (*Fig. 4.1*). After injection of local anesthesia, the 21 was opened and pus was released. The canal was thoroughly rinsed with NaOCl in order to remove necrotic tissue and remnants and finished by a saline solution rinsing. After drying the canal, calcium hydroxide



*Fig. 4.5:* Apexogenesis after 18 months follow-up.



*Fig. 4.6:* Clinical view of both incisors after 18 months of treatment.

paste was left for 3 weeks in immediate contact with the remaining tissue (*fig. 4.2*). During the next visit, no clinical symptoms were present. Patient did not suffer anymore from pain, no swelling and the element showed again normal mobility. Calcium hydroxide had to be repeated and left for another week due to persistence of humidity in the apical third. In the next session, calcium hydroxide was replaced by Biodentine™ (*Fig. 4.3*). Radiographic follow-up at 6 (*Fig. 4.4*) and 18 months (*Fig. 4.7*) showed an ongoing apexogenesis of 21, comparable to the untreated 11 (*Fig. 4.8*).

## Conclusion

Biodentine™ can be seen as the most appropriate material to treat endodontic compromised permanent immature teeth. No crown discoloration is seen, even not when the material is placed coronally. No post-operative pain was reported, moreover, clinical and radiographical

infection healing was apparent. Moreover, in two cases further root development was shown. Regarding the mechanical properties, it is assumed that Biodentine™ can withstand normal functional stresses in order to preserve the tooth.

**Author: Rita Cauwels**


Rita Cauwels graduated in 1980 and ran a general practice focusing on paediatric dentistry. In 1997 she received her MSc in Paediatric Dentistry and Special Care from the Ghent University. For many years she contributed regularly to the congresses of IADH, IAPD and EAPD. Dr Cauwels is actual council member of IAPD for Belgium. Since 2002 she has been working as a full-time clinical assistant at the department of Paediatric Dentistry focused on special care at the University Hospital Ghent and is a member of the PaeCaMed research group. She completed her PhD thesis on dental traumatology in collaboration with the University of Turku (Finland). One of her clinical interests includes laser treatment in paediatric dentistry and Low Level Laser therapy in oncology patients.

## References

---

01. Andreasen JO, Andreasen FM, Andersson L. Textbook and color atlas of traumatic injuries to the teeth. 4th edn. 2007 Blackwell Munksgaard. ISBN 978-1-4051-2954-1.
02. Rafter M. Apexification: a review. *Dent Traumatol* 2005; 21: 1-8.
03. Sheehy EC, Roberts GJ. Use of calcium hydroxide for apical barrier formation and healing in non-vital immature permanent teeth: a review. *Br Dent J* 1997; 183: 241-6.
04. Cvek M. Prognosis of luxated non-vital maxillary incisors treated with calcium hydroxide and filled with gutta-percha. A retrospective clinical study. *Endod Dent Traumatol* 1992; 8: 45-55.
05. Torabinejad M, Watson TF, Pitt Ford TR. Sealing ability of a mineral trioxide aggregate when used as a root end filling material. *J Endod* 1993;19:591-595.
06. Bakland LK, Andreasen JO. Will mineral trioxide aggregate replace calcium hydroxide in treating pulpal and periodontal healing complications subsequent to dental trauma? A review. *Dent Traumatol* 2012;28:25-32.
07. Torabinejad M, Pitt Ford TR, McKendry DJ, Abedi HR, Miller DA, Kariyawasam SP. Histologic assessment of mineral trioxed aggregate as a root-end filling in monkeys. *J Endod* 1997;23:225-228.
08. Torabinejad M, Hong C-U, Lee S-J, Monsef M, Pitt Ford TR. Investigation of mineral trioxide aggregate for root-end filling in dogs. *J Endod* 1995;21:603-608.
09. Iwaya SI, Ikawa M. Revascularization of an immature permanent tooth with apical periodontitis and sinus tract. *Dent Traumatol* 2001; 17: 185-187.
10. Banchs F, Trope M. Revascularization of immature permanent teeth with apical periodontitis: new treatment protocol? *J Endod* 2004; 30: 196-200.
11. Garcia-Godoy F, Murray PE. Recommendations for using regenerative endodontic procedures in permanent immature traumatized teeth. *Dent Traumatol* 2012; 28: 33-41.





# N'Durance® Cristal composite: A practitioner's choice for clinical success

Dr Markus T. Firla  
Private practice, Germany

Septodont's innovative composite system N'Durance® Cristal - now recently marketed as a continuous material improvement on Nano-Dimer-technology-based N'Durance® - is a "restorative of choice" for all clinical cases when esthetic demands, material properties and handling characteristics are to meet high-end quality direct restorations.

## | N'Durance® Cristal

*The universal composite N'Durance® Cristal is based on the polymer technology of nano-dimer conversion. Since the introduction of the composite restoration material N'Durance® by Septodont, this technology has acquired an important clinical place among composite restoration materials.*

Right from the beginning, trials carried out at the University of Leuven by Prof. Lambrechts and the University of Denver, Colorado by Prof. Newman demonstrated the many promising and positive material properties of this new improved composite material technology.

The improved material characteristics are based in particular on:

- **Nano-dimer-conversion technology** and a carefully balanced mix of dimethacrylate monomers that form the synthetic resin matrix,
- **Dimer-dicarbamate-dimethacrylate** ("dimer acid", DDCDMA), a proprietary monomer,

- **Ethoxylate-dimethacrylate** (EBPADMA) and
- **Urethane dimethacrylate** (UDMA), a well-established monomer with a solid track record, and finally
- **Polymerization-induced phase separation** (PIPS). This phenomenon describes the process of significantly reduced polymerization shrinkage of the monomer molecules during the curing phase. At the onset of polymerization of these monomer molecules there is a gradual separation of the initially completely miscible molecules leading to two-phase separation within the organic synthetic resin matrix.

Furthermore, the length of the monomer molecule present in the synthetic resin matrix containing a moiety of dimer-dicarbamate-dimethacrylate also has a positive impact on the dramatically reduced polymerization shrinkage. The dimer

acid molecule is approximately 50% larger than the simple methacrylate monomer molecule found in many conventional composites.

The complete chemical reaction called “nano-dimer-conversion technology” by the manufacturer therefore finds its full utility in this restorative material. It is particularly noteworthy in terms of its physical properties that a reduction in general polymerization shrinkage also lessens polymerization-induced shrinkage stress in the composite filling material. This is all the more important since it is the shrinkage stress in hardened composite that actively hinders complete micro-retentive adhesion of restoration material to dental enamel, giving way sooner or later to micro-leaks and substance loss along the bond between the composite and dental enamel.

### High level of polymerization

The high polymerization level of this universal composite system also has an important clinical role. Due to the chemical properties of the dimer-dicarbamate-dimethacrylate molecules, which are able to move more freely and unrestrictedly than conventional monomers during the polymerization process, a polymer crosslink rate (conversion level) of approximately 80% is achieved under normal curing light. Most other composite filling materials have values ranging from only 45 to 65% at most!

### Biocompatibility

This high conversion rate gives rise to far lower residual monomer content in the hardened composite, which in turn means considerably fewer monomers being released from the filling material. The lower the rate of monomer release from a composite material, the lower the risk of adverse biological reactions to the material. This clearly diminishes the risk of toxicity and allergic reactions.

### Marked hydrophobia

And last, but not least, mention must be made in this report of the marked hydrophobia of the special synthetic resin matrix. To keep this presentation succinct we will not go into greater

detail about the material, but it should be noted that its hydrophobia – a primary property of the material – is largely attributable to the chemical structure of the dimer-dicarbamate-dimethacrylate molecules.

The reduced water sorption of the composite material described above ensures that fewer constituents are washed out of the filler material. This means that the clinically relevant physico-mechanical material properties are more durable in the long-term.

## Excellent clinical performance

N’Durance® Cristal is available in the most common shades A1, A2, A3, A 3.5, B1, B2, C2 and as the universally applied enamel shade Incisal.

The clinical material parameter “user friendliness” is of particular importance for both the operator and the patient, and has a very positive impact. In the author’s opinion, based on 27 years of experience with intraoral adhesive preparation of direct composite filling materials, the following points are of key importance:

- **high polishability,**
- **very good color match** to the patient’s enamel
- **easy handling**

Although this restoration material is relatively viscous it is still very easy to apply from the screw syringes and single dose capsules. Its relatively high viscosity makes it ideally suited to modelling applications in class III and IV anterior cavities and for “packable” filling in posterior defects.

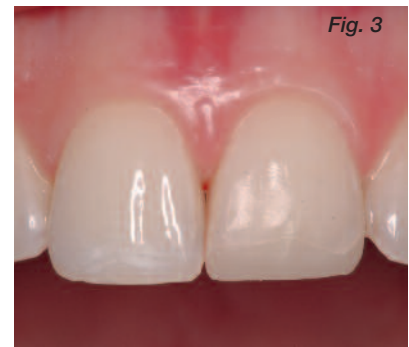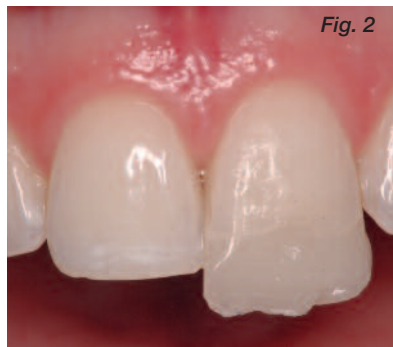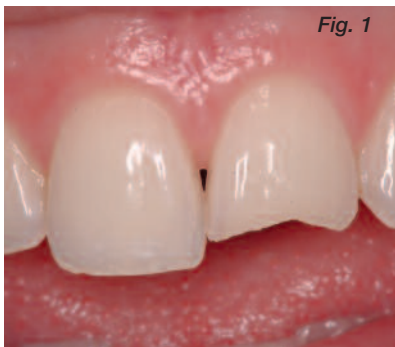### ■ Impressive radiopacity

Finally, it is also important to mention the surprisingly high radiopacity of this composite material system with an aluminum equivalent level of almost 4 mm.

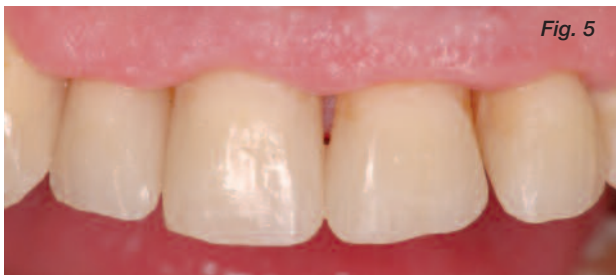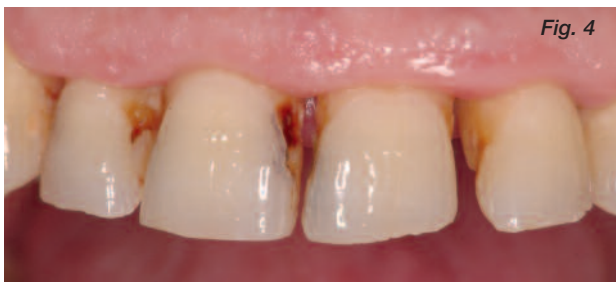## Clinical case no.1

**Figures 1 to 3** show an emergency treatment of a maxillary left central incisor. The young woman came to the practice without an appointment after an approximately 12-year-old composite build-up had broken off without apparent cause while she was eating lunch. In order to give the patient a “first-aid” treatment as quickly as possible, and because we were short of time, her treatment having been “squeezed” into the routine treatment schedule, we decided to carry out an adhesive direct monochromatic composite restoration using

the “bulk technique.” We therefore applied a single layer of N’Durance® Cristal, shade A2. Despite the time-consuming preparation of the enamel surface with 35% phosphoric acid followed by application of a self-conditioning all-in-one adhesive - both of which were necessary for adhesion - the treatment only took 12 minutes from start to finish, including contouring and surface-polishing the filling. The speed at which we were able to do owed much to the excellent esthetic and physic-mechanical material properties of N’Durance® Cristal.



**Fig. 1-3:** Emergency treatment of a left central incisor’s fractured off incisal portion (Fig.1). The adhesive composite restoration was executed by simply applying a one-layer bulk-increment of N’Durance® Cristal, color shade A2, without any mechanical preparation on the tooth’s surface (Fig.2). The whole restorative process – including contouring the restoration, light-curing, trimming and finishing, and adjusting the filling to proper occlusion – took only 12 minutes (Fig.3)



**Fig. 4-5:** Multiple approximal carious lesions in upper front teeth (Fig. 4). Given a sensible, regular clinical time frame of 45 minutes for all eight restorations – in accordance with the author’s rules of scheduling restorative treatments – an easy-to-handle, esthetically reliable composite material is essential for success.

N’Durance® Cristal composite, color shade A3, was used for all eight restorations in a one-layer-technique. This particular composite—specially conceived for anterior high-end quality restorations—is designed for “monochromatic” fillings that blend in perfectly with the visual appearance and color impression of natural tooth substance.

## Clinical case no.2

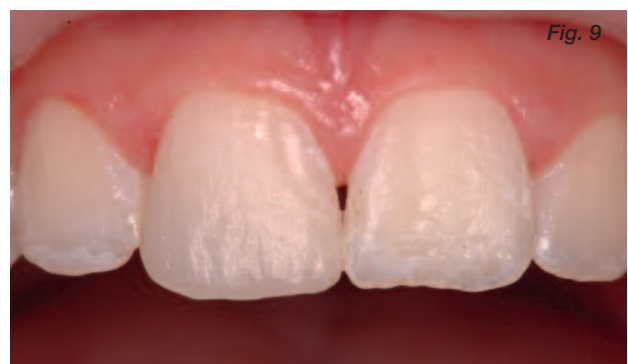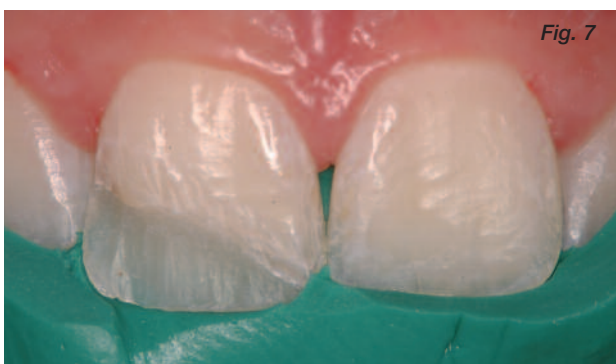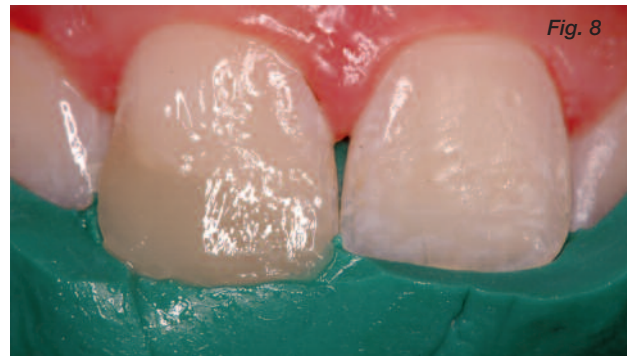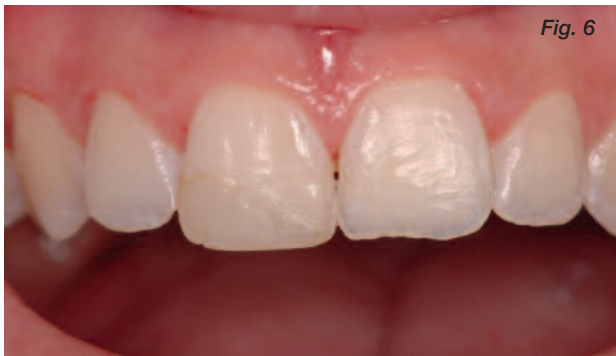This case shows a routine, planned filling treatment of the maxillary central incisors before (Fig. 4) and after treatment (Fig. 5). Due to the positive esthetic properties of N’Durance® Cristal we were able to carry out all eight restorations using only a single composite material. Shade A3 of N’Durance® Cristal was used for monochromatic filling of the individual cavities. Its excellent handling properties meant we were able to complete the entire filling treatment to the maxillary central incisors within only 30 minutes.

## Clinical case no.3

Replacing an insufficient corner build-up on a right maxillary central incisor to improve the overall esthetic impression (Fig. 6) was a considerable challenge, because the 17-year-old girl was very critical and had high esthetic expectations. It was important to preserve exactly the same shape of the tooth with the new filling. To achieve this we used an intraoral A-silicone plug assist to obtain an individual impression and ensure that the tooth shape was identical in the reconstruction (Fig. 7). To ensure that the color and light impression of the direct, adhesively applied composite restoration was completely optimal we decided to proceed using the “dual

layer technique.” First, we applied a palatal-incisal base layer of N’Durance® Cristal in shade A3.5 (Fig. 8). Once we had extensively light cured this relatively dark composite material the second composite layer was applied labially. N’Durance® Cristal Incisal was used for this material layer, since it has the most esthetic impact.

The very good polishing properties of all N’Durance® Cristal products enabled us, by contouring and polishing the filler surface, to create a “biomimetic” surface rapidly and easily (Fig. 9).



**Fig. 6-9:** Esthetically invalid composite Class-IV-restoration in a young woman’s right upper central incisor (Fig. 6). In order to achieve a fully acceptable esthetic result it was decided – in accordance with the patient’s wishes – to refer to the two-layer-technique involving a custom-made matrix (Fig. 7) when restoring the teeth with direct adhesive composites. N’Durance® Cristal, shade A 3..5, was applied as a first, shape-giving layer due to its excellent physical esthetic properties, e. g. “biomimetic” tooth color, life-like translucency and color stability after light curing (Fig. 8). The second, i.e. final, layer was applied with the same composite’s most translucent, universally usable shade Incisal. This restorative’s superb tooth color matching, blending-in properties (“chameleon effect”), along with the outstanding polishability of all N’Durance® composites, allow these high-end esthetic restorations to be completed in only a short time (Fig. 9).



**Author:**           **Dr Markus T. Firla**  
Hauptstrasse 55  
D-49205 Hasbergen-Gaste - Germany  
Email: Dr.Firla@t-online.de

Dr Firla has been a dentist for 20 years, managing his own practice since 1994, which has attained certification in ISO 9001:2000 (Requirements for Quality Management Systems) and EPA-Dent (European Practice Assessment for Dentistry) standards

## References

---

01. Barfuß A: Unsichtbar – Eine Rekonstruktion aus Komposit. Interview with Dr Oliver Kappler. Dent Mag 2011; 28: (I) 38-41.
02. Firla M T. Ästhetische Aspekte zur biomimetischen Schichttechnik. Zahnärztl Mitteil 1990; 80: (18) 1957-1962.
03. Firla M T. Biomimetische Kompositrestaurationen. DZW 2005; 19: (39) 22-23.
04. Firla M. T.: Direkte „einfache“ biomimetische Frontzahn-Komposit-Restaurationen. Dent Barometer 2010; 5: (6) 38-41.
05. Firla M Th: Hohe Biokompatibilität und gute werkstoffkundliche Eigenschaften bei Kompositen. DZW 2010; 24: (13) 17-19.
06. Firla M Th: Komposite auf Dimer-Säure-Basis. DZW Spezial 2010; 18: (2) Sonderdruck 1-3.
07. Mahn E: Die richtige Wahl bei Frontzahnfüllungen. Dentalzeit 10: (1) 36-38
08. Newman S M: Eine neue Technologie für Komposit-Füllungsmaterial. ZWR 2009; 118: 648-653.
09. Ozoglu A H: Minimalinvasiv restauriert. Dent Mag 2011; 28: (1) 44-46.
10. Roeters J, de Kloot H. Kosmetische Zahnheilkunde mit Hilfe von Komposit. – Praktische Anwendung der direkten Technik. Quintessenz Verlag Berlin, 1992.
11. Septodont: N'Durance® – Nano-Dimer Conversion Technology. Technisches Produktprofil DVD 2009.
12. Septodont: N'Durance® – Product information. 2009; Brochure.
13. Septodont: N'Durance® Cristal – Nano Dimer Technologie. Scientific File; 2012.
14. Trujillo-Lemon M et al: Dimethacrylate derivatives of Dimer Acid. J Polymer Science Part A: Polymer Chemistry 2006; 44: 3921-3929.

# Repair of a perforation of the floor of the pulp chamber with Biodentine™

Dr Godfrey Cutts

Private practice, United Kingdom

A 43 year old female patient was referred for possible endodontic treatment to 26 by her dental practitioner who states in the referral letter (*Fig 1*) that there is a possible perforation of the floor of the pulp chamber which has been “temporised with amalgam”

Dear Mr Cutts.

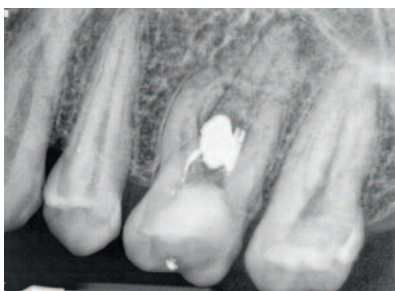
I would much appreciate if you could see and treat the above patient. I have commenced RCT on the UL6, during RX there has been a possible perforation at the floor of the chamber, this has been temporised with amalgam. The patient wishes to see an endodontic specialist for completion of the RCT if possible. Medically the patient is healthy.

Thankyou Very Much

Kind Regards,

*Fig. 1*

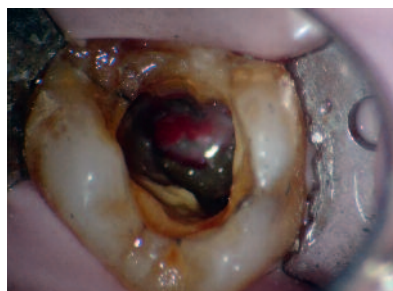Upon examination there was some buccal tenderness and the tooth was slightly tender to percussion. Radiographic examination (*Fig. 2*) demonstrates loss of the floor of the pulp



*Fig. 2*

chamber and a considerable amount of amalgam in the furcation.

Local anaesthetic was administered and the tooth isolated with rubber dam. After removal of the coronal temporary dressing the extent of the perforation was revealed and involved the whole of the floor of the pulp chamber including the orifice of the palatal and disto-buccal canals. (*Fig. 3*)



*Fig. 3*

The amalgam could not be removed intact since it was

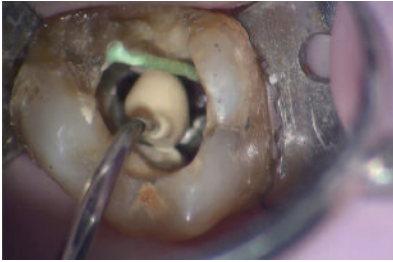


Fig. 4

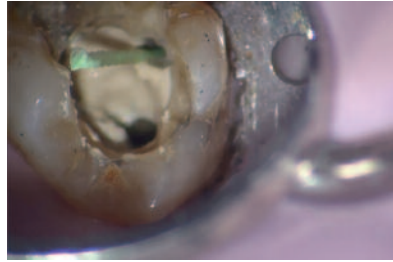


Fig. 5

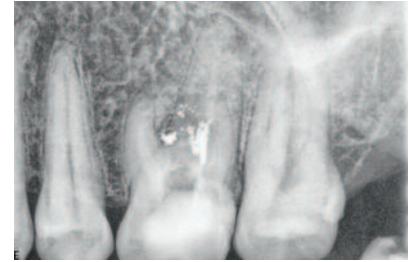


Fig. 6

convex and locked in the furcation. With judicious use of ultrasonic instruments from the "Satelec" EndoSuccess range the amalgam was gently fragmented and the majority removed.

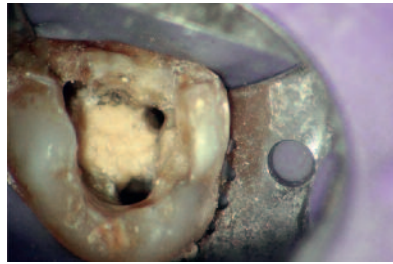


Fig. 7

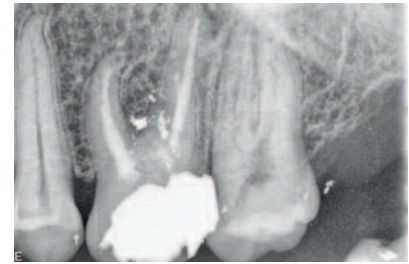


Fig. 8

The initial treatment plan was to carry out conventional endodontic treatment before repairing the perforation however this was not possible since the irrigants were leaking through the furcation and past the rubber dam. Repair of the perforation became the priority and this was carried out using Biodentine from Septodont. Before attempting the repair a paper point was placed in the disto-buccal canal to preserve patency. The perforation was dried gently using large paper points before placing the Biodentine passively in increments using a Thymozin instrument. (Fig. 4/5/6) Upon completion of repair of the perforation the Biodentine was allowed to set for 10 minutes before temporisation of the access cavity.

At the second visit one week later the access cavity was re-opened (Fig. 7/8) to perform conventional endodontic treatment with GIC used to restore the floor of the access cavity followed by a bonded amalgam core, the tooth was removed from the occlusion and the patient was advised to have a full coverage crown as soon as possible.

This case can be viewed on YouTube :



[http://www.youtube.com/watch?v=bLR8Lsm\\_zKo](http://www.youtube.com/watch?v=bLR8Lsm_zKo)



**Godfrey Cutts LDS Dunelm.**

Graduated from the Sutherland Dental School, Newcastle upon Tyne in 1961.

In general practice as a GDP in Nuneaton Warwickshire from 1964 until the present day.

In 1968 the practice was sold to Oasis Dental Care and has held posts with the company as Clinical Director and Clinical Advisor.

Has a special interest in endodontics and has attended numerous courses including those held at the Eastman Dental Institute and is a member of the British Endodontic Society attending their meetings on a regular basis. In the past eight years he has

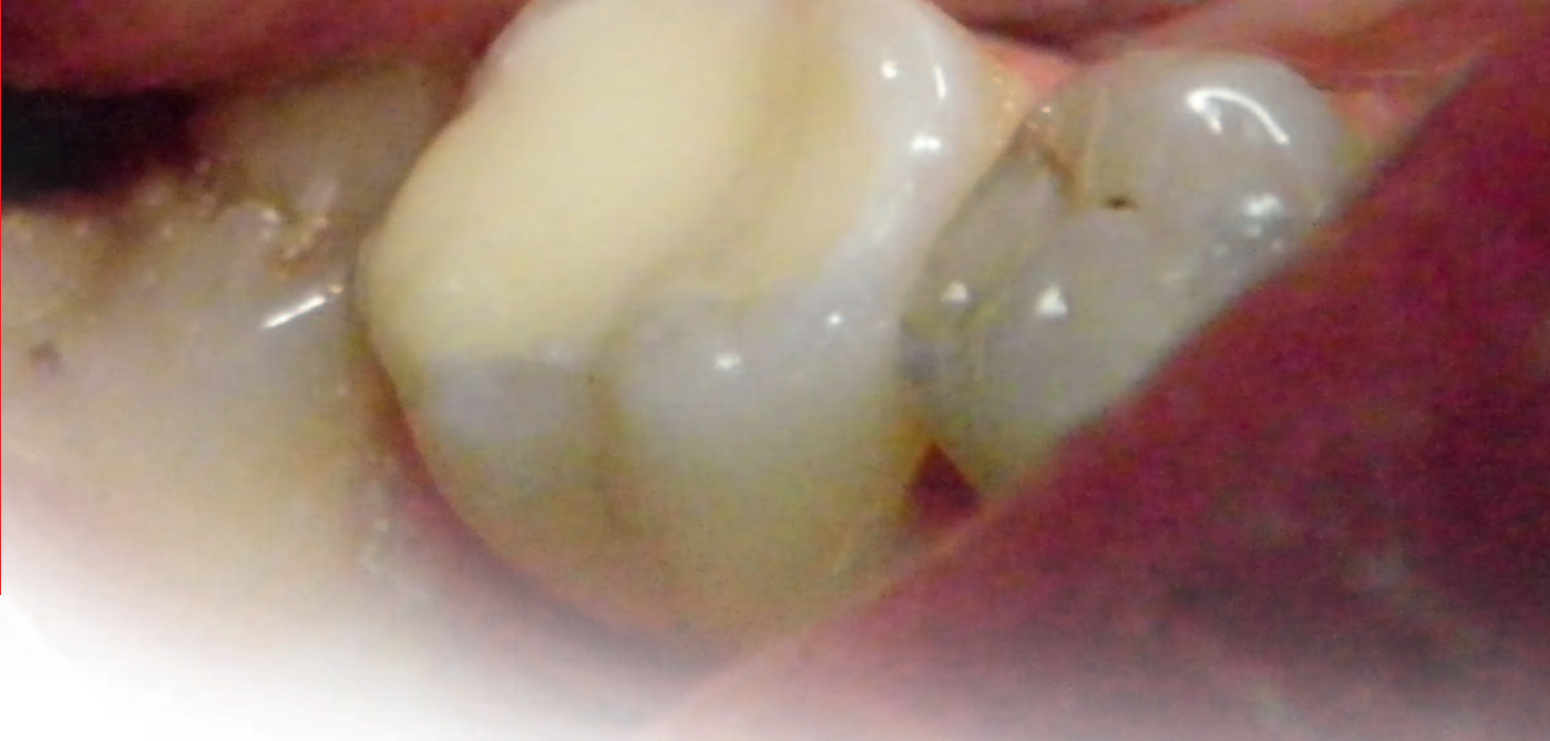organised and lectured at hands on courses for GDP's at venues around the country.

Has an active interest in developing new instruments, materials and protocols for their use to enhance treatment outcomes.

In 2005 he filmed and produced the instructional DVD for the use of RaCe Ni-Ti files.

Currently he has a successful endodontic referral practice, treating some 500 cases a year, where practitioners from some fifty miles around refer patients for initial treatments, re-treatments and apical micro-surgery.

godfrey@gcutts.co.uk



# Clinical effectiveness of acute deep caries treatment in patients with compromised allergic history using a novel calcium silicate material

Prof O.V. Denga, Dr M.V. Anisimov, Dr L.V. Anisimova  
SE "Institute of Stomatology of the NAMS of Ukraine"

Acute deep caries treatment with a step-by-step approach for patients with a compromised allergic history using "Biodentine™" (Septodont) is suggested. The clinical observations were performed on 40 patients. Thirty mandibular molars were treated in each group. The use of clinical-radiological and spectro-colorimetric techniques demonstrated the advantages of the chosen method of treatment in these patients.

## Introduction

Earlier conducted research showed that 22.5% of all dental patients have allergic compromised history [1]. At the same time, it was observed that these allergic compromised patients have a higher intensity of caries and lower level of non specific resistance [2, 3]. The main risk group with drug allergies represents the main risk group for the use of local dental anaesthetics. Most of the people from this group are also

allergic to latex rubber dam as well [2, 4]. This fact makes the treatment of this category of patients more complicated.

## Objectives

Evaluation of the clinical effectiveness of the proposed "step-by-step" treatment of acute deep caries in patients with a compromised allergic history with "Biodentine™".



## Methods and materials

For the comparative effectiveness of caries treatment there were two groups of patients: 21 patients in the test group and 19 patients in the control group. In each group 30 mandibular molars were treated.

The treatment was performed by one dentist. In the control group the treatment was completed using the invasive-restorative methodology according to the standard procedure. We used “Calcimol LC” (VOCO) as a liner. The glass-ionomer cement “Vitrebond” (3M ESPE) was used as an isolating liner. The crown build up was achieved with “Grandio” (VOCO) in combination with “Futurabond” (VOCO) as bonding system.

The deep caries treatment in the test group was carried out in two steps. During the first visit the patient had his cavity prepared (without local anaesthesia) in accordance with the principle of prophylactic filling. After toileting the cavity

with distilled water and drying it with cotton pellets, Biodentine™ (Septodont) was placed into the cavity for a period of 48 hours. During the second visit the upper layer of the Biodentine was cut down (2-3 mm) and the enamel was permanently restored with “Grandio” (VOCO) composite material. The fissures and blind fossae were filled with a pit and fissure sealant: “Fissurit” (VOCO).

The defects and complications were recorded on the basis of patients’ complaints, clinical examination in conjunction with roentgenograms. To evaluate the level of hard tissues mineralization during the deep acute caries treatment with Biodentine™, we used the spectro-colorimetric observations method by O.V. Denga [5].

All the optical and color parameters were recorded in the color coordinates, in the form of spectral distribution of the hard tissues’ reflection coefficient.

## Results of the research

During the dental treatment of patients with allergic compromised history, we also observed in some instances an intolerance/ reaction to latex rubber dams, sodium hypochlorite solution, thymol, and formocresol.

Taking into account the fact that these few unsatisfactory results were observed during the treatment without using local anaesthetics [6], we should improve the existing treatment algorithms.

For the caries treatment of dental patients with drug allergies, we suggested a two-visit approach. First the prophylactic filling of fissures, that involves a conservative preparation of the hard tissues at the level of the damaged enamel and dentin tissues, followed secondarily by the fissures and the blind fossae sealing. This point is very important for us, as the patients with drug allergies have a contra-indication to the use of local anaesthesia and the use of the

general anaesthesia is not always necessary during the dental procedure.

Hypo-allergic and highly technologic material, Biodentine™ was used as a dentin substitute material. Thanks to its chemistry, that contains mineral ingredients without monomers, Biodentine™ became the material of choice for this treatment. According to the manufacturer’s instruction, this material can be applied directly into the tooth cavity without the previous cleaning of the surface from the calcified tissues. By means of the total “sealing” of the dentin surface, the usage of this material can be a good background for pulp vitality preservation.

The clinical efficacy was evaluated during the following year. The clinical-radiological examination demonstrated the advantages of the chosen method for these patients. There were no cases of inefficient treatment in the test group of patients.

As for the control group, we observed three cases of secondary caries, in three more cases we observed poor marginal integrity, and in one case we observed the loss of the restoration. There were no complications in the form of periodontitis or pulpitis observed.

The initial rate of the hard tissue mineralization was the following:  $(10+1) \times 10^{-4}$  gradR. Nm<sup>-4</sup>. At 12 months, the analysis of the spectral distribution of the light reflection coefficient in the treated teeth showed a significant increase of the hard tissues mineralization, which was at the level of  $(3,8+2) \times 10^4$  gradR. nm<sup>4</sup>. The light

reflection coefficient with the wave length in the range of 450-480 nm was decreased by 2.6 times (Fig. 1).

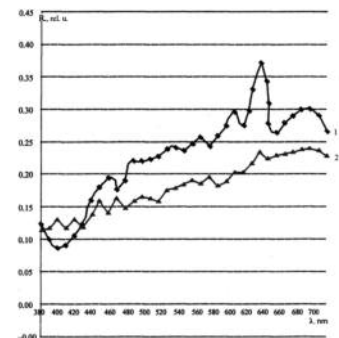

Fig. 1: Spectral distribution of the light reflection coefficient of the tooth 46 (curve 1- before the treatment, curve 2- 1 year after the treatment).

## Extract from the medical report

Patient N., born in 1985 came complaining about short term pain stimulated by chemical and thermal stimuli. The tooth had been aching for one month.

The medical history states an anaphylaxis of the second stage 5 years before during dental treatment. The laboratory diagnosis was held: IFA (immune fermentative analysis) special-articaine 2.26 ME/ml, mepivacaine -3,23 ME/ml, lidocaine – 1,16 ME/ml. The use of local anaesthetics was therefore contraindicated.

Objectively: there is a carious cavity on the occlusal surface, in the limits of circum-pulpal dentin of tooth 46, with a narrow entrance that is observed by the loose slightly pigmented tissue. There was a reaction on a thermal irritant

in the form of short termed pain; probing was painless, percussion was painless as well. EOD: 5.8 Mka (apparatus PULPTEST).

Diagnosis: Acute deep caries of tooth 46.

Treatment procedure: the conservative preparation of the cavity was held without using local anaesthetics (Fig. 2). The cavity was rinsed with distilled water and dried with a cotton pellet. Biodentine™ was applied into the cavity (Fig. 3). After 8 months the patient came back for the second visit. There were complaints. On the roentgenogram on the cavity bottom there were clearly noticeable “dentine bridges” (Fig. 4). The upper layer of the “artificial dentine” was removed (Fig. 5) and the complete restoration was made using “Grandio” (VOCO) (Fig. 6).

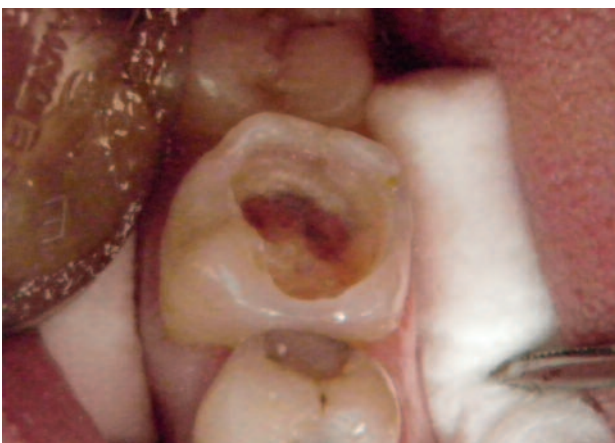

Fig. 2: Acute deep caries of tooth 46

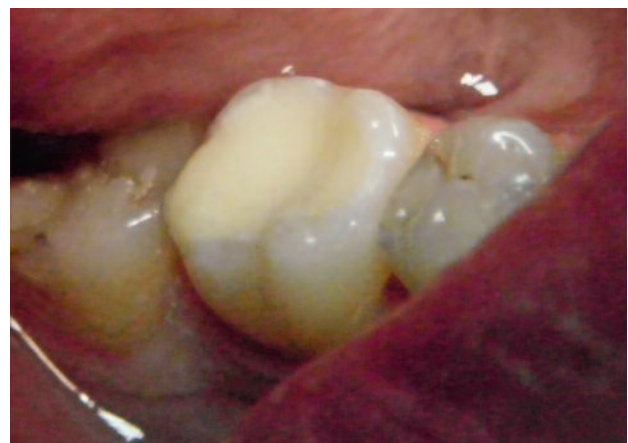

Fig. 3: The tooth is filled with “Biodentine™”

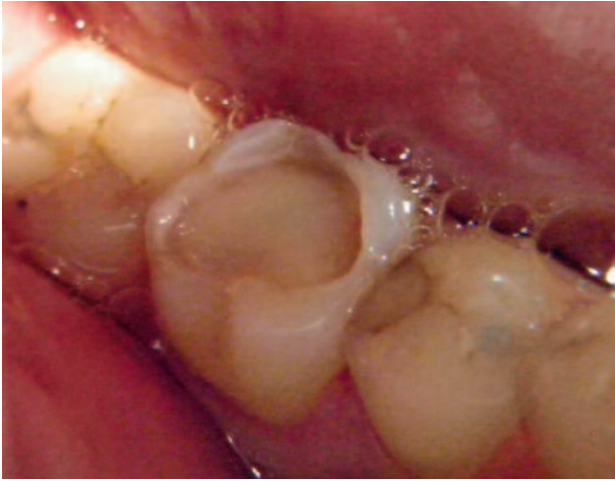

Fig. 4: Roentgenogram of the tooth 46 after 8 months. The “dentine bridges” are clearly seen on the cavity bottom

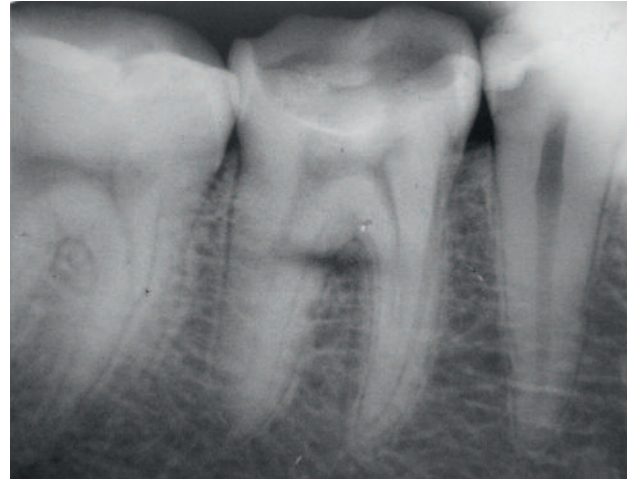


Fig. 5: The upper layer of “Biodentine™” is removed

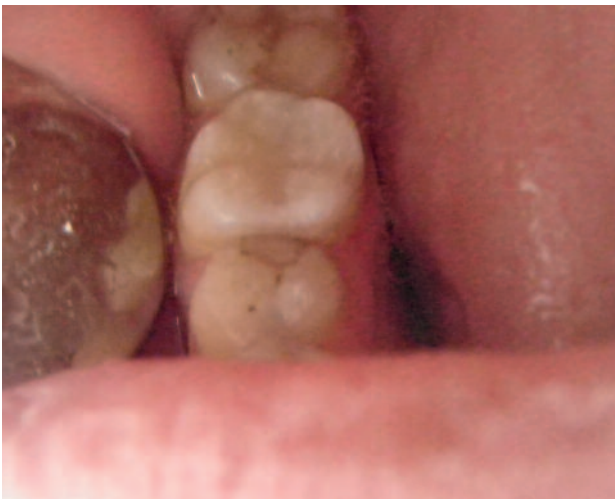

Fig. 6: Tooth 46 after treatment

## Conclusion

The clinical-radiological and spectro-colorimetric observations proved the advantages of the treatment method of such category of patients. There were no cases of ineffective caries treatment results in the test group of patients observed during this year. The level of the hard tissues mineralization increased sufficiently: from  $(10+1) \cdot 10^{-4}$  grad R, nm<sup>-1</sup> to  $(3.8+2) \cdot 10^{-4}$  grad R, nm<sup>-1</sup> for the light reflection coefficient, with the wave length in the range of 450-480 nm. We recommend using “Biodentine™” for treatment of patients with a drug allergy risk.



### Professor Denga Oxana

Honored doctor of Ukraine,

Doctor of Dental Science (DDS)

Professor, chairman of the Pediatric Dentistry Division (Scientific institute of dentistry, Academy of Medical Sciences of Ukraine)

Chairman of the Pediatric Dentistry Department (Odessa State Medical University)

Head of the Regional Pediatric Dentistry and Orthodontic Center

Vice-president of the regional section “Pediatric dentistry” of the Ukraine Association of Dentists (ASU),

President of the Ukrainian Dental Hygienists Association

Member of the International Association of Paediatric Dentistry (IAPD)

Member of the European Association of Dental Public Health (EADPH)

Member of the International dental Collage (ICD)

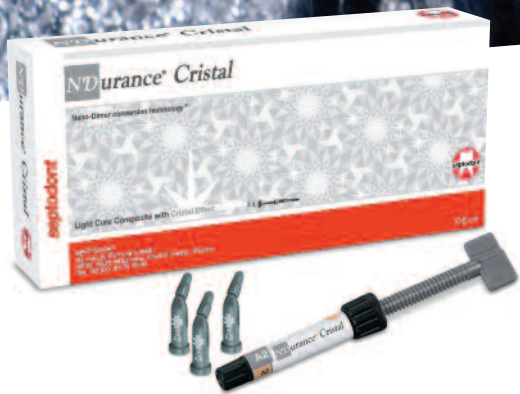
## References

---

01. Anisimov M. V. Prevalence of allergic reactions conditioned by usage of local anesthetics. / Anisimov M. V., L.V. Anisimova // Conference proceedings "Scientific and practical aspects of individual and professional oral hygiene". – Odessa, 2009. – P. 9-10.
02. Admakin O. I. Oral health status of children and adolescents with allergic pathology / O. I. Admakin, N. A. Geppe, Ad. A. Mamedov, D. A. Baysagurov // Dental forum. – 2005. – N°4. – P. 30-35.
03. Achmerova A. Ph. Clinical progression characteristics and prevention of caries and periodontal diseases in children with allergosis: Candidate's dissertation / A.Ph. Achmerova. – Kazan, 2001. – P. 133.
04. Veber V. R. Local anesthesia in dental patients with comorbidity: Tutorials / V. R. Veber, B.T. Moroz. – SPb.: Human, 2004. – 80 pages.
05. Denga O. V. Adaptogenic prevention and treatment of pediatric dentistry diseases: synopsis of PhD thesis: specialty occupation: «Dentistry» / O. V. Denga. – K., 2001. – 32 pages.
06. Anisimov M. V. Caries and pulpitis treatment efficiency depending on anesthesia method in patients with burdened allergic history / M. V. Anisimov // Dentistry messenger. – 2011. – N°4.

**N'Durance® Cristal**

A unique blend  
of beauty  
and science



New **N'Durance® Cristal** composite offers an unsurpassed combination of beautiful, natural translucency along with the science of our proven Nano-Dimer Technology and delivers:

- **High-end esthetic** properties for exquisite anterior restorations
- **Soft-on-demand handling** thanks to adapted thixotropy
- **Low shrinkage** for improved marginal integrity and reduced microleakage
- **High monomer conversion** for greater durability and biocompatibility

To see the **unique blend of beauty and science**, ask your dental distributor about new N'Durance® Cristal.





The Dental Pharmaceutical Company

---

INNOVATIVE, SAFE AND EFFECTIVE SOLUTIONS FOR DENTISTRY WORLDWIDE