

Periodontal intraosseous defects and post-extraction compromised socket. Treatment with Beta Tricalcium phosphate

C.D.E.P. Mario Ernesto García Briseño

The use of safety graft materials, with predictability and availability, is indicated in intraosseous defect treatment and in tooth extractions where the healing of the alveolar ridge is compromised. A clinical case is presented with both conditions and the osseous graft substitute, R.T.R., is used in their treatment.

Introduction

The inflammatory response as a result of periodontal infection leads to the loss of tooth support tissues¹. The alveolar bone and its three components, cortical plates, trabecular bone and bundle bone (alveolar bone proper), are lost through periodontal infection². Other conditions can worsen the periodontal condition, mainly endodontic, prosthetic and traumatic complications^{3,4,5}. When the tooth extraction is indicated, the anatomic characteristics of the alveolus, the associated lesion and phenotype of the periodontal tissues can lead to a healing of the alveolar ridge with an inadequate morphology

to the replacement of the lost tooth with fixed/removable prosthetics and/or dental implants^{6,7,8}. Restoration of adequate conditions in the periodontium destroyed by periodontal infection to preserve the dentition in health and function^{9,10}, and/or maximizing the healing conditions in the alveolar ridge post extraction for prosthetic restoration^{11,12}, is indicated with the use of graft materials. It provides predictable results, safe use and no availability restrictions. These characteristics are present in the synthetic bone graft substitute R.T.R. (beta tricalcium phosphate)^{13,14,15,16}.

Clinical Cases

62-year-old patient with recurrent periodontal disease without infection control after a previous treatment in February 2007. The main concern is “I do not want to lose my teeth”. The clinical aspect shows high plaque score, signs of inflammation, bleeding on probing, periodontal attachment lost and, radiographically, bone lost, pathologic migration and inadequate occlusal relations (figs. 1,2). At the beginning of the retreatment the patient was instructed about the problem with emphasis on infection control by meticulous daily plaque control and oral home care. Once the change in attitude and compromise were noted, the treatment plan was initiated.

Diagnosis

Chronic generalized periodontal disease with advanced periodontal attachment lost.

Treatment plan

Flap debridement and scaling and root planing in superior arch and scaling and root planing alone in lower arch. Prognosis in the anterosuperior segment is reserved.

Procedure description

Anterosuperior segment. Flap debridement and scaling and root planing filling the osseous defects with bone graft substitute, R.T.R, and collagen membrane (Figs. 3,4).

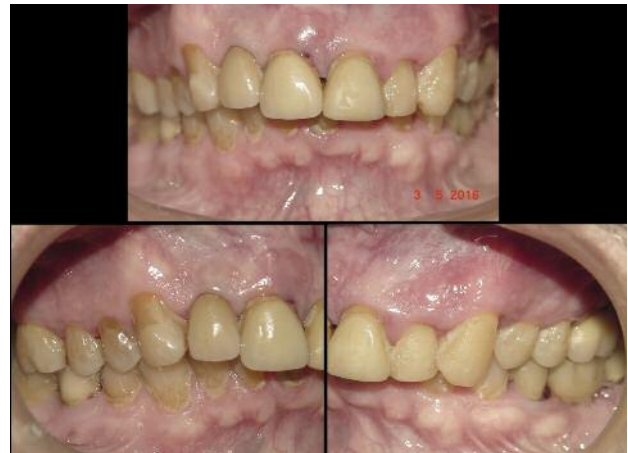

Fig. 1

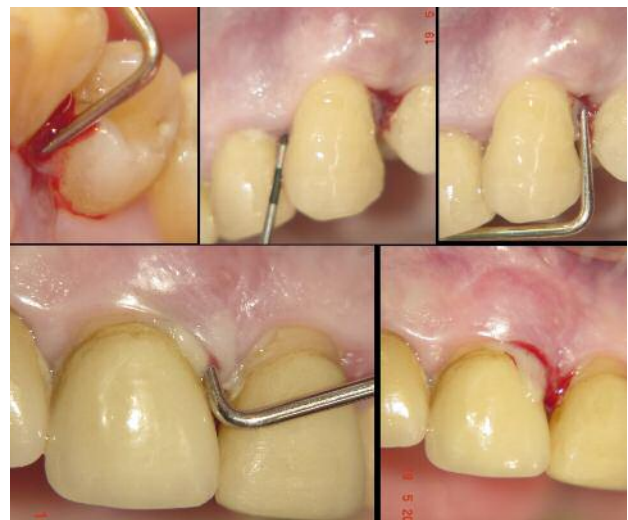

Fig. 2

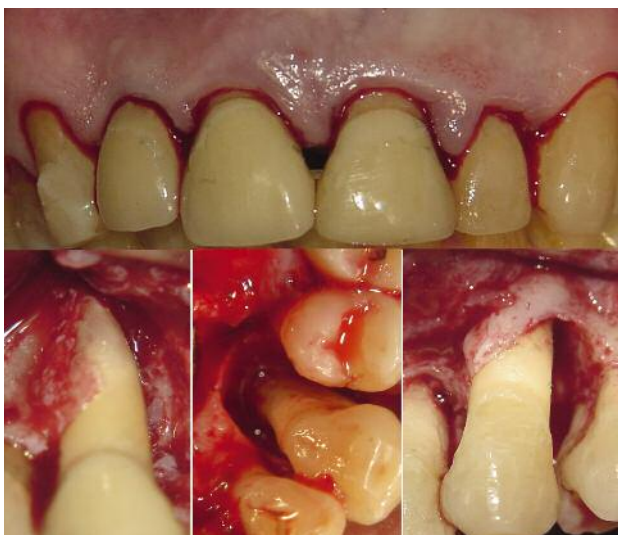

Fig. 3

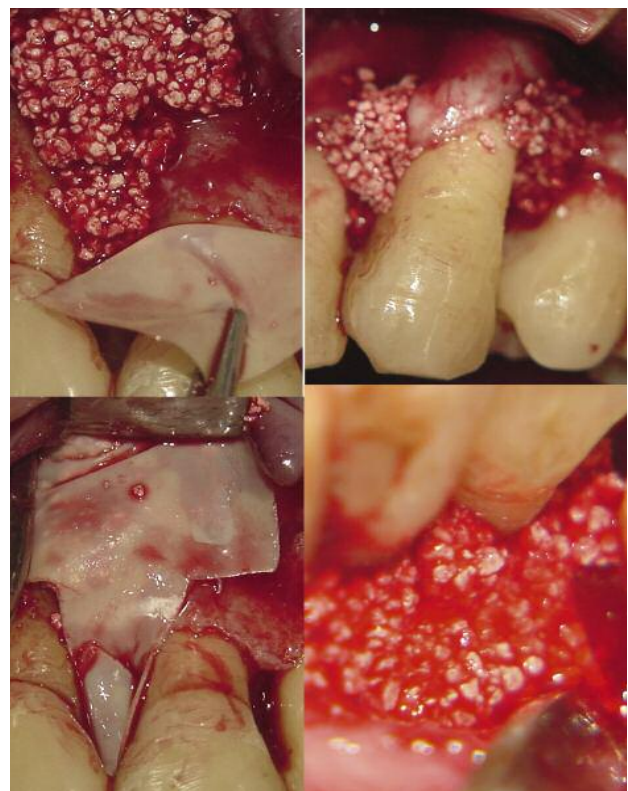


Fig. 4

Healing

The initial radiographs show bone loss and, in radiographs 10 months later, the bone-fill in the defects is evident (Fig. 5). Initial clinical view and healing (Fig. 6).

In the lower right quadrant, extraction of tooth 46 is depicted. The distal alveolus and bone defect with loss of the vestibular plate was

filled with bone graft substitute, R.T.R. cones. The blood clot covers the intact alveolus of the mesial root (Fig. 7).

Figure 9 shows the complete osseous filling of the osseous defect and the compromised socket post extraction at the time of the implant surgery with bone regeneration at 9 months, and radiographic evidence.

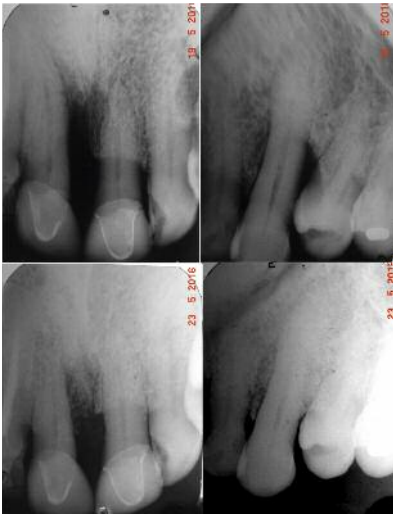

Fig. 5

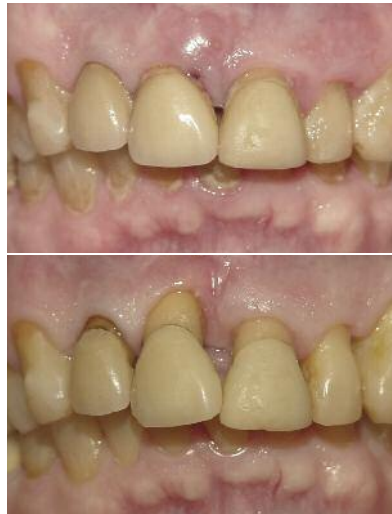

Fig. 6

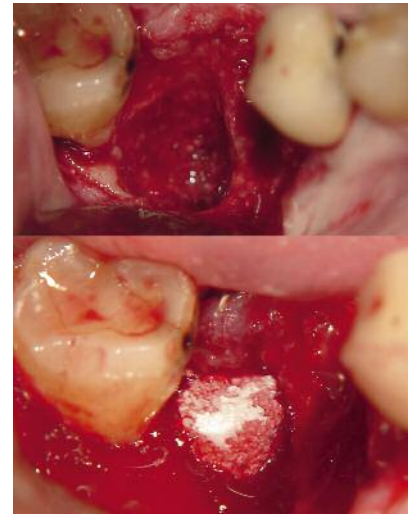

Fig. 7

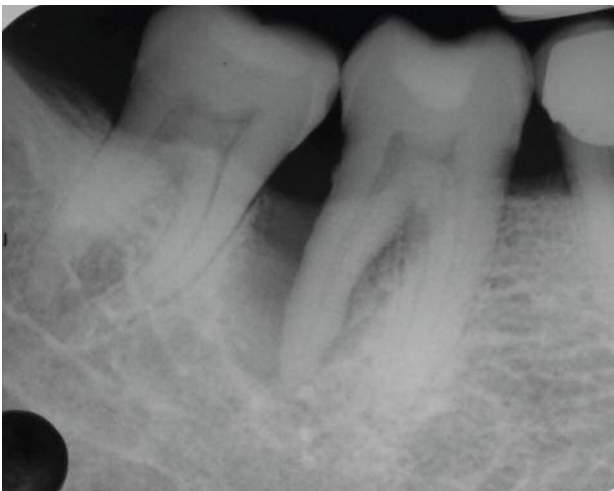

Fig. 8: View of the radiographic initial lesion.

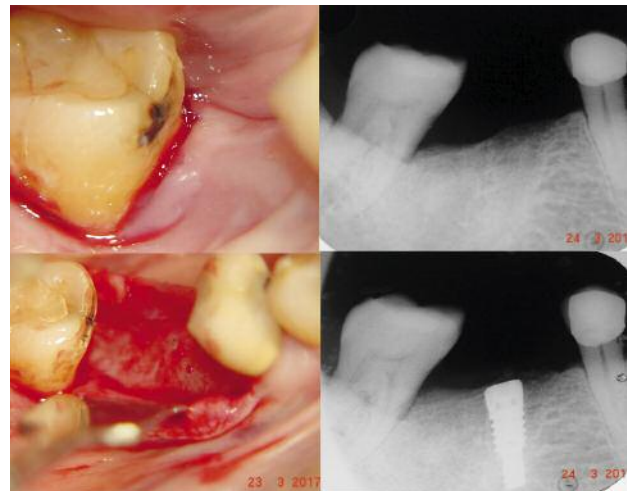


Fig. 9

Conclusion

Loss of periodontal attachment and the consequent alveolar bone destruction resulting from the periodontal infection require procedures to provide periodontal regeneration. This goal requires an accurate diagnosis of the condition and high practitioner skills. Predictability is restricted to certain situations. The loss of the bone morphology in the residual ridge post extraction is worse if combined with periodontal attachment loss, extraction procedure compli-

cations, periapical lesions and/or traumatic events. Prevention and improvement of the healing post extraction is a common procedure with restorative, prosthetic and implant dentistry. The use of a bone substitute graft material like beta tricalcium phosphate (R.T.R., Septodont) ensures biologically secure procedures, predictability in results and total availability. The clinical results are adequate and scientific evidence-based.



Authors:

Mario Ernesto García Briseño

Graduated from the Universidad Autónoma of Guadalajara as a Dental Surgeon (1971-1976).

Specialty in Periodontics at the Universidad Nacional Autónoma of México (1985-1987).

Coordinator of the specialty program in Periodontology at the Universidad Autónoma of Guadalajara from 1993 to 2015 (22 years).

Professor of the Pathogenesis of Periodontal Disease I and II, Etiology of Periodontal Disease, Occlusion, IV Periodontics, Clinical Cases I and II Seminar and Interdisciplinary Seminar in the Periodontics Specialty of the Autonomous University of Guadalajara from 1993 to date.

Instructor in the Periodontics specialty clinic from 1993 to date (24 years).

Professor of the Periodontics Course in the Specialties of Endodontics, Oral Rehabilitation and Orthodontics from 1993 to 2015.

Founding Member of the Mexican Association of Periodontology and President Biennium 1996-1998).

Founding Member and Secretary in the first board of directors of the Mexican Council of Periodontics 1996.

Certificate no. 005 of the Mexican Board of Periodontics from 1996 to date.

Founder and Academic Coordinator of Periodontology GDL, A.C. College of Periodontist from 2005 to date.

Prize Jalisco Dentistry 2002.

Opinion leader at Crest Oral B.

Leader of opinion in Septodont Mexico.

International lecturer and author of 3 publications of the company Septodont, France.

Member of the Academy of Osseointegration since 2015.

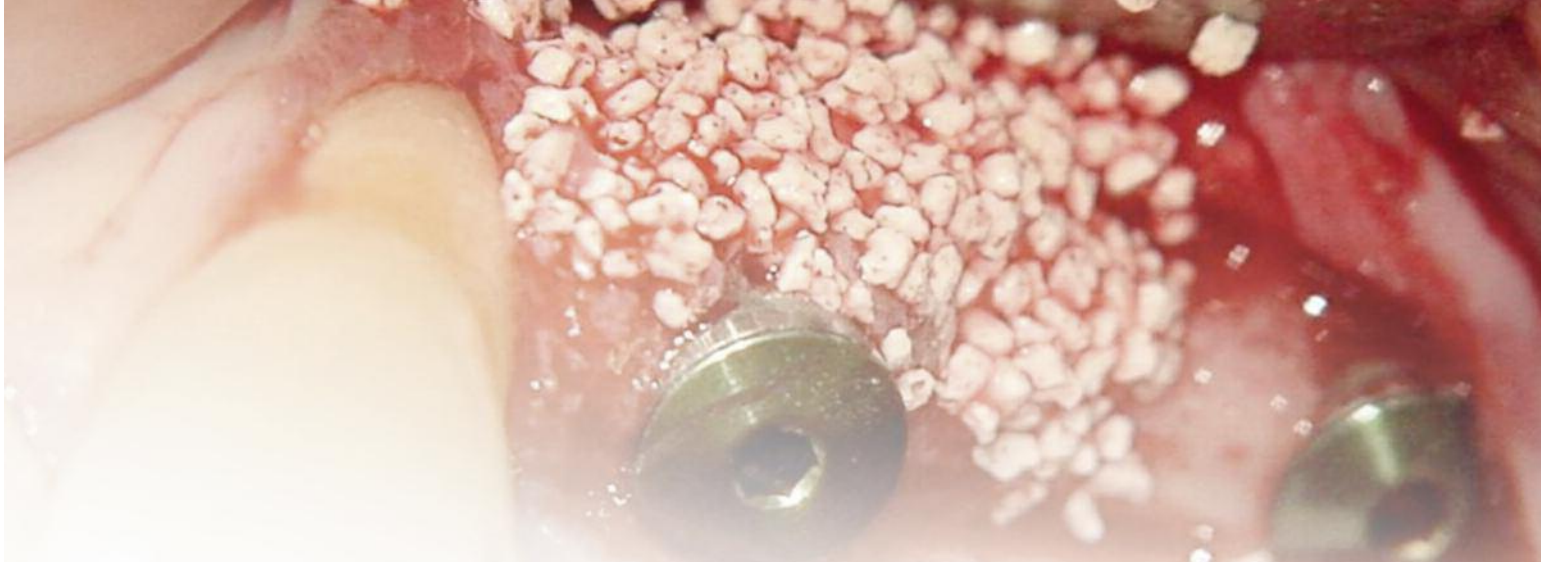Member of the American Academy of Periodontology 1989 to 2010.

Author of 10 publications in national and foreign journals and 3 international presentations (Webinar) (Coa, Septodont and CMD).

Director and private practice in Professional Periodontology from 1987 to date.

References

01. Listgarten M A: Patogenesis of periodontitis. *J Clin Periodontol* 1986;13:418-425.
02. Waerhaug J. The angular bone defect and its relationship to trauma from occlusion and down growth of subgingival plaque. *J Clin Periodontol*. 1979;6:61-82.
03. Iqbal MK, Kim S. A review of factors influencing treatment planning decisions of single-tooth implants versus preserving natural teeth with nonsurgical endodontic therapy. *J Endod*. 2008;34: 519-529.
04. Zitzmann NU, Krastl G, Walter C et al. Strategic considerations in treatment planning: deciding when to treat, extract, or replace a questionable tooth. *J Prosthet Dent*. 2010;104:80-91.
05. Hiatt WH. Pulpal periodontal disease. *J Periodontol*. 1977;48:598-609.
06. Boyne PJ. Osseous repair of the postextraction alveolus in man. *Oral Surg Oral Med Oral Pathol*. 1966;21:805-813.
07. Pietrokovski J, Massler M. Alveolar ridge resorption following tooth extraction. *J Prosthet Dent*. 1967;17:21-27.
08. Lekovic V, Kenney EB, Weinlaender M et al. A bone regenerative approach to alveolar ridge maintenance following tooth extraction. Report of 10 cases. *J Periodontol*. 1997; 68: 563-570.
09. Bowers GM, Granet M, Stevens M, Emerson J, Coria R, Mellonig J et al. Histologic evaluation of new attachment in humans. *J Periodontol*. 1986; 75: 280-293.
10. Hammerle CH. Membranes and bone substitutes in guided bone regeneration. In: Lang NP, Karring T, Lindhe J, eds. *Proceedings of the 3rd European workshop on periodontology. Implant dentistry*. Berlin: Quintessenz Verlag; 1999. pp.468-499.
11. Avila-Ortiz G, Elangovan S, Kramer KWO, D. Blanchette, Dawson DV. Effect of Alveolar Ridge Preservation after Tooth Extraction: A Systematic Review and Meta-analysis. *J Dent Res*. 2014 93:950-958.
12. Orgeas GV, Clementini M, De Risi V, de Sanctis M. Surgical Techniques for Alveolar Socket Preservation: A Systematic Review *Int J Oral Maxillofac*. 2013;28:1049-1061.
13. Labanca M, Leonida A, Rodella FL. Natural or synthetic biomaterials in dentistry: science and ethic as criteria for their use. *Implantologia*. 2008; 1: 9-23.
14. Metsger DS et al. Tricalcium phosphate ceramic. a resorbable bone implant: review and current status. *J Am Dent Assoc*. 1982; 105: 1035-1038.
15. Jensen SS, Broggini N, Hjorting-Hansen E, Schenk R, Buser D. Bone healing and graft resorption of autograft, anorganic bovine bone and beta-tricalcium phosphate. A histologic and histomorphometric study in the mandibles of minipigs. *Clin Oral Implants Res*. 2006; 17: 237-243.
16. Artzi Z, Weinreb M, Givol N et al. Biomaterial resorption rate and healing site morphology of inorganic bovine bone and beta-tricalcium phosphate in the canine: a 24-month longitudinal histologic study and morphometric analysis. *Int J Oral Maxillofac Implants*. 2004; 19: 357-368.



Sinus Floor Augmentation with β -Tricalcium Phosphate (R.T.R. Septodont)

Mario Ernesto García-Briseño

DDS and Professor in Periodontics - Autonomous University of Guadalajara (UAG), Mexico

Resorption of the alveolar process and pneumatization of sinus in the edentulous posterior maxilla are a clinical challenge in the restorative/prosthetic treatment with dental implants. Diverse surgical procedures, bone grafts and substitutes have been used to repair that clinical situations. Reports have shown radiographic, histomorphometric and clinical significant results with β -Tricalcium Phosphate. Two clinical cases of sinus floor augmentation with β -Tricalcium Phosphate (R.T.R. Septodont) or the subsequent insertion of dental implant are presented in this report.

History

Resorption of the alveolar process and the pneumatization of the sinus in the posterior edentulous maxilla often represents a clinical challenge in restorative/prosthetic treatment with dental implants (1).

Al-Nawas and Schiegnitz (2014), continuing the work of Klein (3), have proposed a classification of augmentation procedures in which graft materials are used for bone formation in therapy with dental implants:

1) Maxillary sinus floor augmentation, including the lateral window technique and transalveolar approach and, 2) vertical and/or lateral alveolar ridge augmentation, including dehiscence-type and/or fenestration-type defect around the implant (2).

The biological and physiological properties of the bone grafts and bone substitute materials

(BSM) have been described in terms of osteoinductivity, osteoconductivity and osteogenicity. Osteoconductivity can be described in terms of a biocompatible scaffold, resorbable at different speeds and time, in which the material reacts without consequences with the tissues at the receptor site. The three-dimensional structure of the material mostly facilitates vascular proliferation and, soon after, colonization and growth of osteoprogenitor and osteogenic cells. The physical and chemical properties influence bone formation to a lesser degree (4).

Tricalcium Phosphate

With a composition and crystallinity similar to the mineral phase of bone, Tricalcium Phosphate ($\text{Ca}_3(\text{PO}_4)_2$) is a biocompatible and bioresorbable material. Biodegradation of the material occurs in two ways: dissolution and osteoclastic resorp-

tion (5). Animal models have shown the resorption of beta-TCP, its replacement by bone and formation of bone marrow (6). Particle size, microporosity and speed of resorption confer its osteoconductive properties and promote the bone formation process (7, 8). Placed directly in cancellous bone, it retains its osteoconductive properties, and no tissue or systemic reactions were reported (9). Osteoconductive properties have been reported at ectopic sites (10). For decades, it has been used in Orthopaedics and multiple dental applications (11-14).

Procedure for maxillary sinus floor elevation

Two authors developed the surgical technique to augment bone height from the base of the maxillary floor (15, 16). Various modifications have been reported in the literature, but retaining the initial proposal: increasing the vertical dimension from

the maxillary sinus floor with the use of graft and/or bone substitute materials placed between detached epithelial membrane and the denuded bone (17, 18, 24). The use of bone substitute materials has been reported in maxillary sinus floor augmentation procedures (19), including beta-tricalcium phosphate (20-22), with histomorphometric analysis (23) and simplified techniques (24). Trombelli et al. (2014) report the results of transcrestal maxillary sinus floor elevation done with a minimally invasive procedure and combined with the additional use of deproteinized bovine bone mineral or beta-tricalcium phosphate. (24) The survival of dental implants in maxillary sinus floor augmentation procedures with β -tricalcium phosphate has been reported. (1) The authors report an increase in bone quantity associated with a decrease in grafted material and the presence of osteoclasts around the remaining particles of material. No complications or loss of implants were reported at 12 months.

Case Report no.1

Female patient, 56 years of age

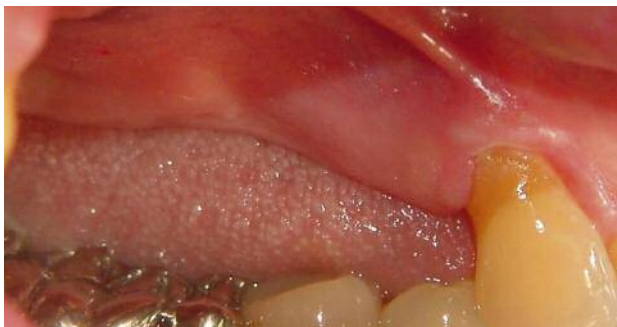

Fig. 1: Edentulous area, first quadrant. Absence of premolars and molars lost 12 years ago. Replaced with removable partial denture.

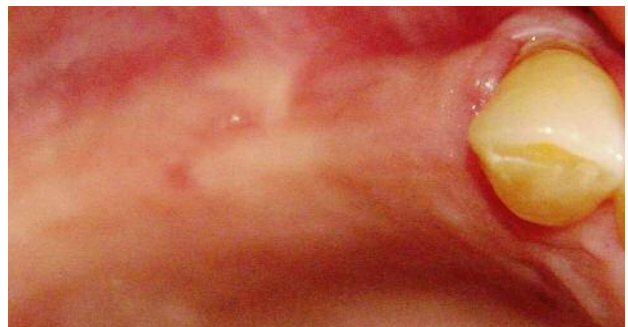

Fig. 2: Occlusal view, quadrant 1.

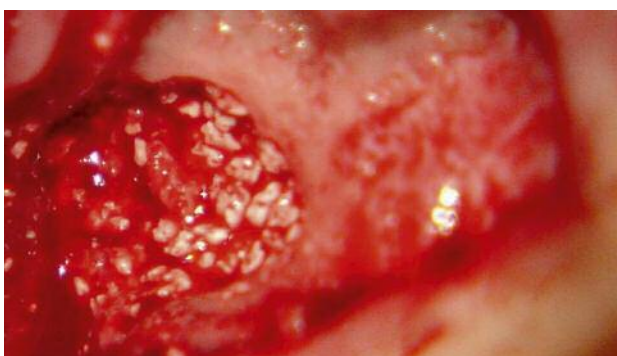

Fig. 3: Maxillary sinus floor augmentation procedure with lateral approach and β -Tricalcium Phosphate "R.T.R." Septodont with bone graft substitute material (day 0).

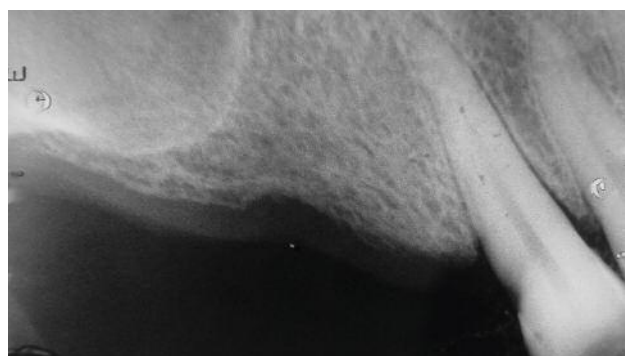

Fig. 4: Pre-op X-ray (day 0).

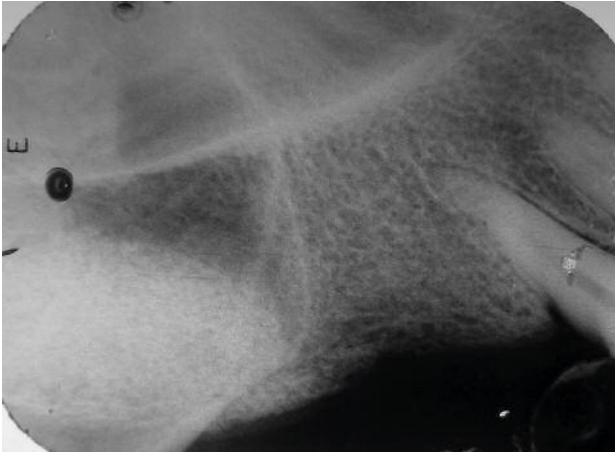

Fig. 5: X-ray immediately post-op showing the location of the β -Tricalcium Phosphate on the maxillary sinus floor -radiolucent area- (day 0).

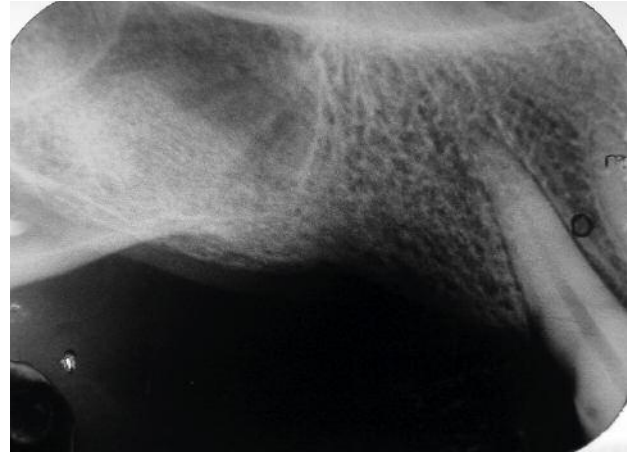


Fig. 6: X-ray six months after the maxillary sinus floor augmentation procedure with lateral approach and β -Tricalcium Phosphate "R.T.R." Septodont as bone graft substitute material. The decrease in the radiolucent area shown in Fig. 6 is obvious, indicating the replacement of the material with new bone.

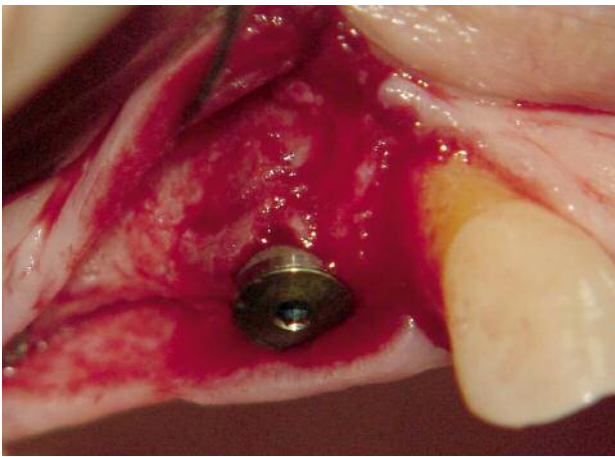


Fig. 7: During the surgical procedure (at 7 months) of implant placement, at the site of 14, the presence of the vestibular cortical plate of inadequate thickness is noted.

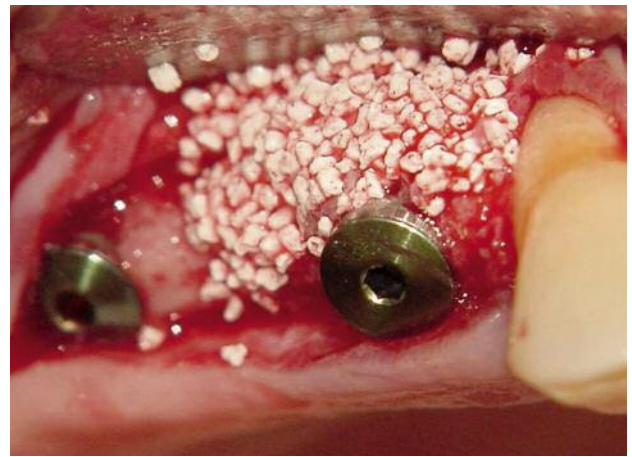


Fig. 8: β -Tricalcium Phosphate "R.T.R." Septodont as bone graft substitute material in the vestibular plate of 14. Distal implant in the first molar area placed in the area of the maxillary sinus floor augmented 7 months earlier.

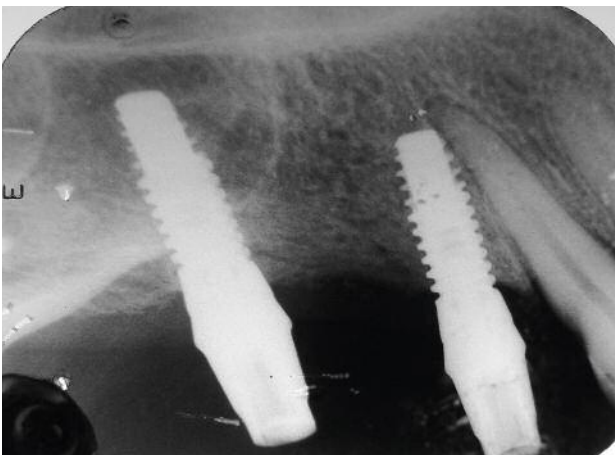


Fig. 9: X-ray immediately after placement of the prosthetic pillars on the implants. Stability of the implant in the area of 16 was clinically proven.

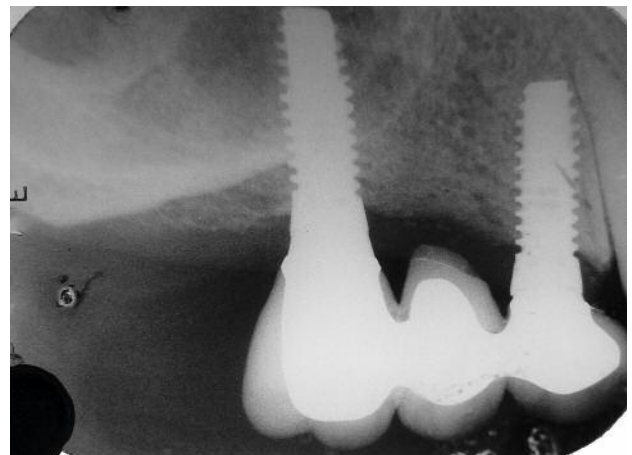


Fig. 10: Prosthetic restoration 10 months after the maxillary sinus floor augmentation procedure with lateral approach and β -Tricalcium Phosphate "R.T.R." Septodont and 3 months after placement of the implants.

Case Report no.2

Female patient, 55 years of age

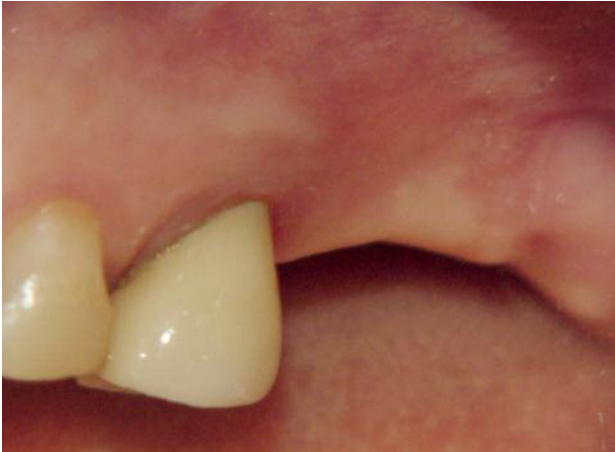

Fig. 1: Left atrophic posterior maxilla. Absence of molars lost approx. 10 years ago. Replaced with removable partial denture.

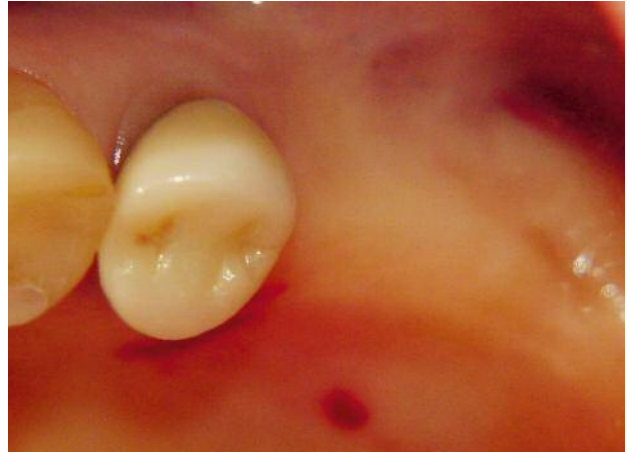


Fig. 2: Occlusal view of the area.

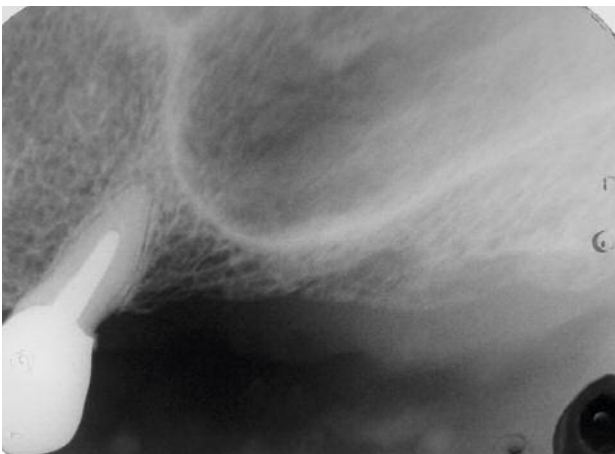

Fig. 3: Pre-op X-ray.

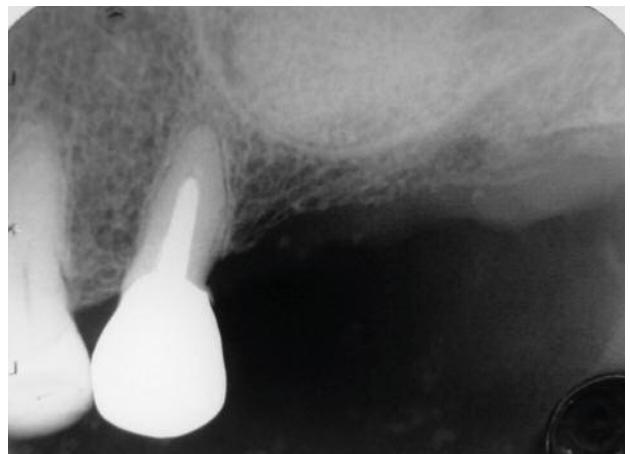


Fig. 4: X-ray immediately post-op showing the placement of the β -Tricalcium Phosphate on the maxillary sinus floor -radiolucent area- (day 0).

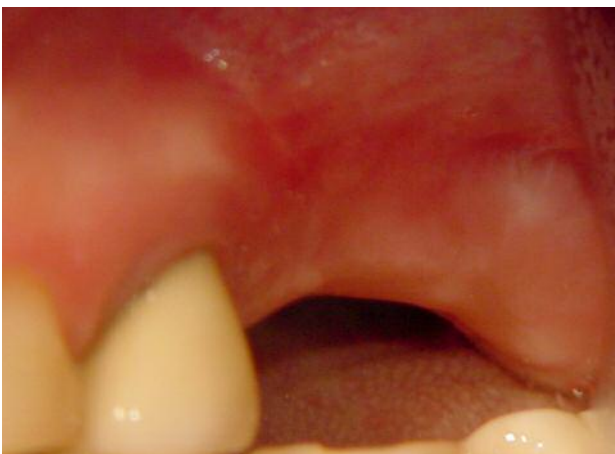

Fig. 5: Pre-op clinical image 6 months after β -Tricalcium Phosphate graft "R.T.R." Septodont.

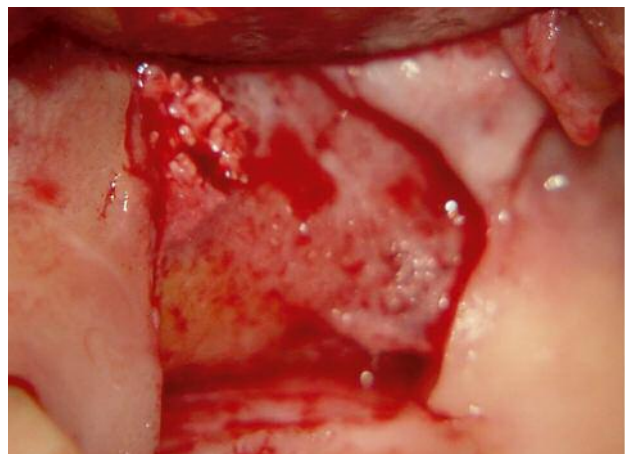

Fig. 6: In the window of the sinus lift procedure done 6 months earlier, granules of β -Tricalcium Phosphate "R.T.R." Septodont are observed, which indicates partial replacement with new bone.

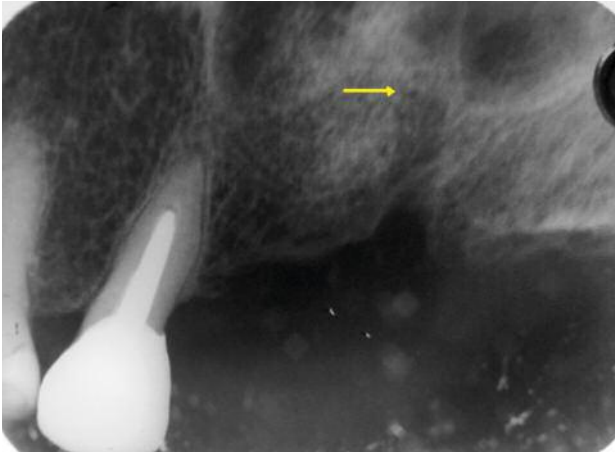


Fig. 7: X-ray image to confirm the cutting depth (2.5 mm \varnothing) of the implant receptor site at 10 mm (arrow). Partial replacement of the bone substitute material with receptor bone is obvious.

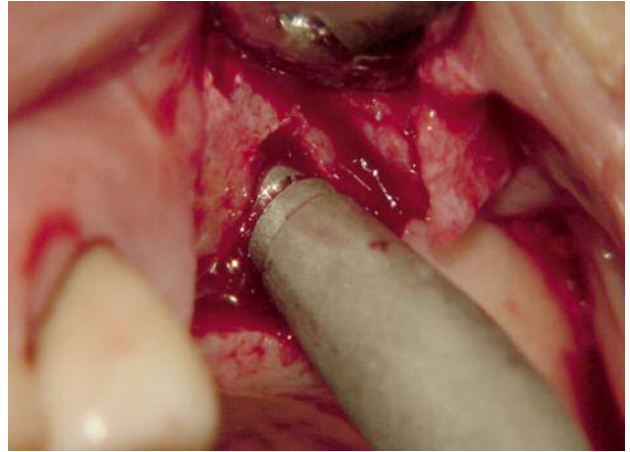


Fig. 8: With osteotomes (Summers technique, 1994) the maxillary sinus floor is lifted 2 mm to achieve insertion of a 12-mm long implant.

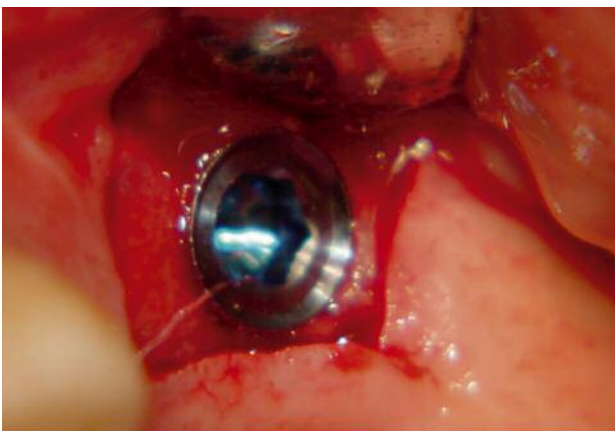


Fig. 9: Implant 12 mm long by 5 mm diameter placed at bone crest level.

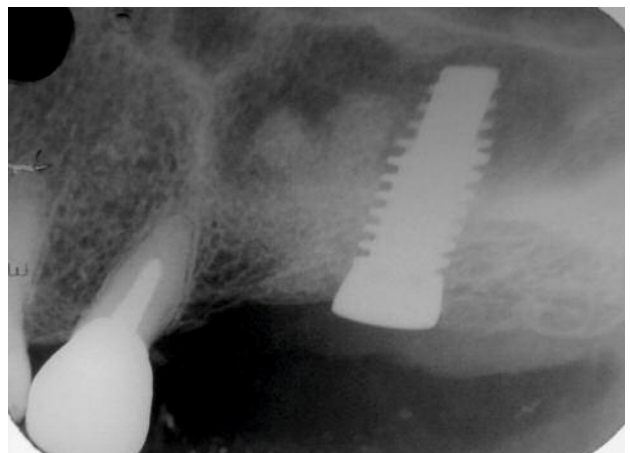


Fig. 10: X-ray image showing the placement of the implant.

Conclusions

Resorption of the alveolar process and pneumatization of the sinus in the edentulous posterior maxilla often represents a clinical challenge in restorative/prosthetic treatment with dental implants (1). Various surgical procedures and graft materials have been used to correct such changes (20-22), including β -Tricalcium Phosphate (23). Miyamoto et al. report "... particles of tricalcium phosphate attract osteoprogenitor cells that migrate into the interconnected micropores of the bone substitute material by six months" (25). The stability of the implants placed at the sites has been evaluated (24). A recent systematic review concludes: "There is a high level of evidence that survival rates of dental implants placed into augmented areas are

comparable with survival rates of implants placed in pristine bone. For maxillary sinus floor elevation, all investigated bone substitute materials performed equally well compared with bone, with high dental implant survival rates and adequate histomorphometric data" (3). The two cases presented show satisfactory results in the use of the bone graft material, β -Tricalcium phosphate "R.T.R." Septodont based on the evidence reported. This, along with the availability of the material and its safety in use, make it a therapeutic choice with multiple benefits.



Author: Dr Mario Ernesto García-Briseño

DDS at Universidad Autónoma de Guadalajara, México, 1976.

Certificate program in Periodontology at Universidad Nacional Autónoma de México 1985-87.

Director and Professor of the certificate program in Periodontology since 1992 to date at Universidad Autónoma de Guadalajara School of Dentistry.

Professor of Periodontology at certificate programs in Endodontics,

Orthodontics, and Oral Rehabilitation since 1992 at Universidad Autónoma de Guadalajara School of Dentistry.

Founder and President of the Mexican Association of Periodontology 1996-98.

Founding member and Secretary of the Mexican Board of Periodontology 1996/2001.

Academy affairs coordinator College of Dental Surgeons of Jalisco 2000/2004.

Founder and academic coordinator of the College of Periodontics GDL.

National and international lecturer.

Private practice in Periodontics and Implant Dentistry.

References

- 01 Schulze-Späte, U., Dietrich, T., Kayal, R. A., Hasturk, H., Dobeck, J., Skobe, Z. & Dibart, S. (2012) Analysis of bone formation after sinus augmentation using β -tricalcium phosphate. *Compendium of Continuing Education in Dentistry* 33, 364–368.
- 02 Al-Nawas B, Schiegnitz E: Augmentation procedures using bone substitute materials or autogenous bone – a systematic review and meta-analysis. *Eur J Oral Implantol* 2014;7(Suppl2):S219–S234.
- 03 Klein MO, Al-Nawas B. For which clinical indications in dental implantology is the use of bone substitute materials scientifically substantiated? *Eur J Oral Implantol* 2011;4:11–29.
- 04 LeGeros RZ. Properties of osteoconductive biomaterials: calcium phosphates. *Clin Orthop Relat Res* 2002;(395):81–98.
- 05 Daculsi G, LeGeros RZ, Heughebaert M, Barbieux I. Formation of carbonate apatite crystals after implantation of calcium phosphate ceramics. *Calcif Tissue Int* 1990; 46: 20-7
- 06 Cutright DE, Bhaskar SM, Brady JM, Getter L, Posey WR. Reaction of bone to tricalcium phosphate ceramic pellets. *Oral Surg Oral Med Oral Pathol* 1972; 33 : 850-6.
- 07 Ghosh SK, Nandi SK, Kundu B, Datta S, De DK, Roy SK, et al. In vivo response of porous hydroxyapatite and β -tricalcium phosphate prepared by aqueous solution combustion method and comparison with bioglass scaffolds. *J Biomed Mater Res B Appl Biomater* 2008; 86 : 217-27.
- 08 Hing KA, Wilson LF, Buckland T. Comparative performance of three ceramic bone graft substitutes. *Spine J* 2007; 7 :475-90.
- 09 Cameron HU, Macnab I, Pilliar RM. Evaluation of biodegradable ceramic. *J Biomed Mater Res* 1977; 11 : 179-86.
- 10 Zhang M, Wang K, Shi Z, Yang H, Dang X, Wang W. Osteogenesis of the construct combined BMSCs with β -TCP in rat. *J Plast Reconstr Aesthet Surg* 2008; 10:1016
- 11 Hak DJ. The use of osteoconductive bone graft substitutes in orthopaedic trauma. *J Am Acad Orthop Surg* 2007; 15 : 525-36.
- 12 Labanca M., Leonida A., Rodella FL: Natural synthetic biomaterial in Dentistry: Science and ethics as criteria for their use. *Implantologia* 2008; 1:9-23
- 13 Smiler DG, Johnson PW, Lozada JL, et al. Sinus lift grafts and endosseous implants. Treatment of the atrophic posterior maxilla. *Dent Clin North Am* 1992;36:151-186.
- 14 Metsger D.S. et al. (1982). Tricalcium phosphate ceramic--a resorbable bone implant: review and current status. *J Am Dent Assoc.*105: 1035-1038.
- 15 Boyne PJ, James RA. Grafting of the maxillary sinus floor with autogenous marrow and bone. *J Oral Surg.* 1980;38(8):513-616.
- 16 Tatum H Jr. Maxillary and sinus implant reconstructions. *Dent Clin North Am.* 1986;30(2): 207-229.
- 17 Summers RB. A new concept in maxillary implant surgery: the osteotome technique. *Compend Contin Educ Dent.* 1994;15(2):152-162.

References

- 18 Davarpanah M, Martinez H, Tecucianu JF, et al. The modified osteotome technique. *Int J Periodontics Restorative Dent*. 2001;21(6):599-607
- 19 Velich N, Nemeth Z, Toth C, Szabo G. Long-term results with different bone substitutes used for sinus floor elevation. *J Craniofac Surg* 2004;15:38–
- 20 Browaeys H, Bouvry P, De Bruyn H. A literature review on biomaterials in sinus augmentation procedures. *Clin Implant Dent Relat Res* 2007;9:166–177
- 21 Nkenke, E., Schlegel, A., Schultze-Mosgau, S., Neukam, F. W. & Wiltfang, J. (2002) The endoscopically controlled osteotome sinus floor elevation: a preliminary prospective study. *International Journal of Oral and Maxillofacial Implants* 17, 557–566.
- 22 Uckan, S., Deniz, K., Dayangac, E., Araz, K. & Ozdemir, B. H. (2010) Early implant survival in posterior maxilla with or without beta-tricalcium phosphate sinus floor graft. *Journal of Oral and Maxillofacial Surgery* 68, 1642–1645.
- 23 Zerbo, I. R., Zijderveld, S. A., de Boer, A., Bronckers, A. L., de Lange, G., ten Bruggenkate, C. M. & Burger, E. H. (2004) Histomorphometry of human sinus floor augmentation using a porous beta-tricalcium phosphate: a prospective study. *Clinical Oral Implants Research* 15, 724–732.
- 24 Rombelli L, Franceschetti G, Stacchi C, Minenna L, Riccardi O, Di Raimondo R, Rizzi A, Farina R. Minimally invasive transcrestal sinus floor elevation with deproteinized bovine bone or β -tricalcium phosphate: a multicenter, double-blind, randomized, controlled clinical trial. *J Clin Periodontol* 2014; 41: 311–319
- 25 Miyamoto S, Shinmyozu K, Miyamoto I, Takeshita K, Terada T, Takahashi T. Histomorphometric and immunohistochemical analysis of human maxillary sinus floor augmentation using porous β -tricalcium phosphate for dental implant treatment. *Clin. Oral Impl. Res.* 24 (Suppl. A100), 2013, 134–138.



The Dental Pharmaceutical Company

INNOVATIVE, SAFE AND EFFECTIVE SOLUTIONS FOR DENTISTRY WORLDWIDE